

Surgical Case

Hospital Infantil de México “Federico Gómez”

Mexico City

Dra. Brenda Domínguez Zúñiga

Dr. Emilio Fernández Portilla

Dr. Roberto Dávila Pérez

Dr. Alfredo Domínguez Muñoz





MEDICAL HISTORY

- Female ♀
- 9 years old
- No history of illness in her family



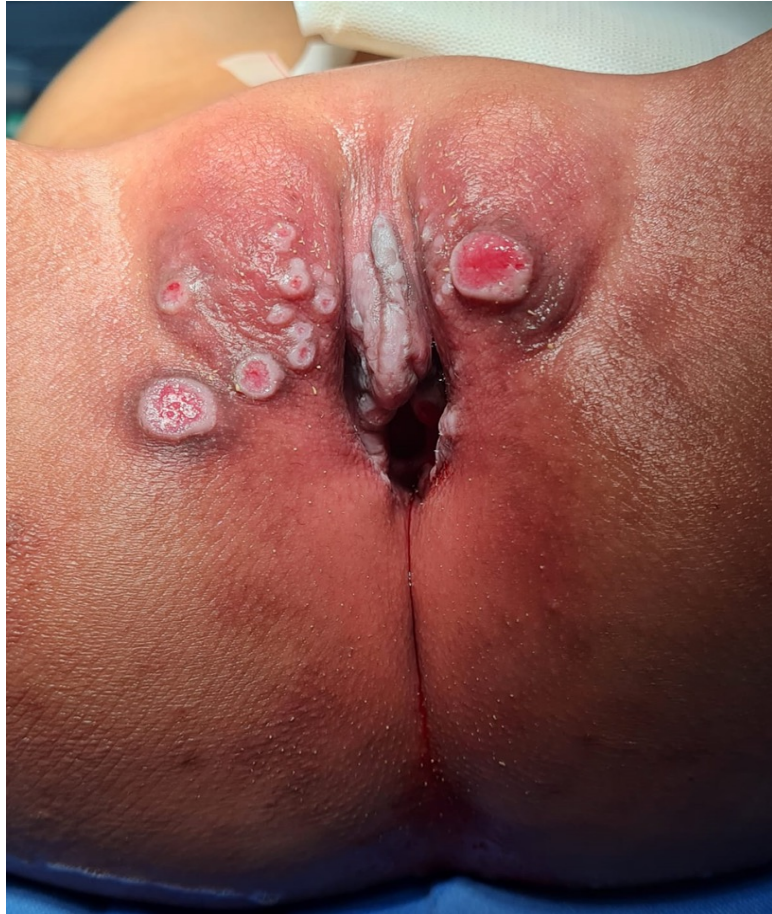MEDICAL HISTORY

- Late diagnosis of anorectal malformation (8 yo)
 - September 2022 First time at colorrectal center

Physical examination:

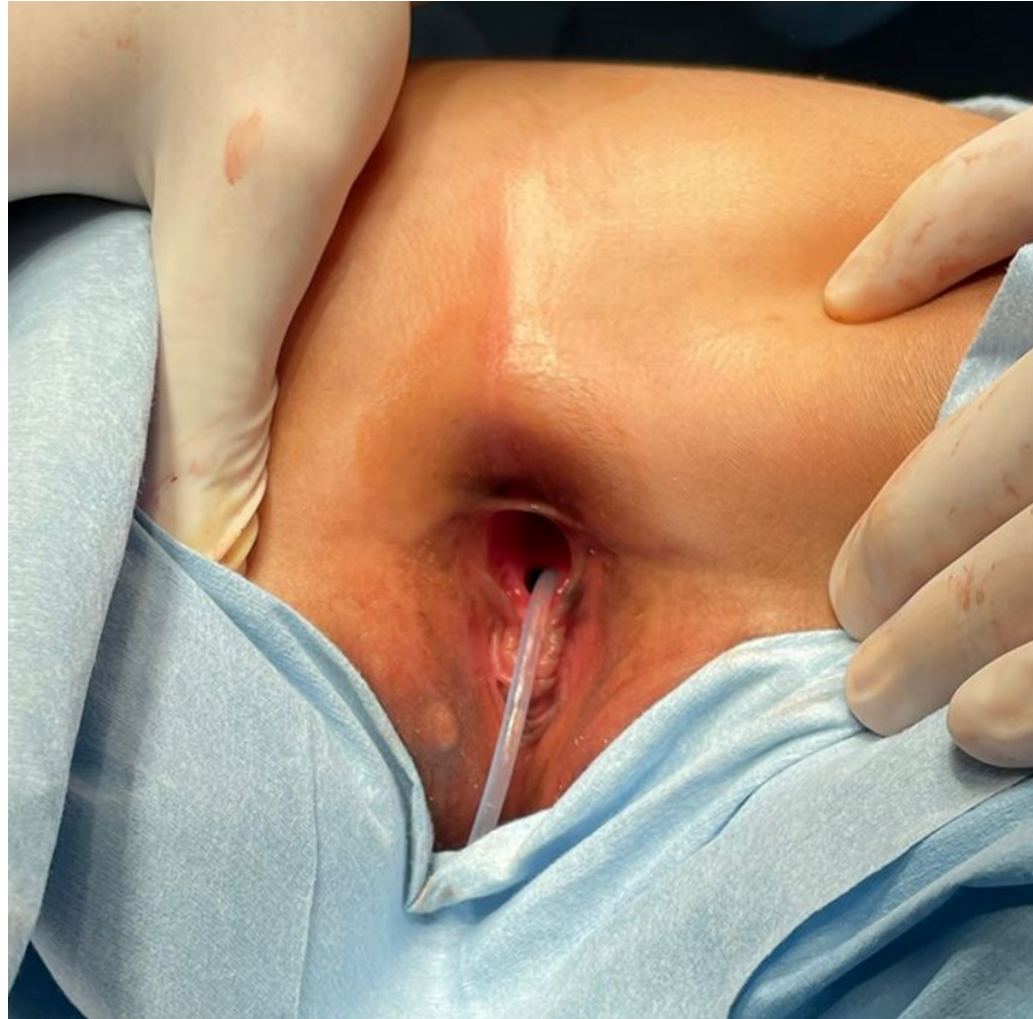- Lumbar scoliosis
- Anorectal malformation: vestibular fistula
- Vaginal agenesis

Physical exam



- Urinary incontinence
 - Incontinence-associated dermatitis
- Vaginal agenesis
- Anorectal malformation:
vestibular fistula

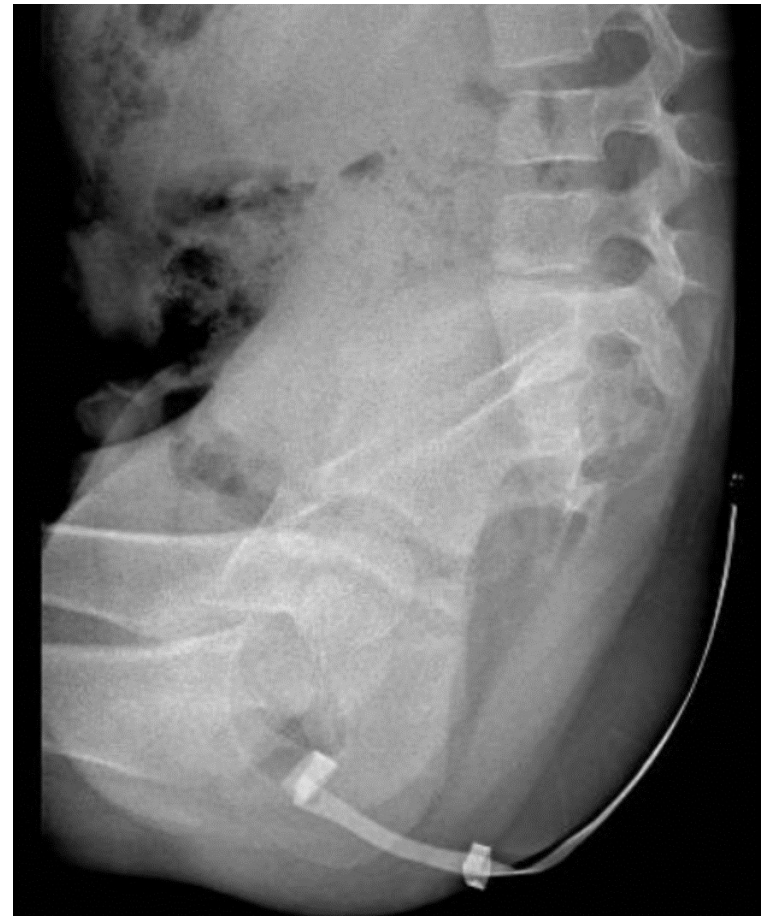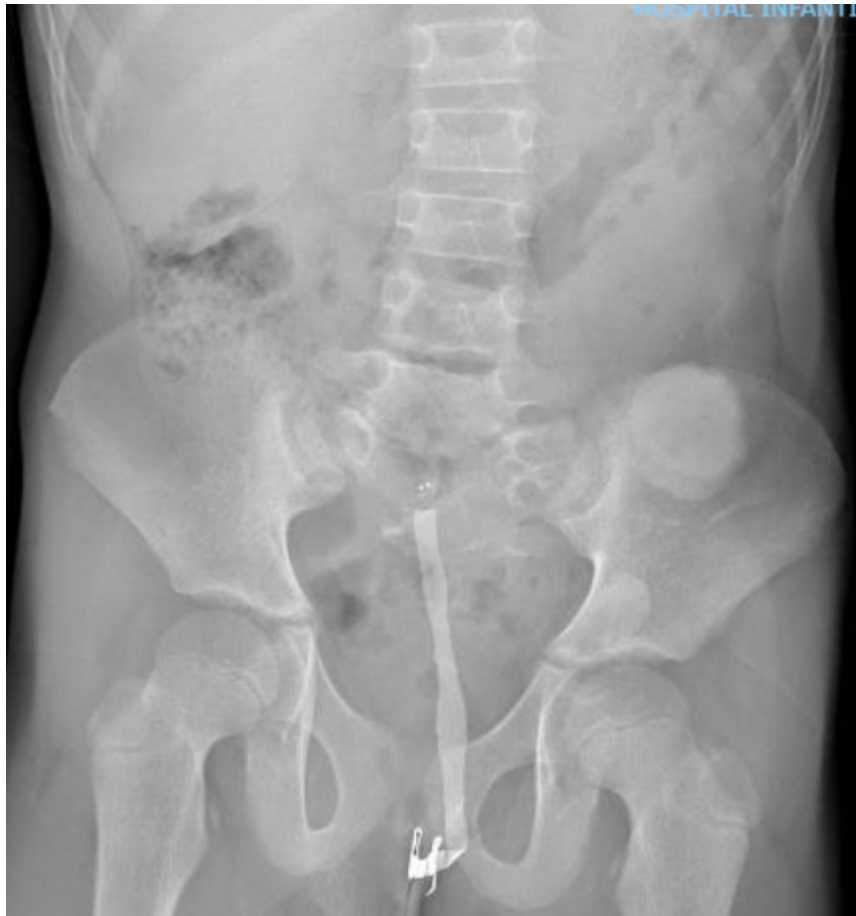Physical exam

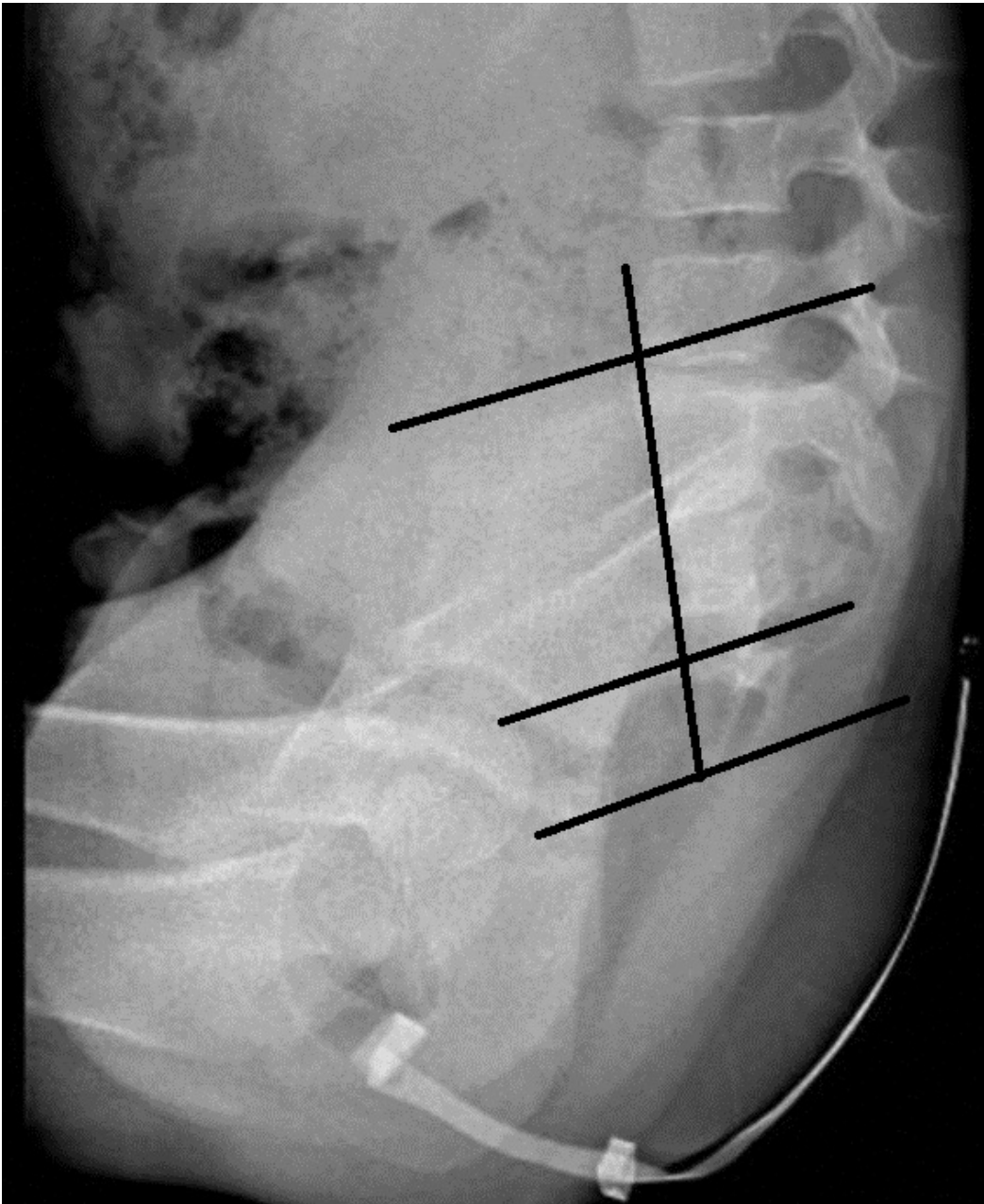


SURGICAL TREATMENT

- Colostomy
 - Meckel's diverticulum
 - Absent uterus

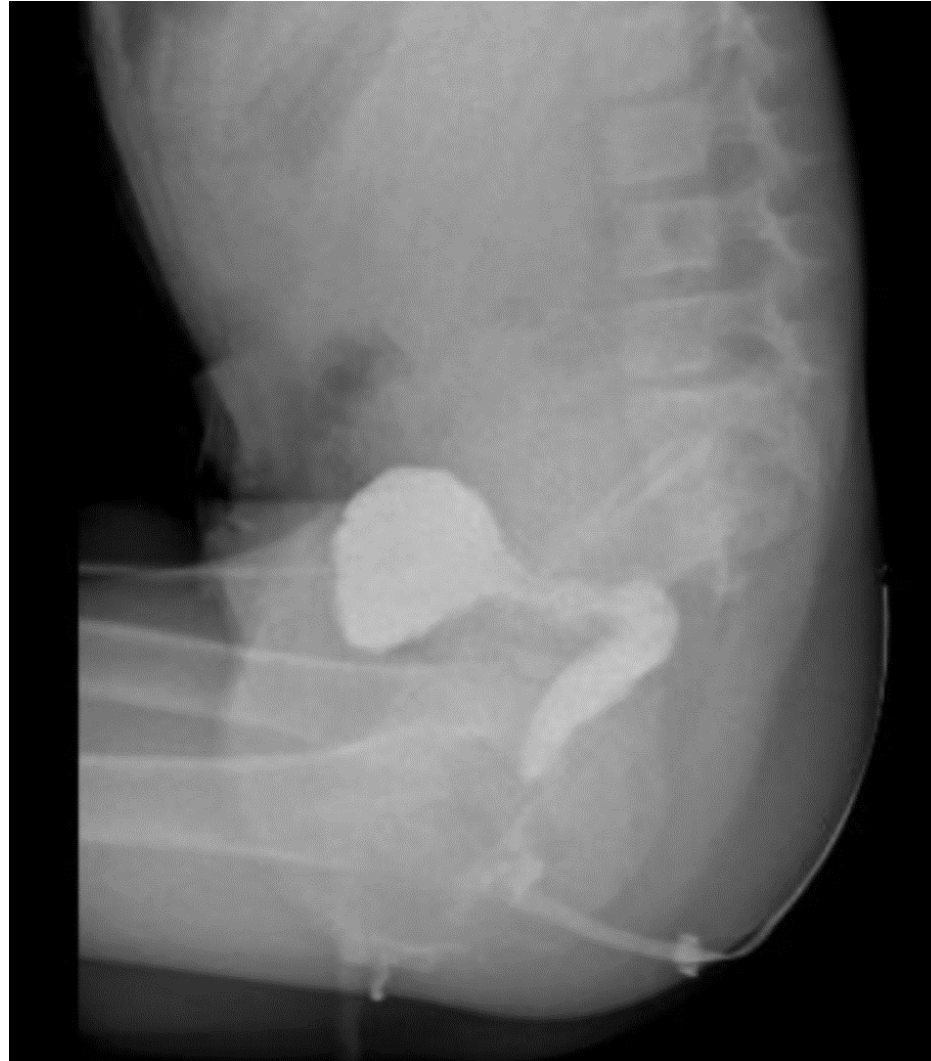X-RAY FILMS: abnormal sacrum

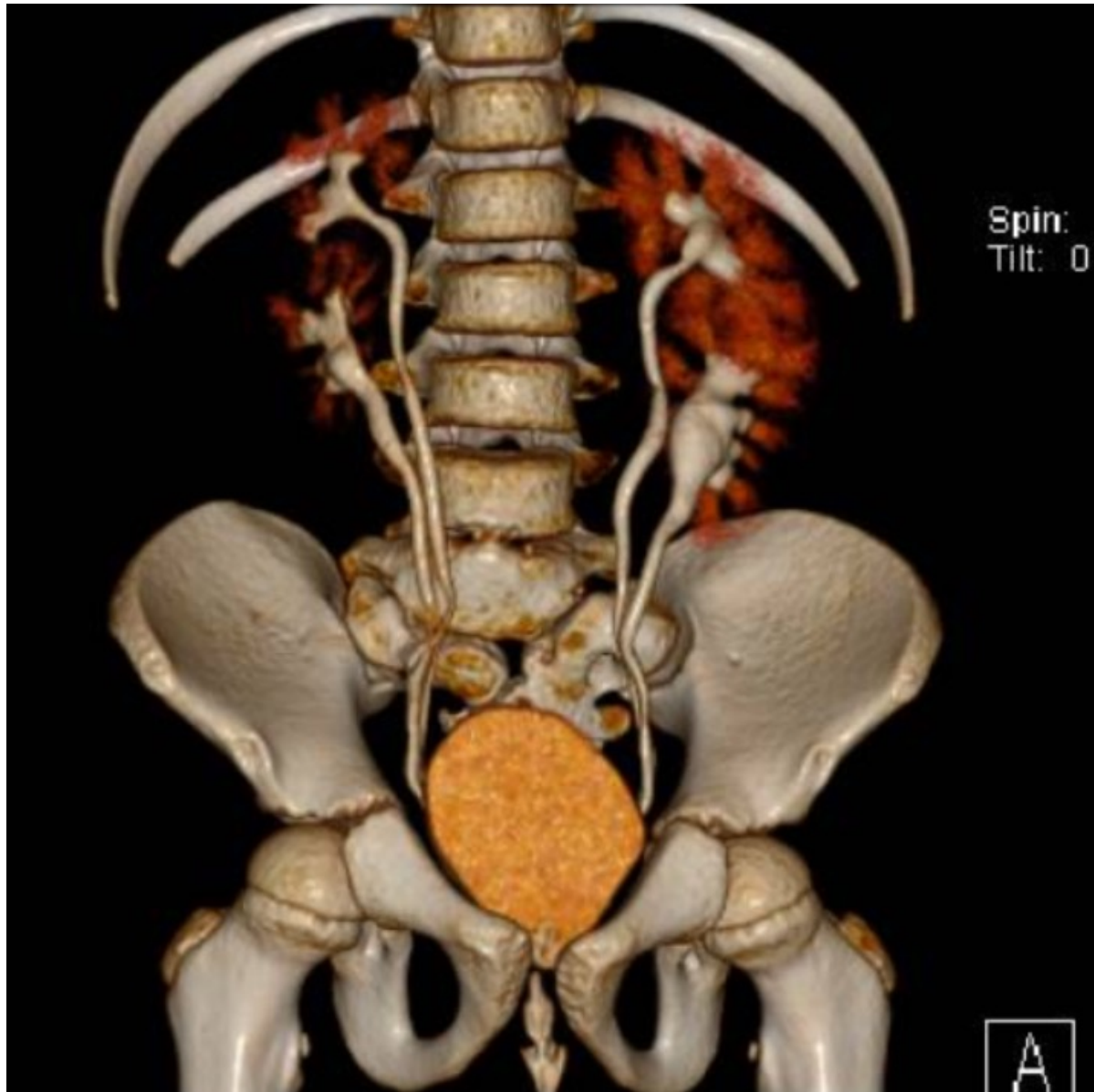




Sacrum ratio: 0.3

Distal colostogram





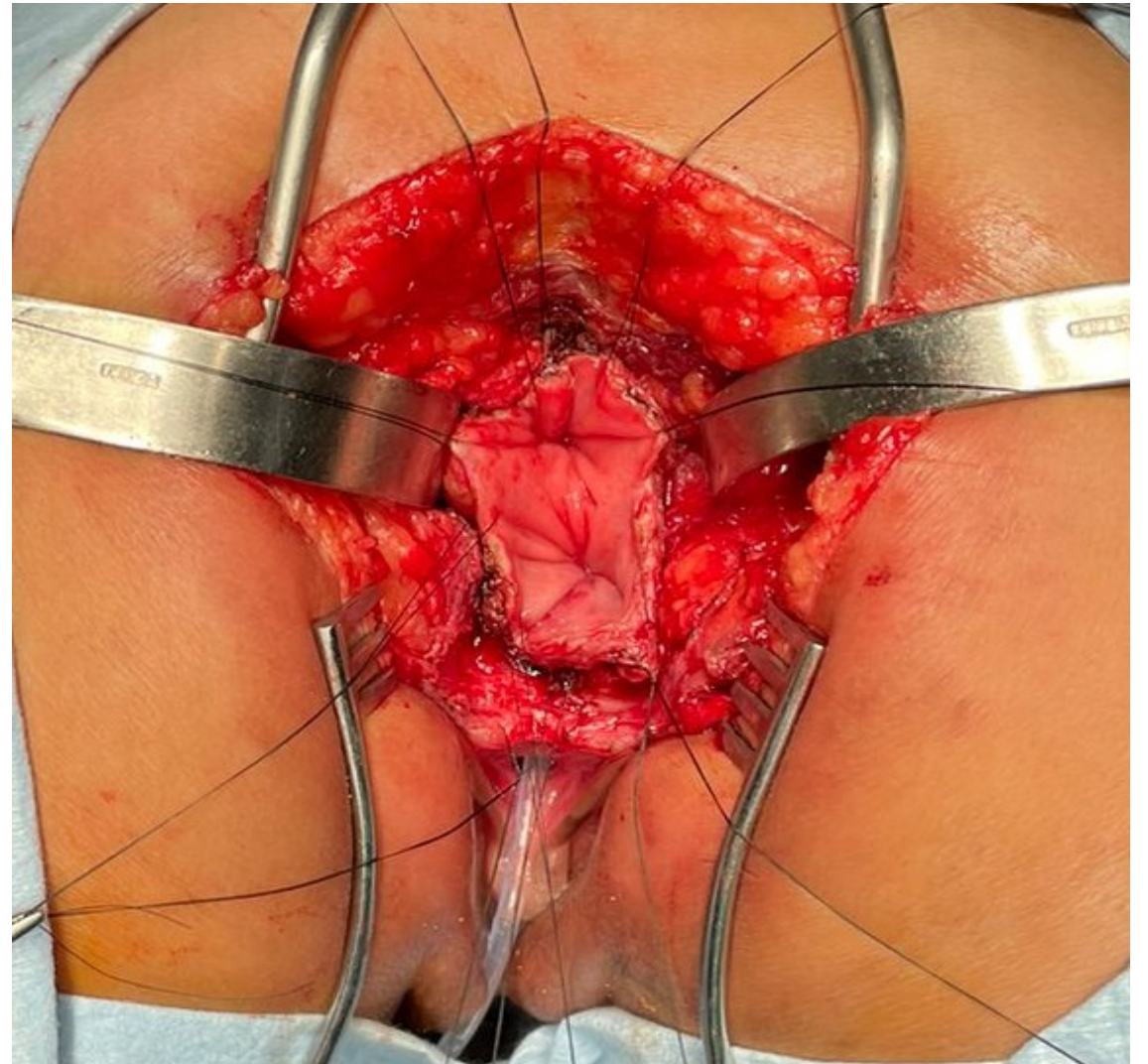
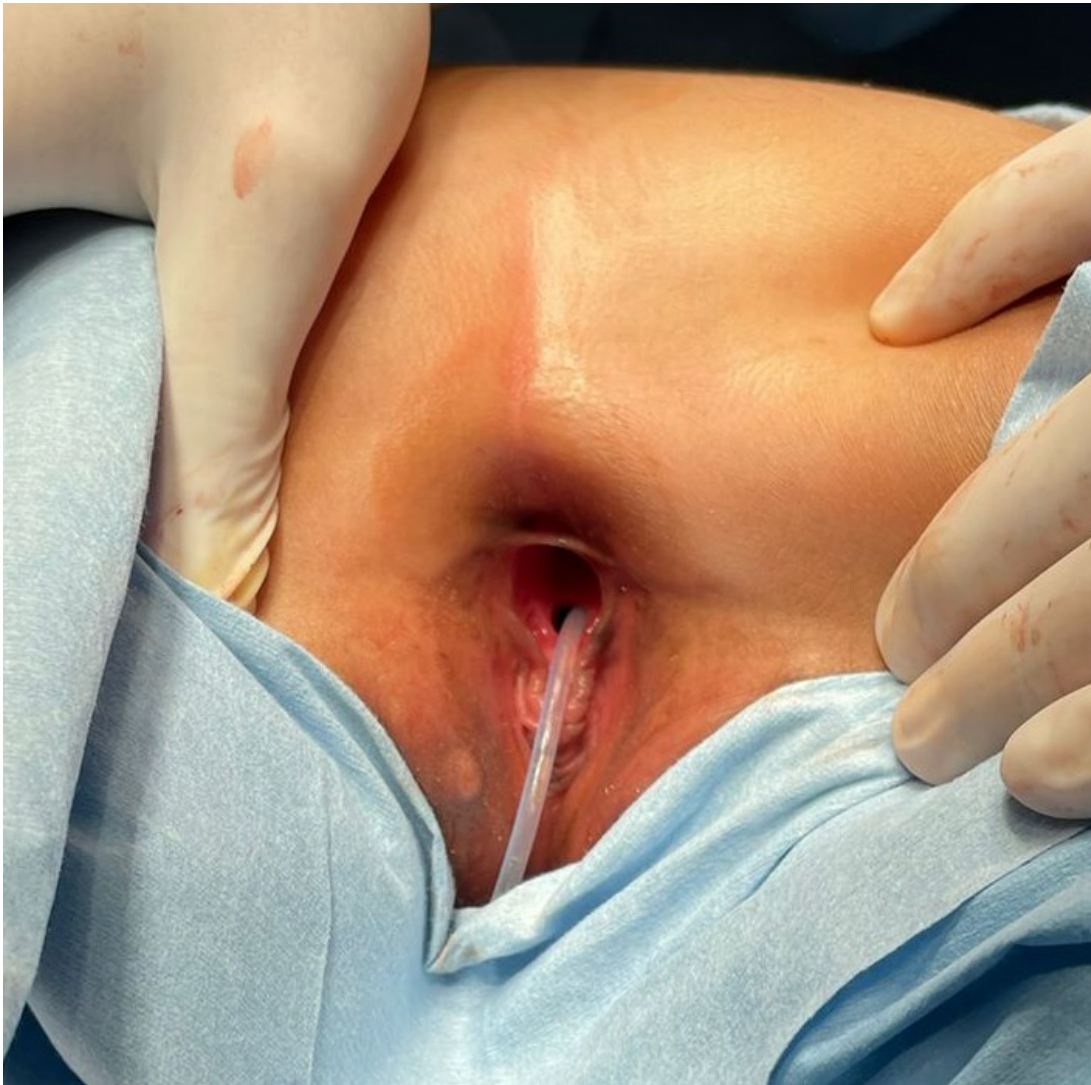Double excretory system (bilateral)

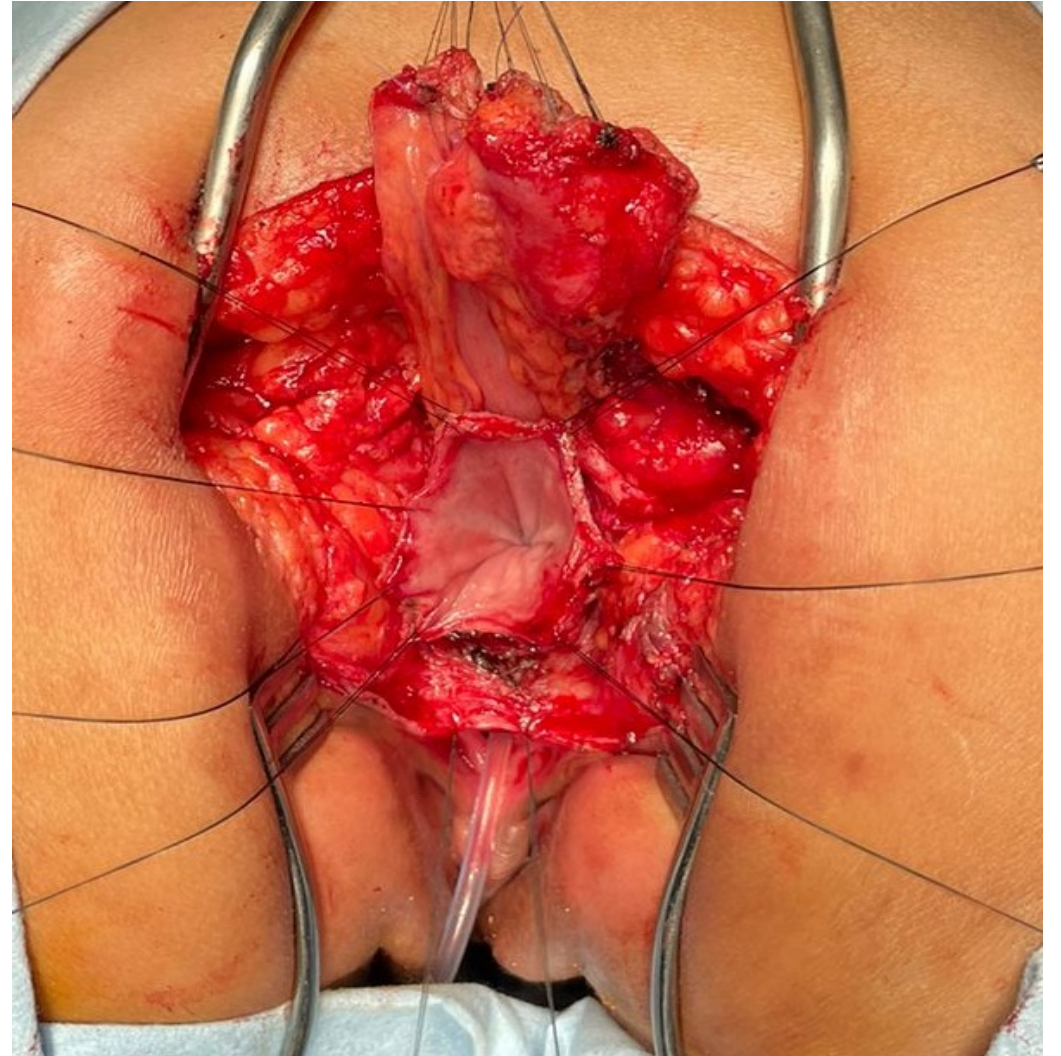
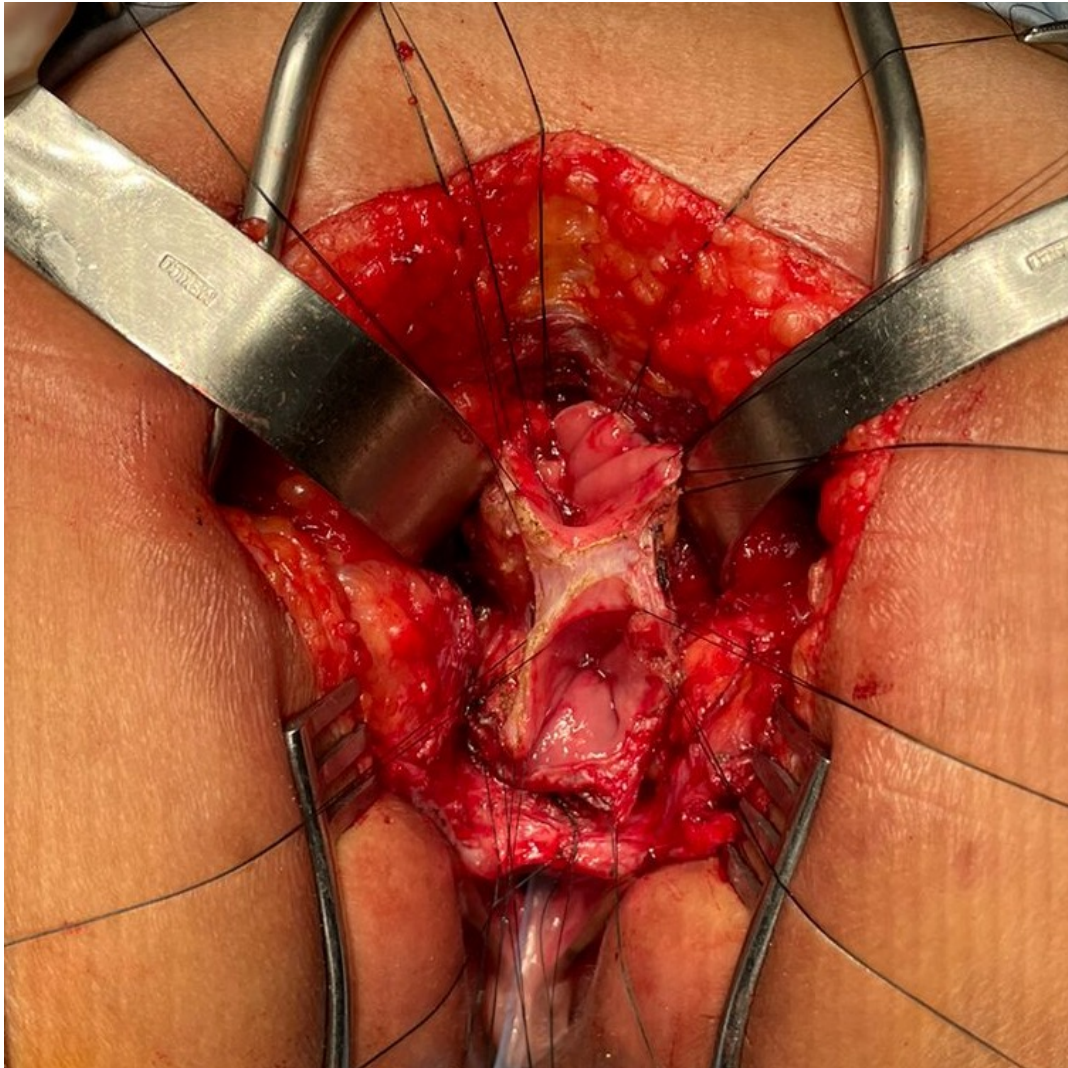
QUESTION 1

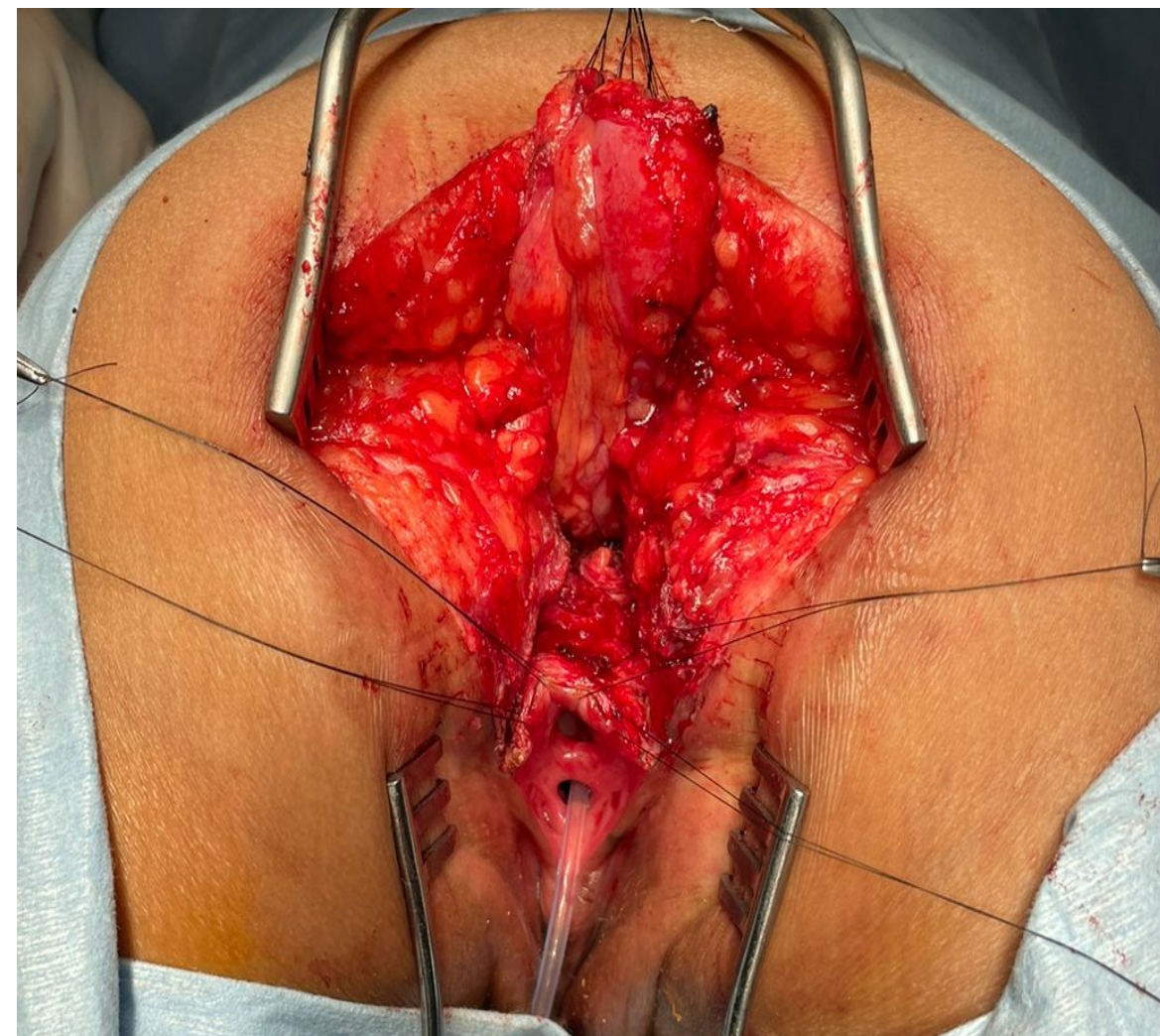
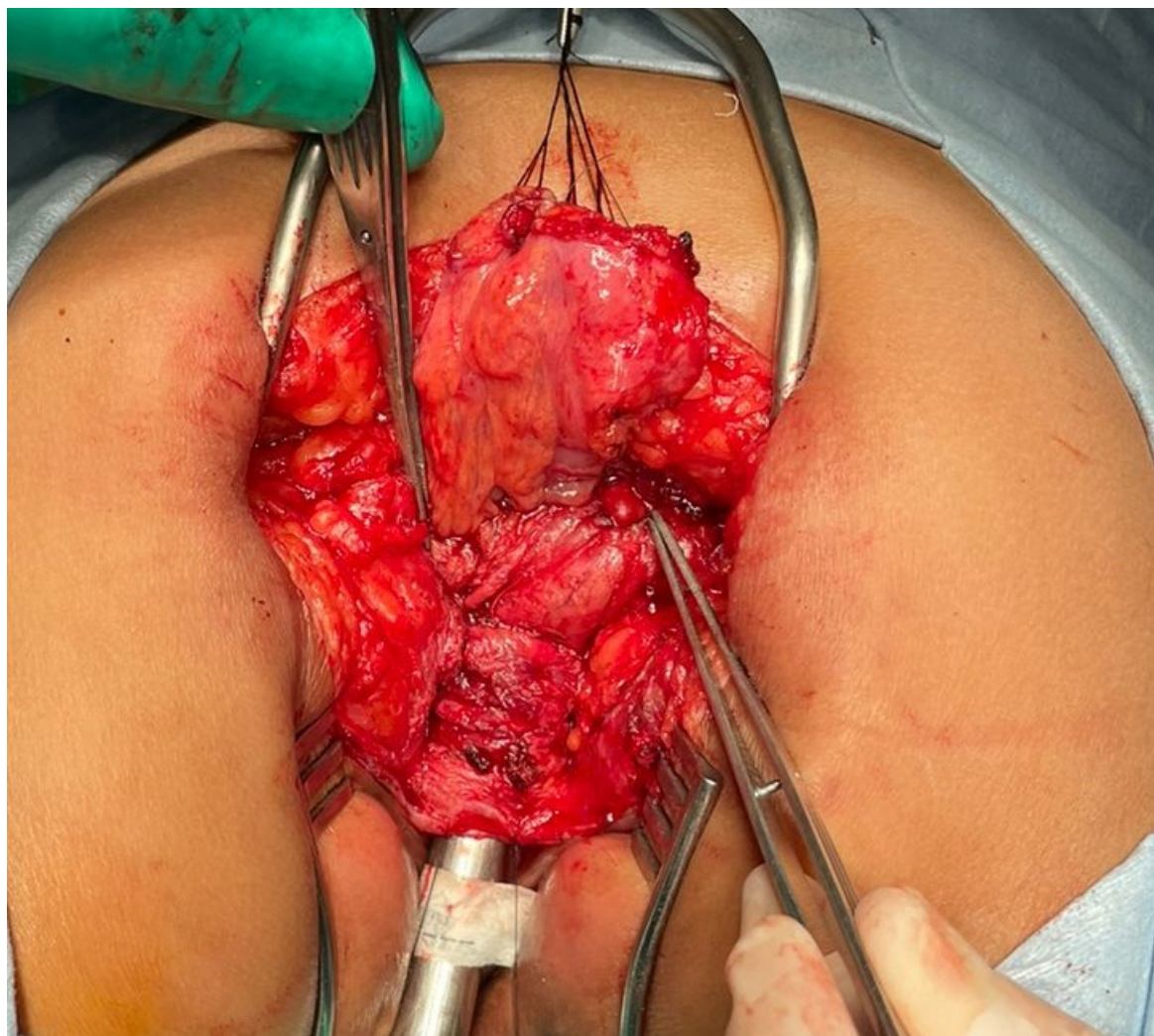
- What are the chances for bowel control?
 - A) Excellent
 - B) Poor
 - C) I am not sure

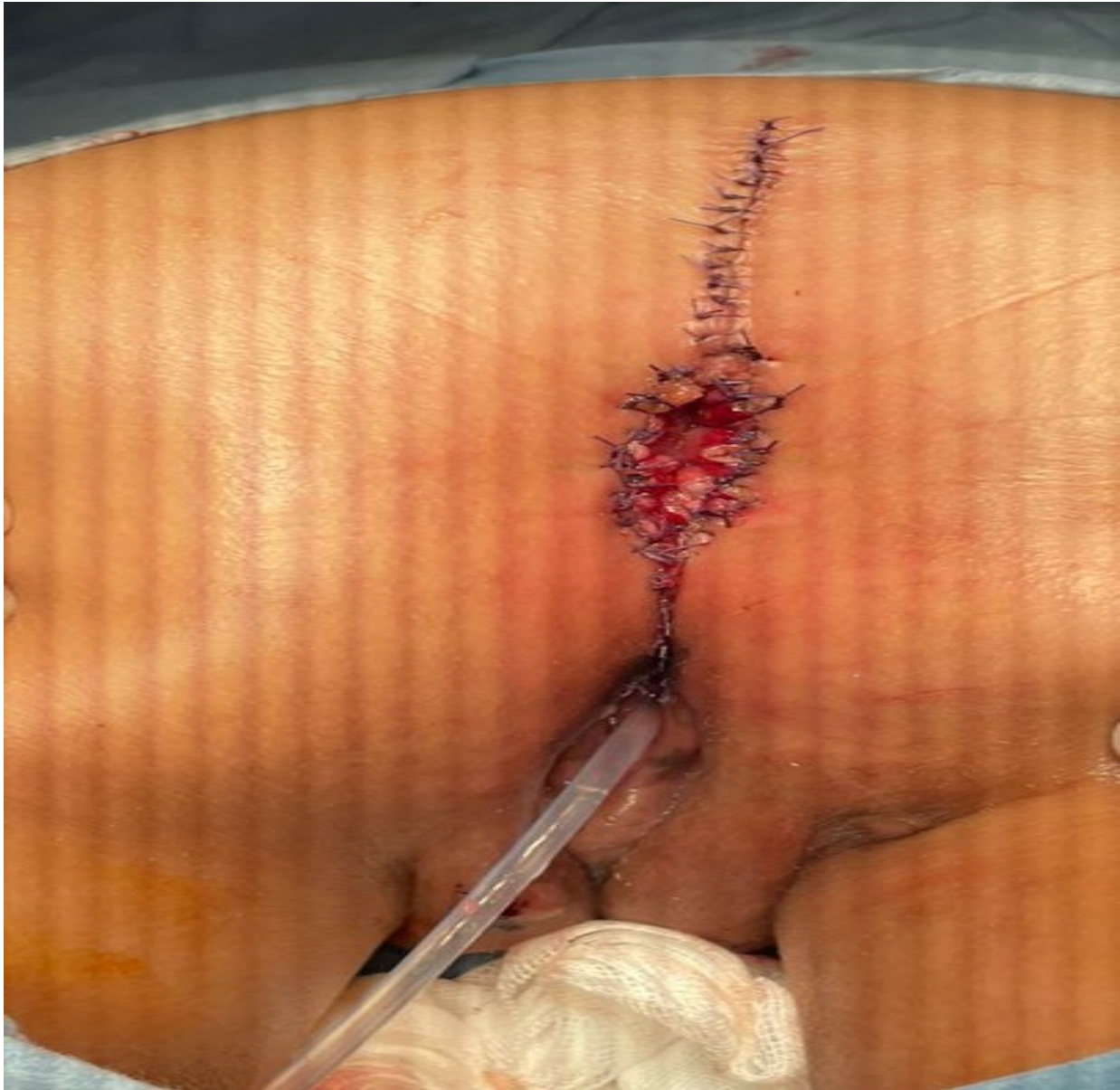QUESTION 2

- What is the goal for the vaginal replacement?
 - A) Sexual function
 - B) Capacity to procreate
 - C) I don't know

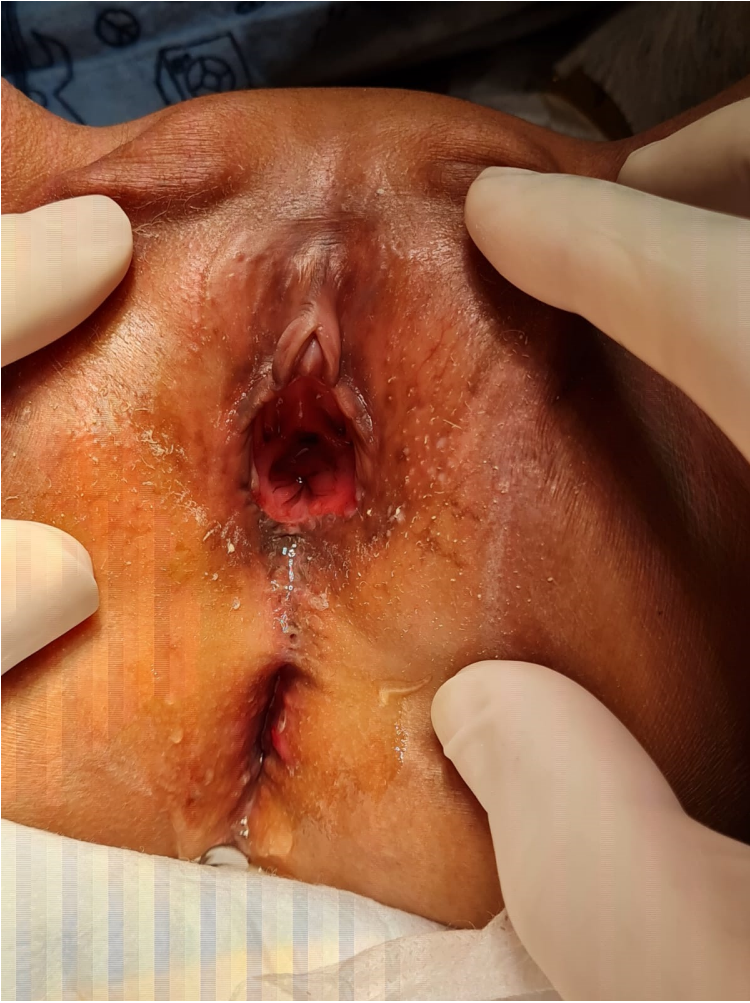







TWO MONTHS LATER



THANK YOU

MR

