

Case #4

Andrea Bischoff

August 27th, 2020



Children's Hospital Colorado

INTERNATIONAL CENTER FOR
**COLORECTAL AND
UROGENITAL CARE**



9 yo male patient, born with Trisomy 21,
hyperthyroidism, and Hirschsprung
disease

Underwent Soave pull-through at 9
months of age.



Initially seen by GI due to “constipation and overflow pseudo-incontinence.”

Plan: Botox injection



What is your opinion about the current plan?

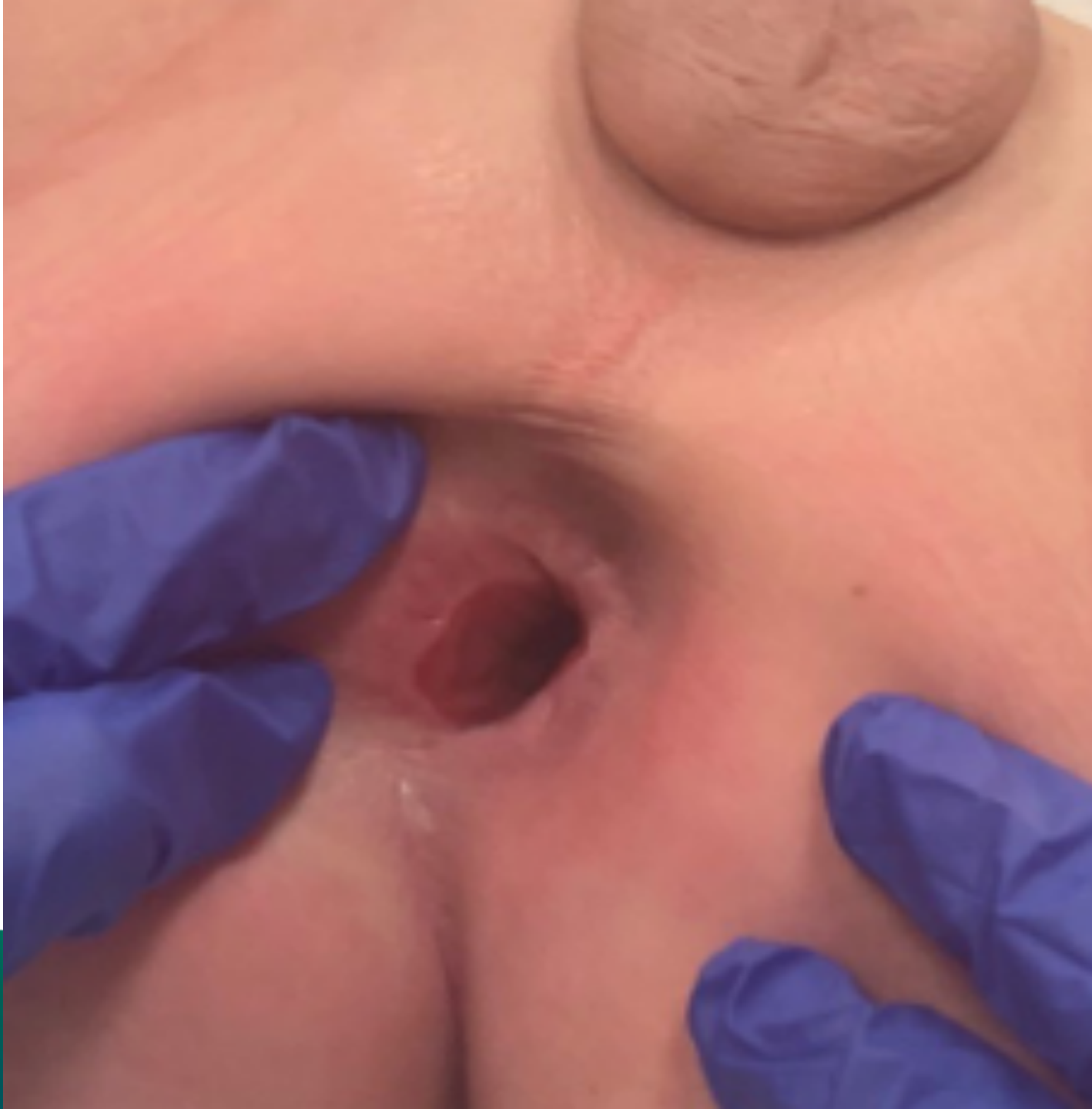1. Agree
2. Disagree
3. Need more information

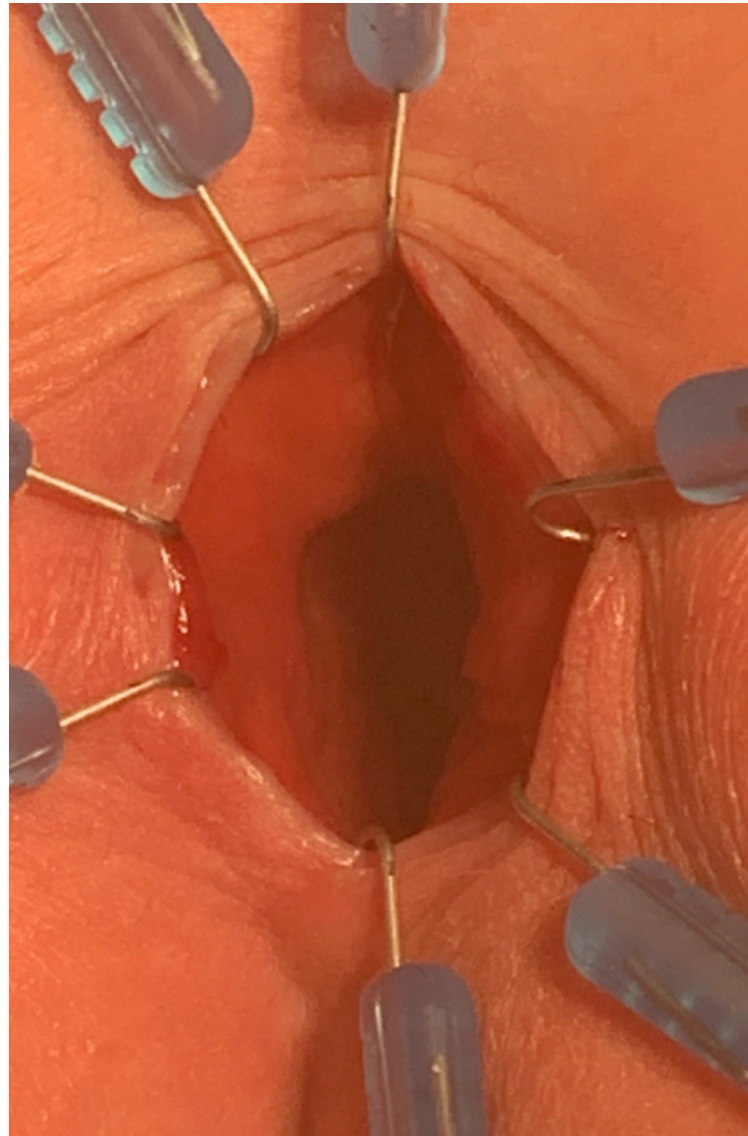
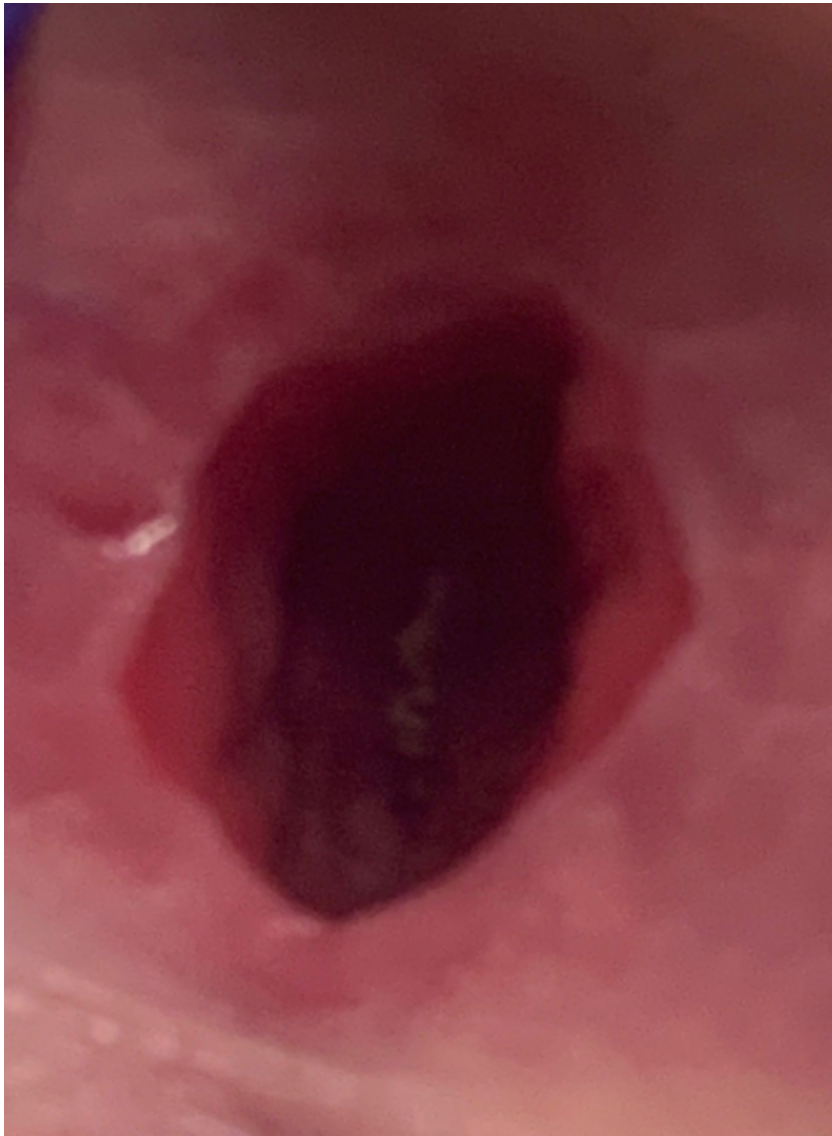

Patients operated for Hirschsprung disease coming to us with “bowel problems”



Examination under anesthesia







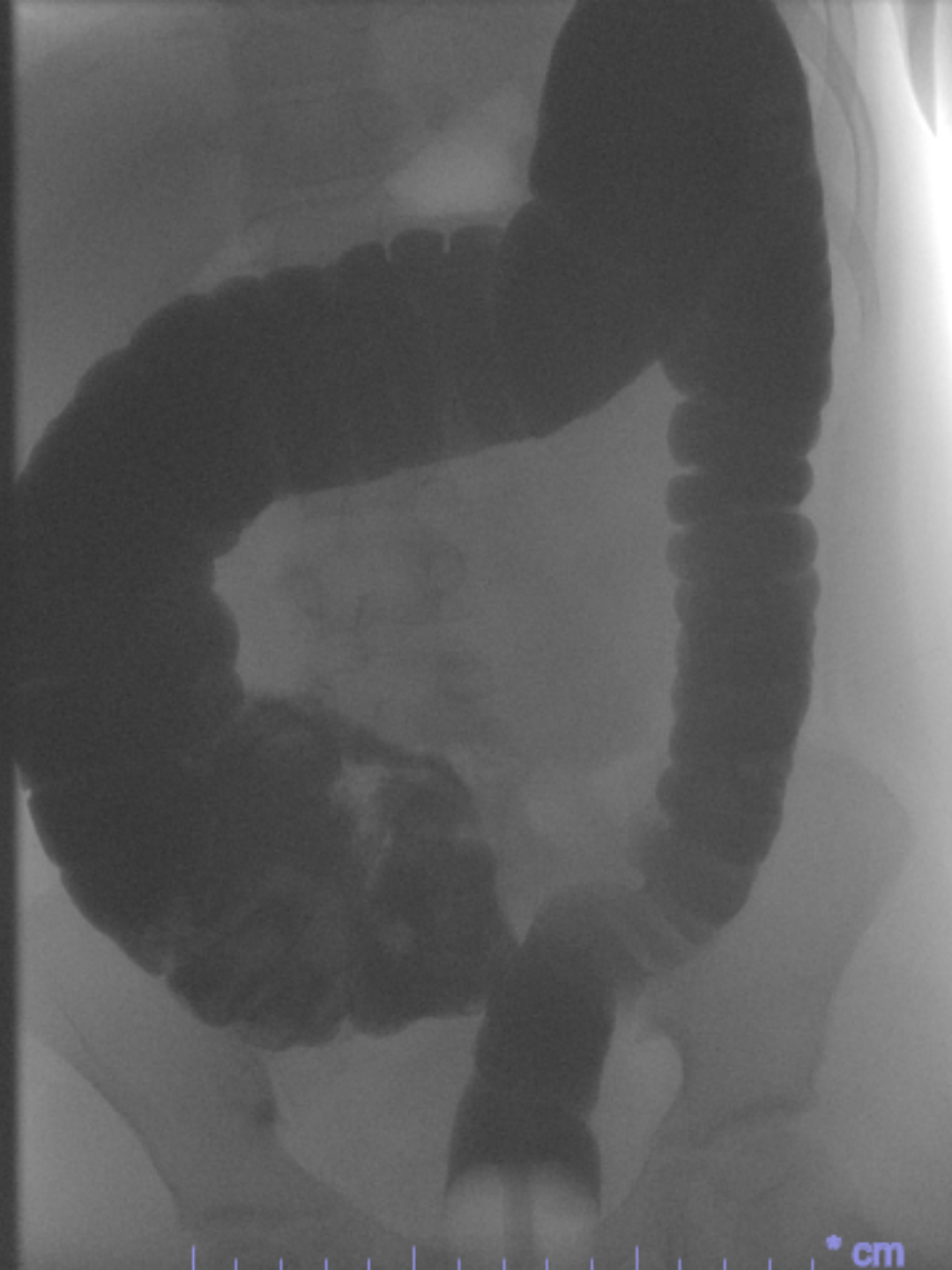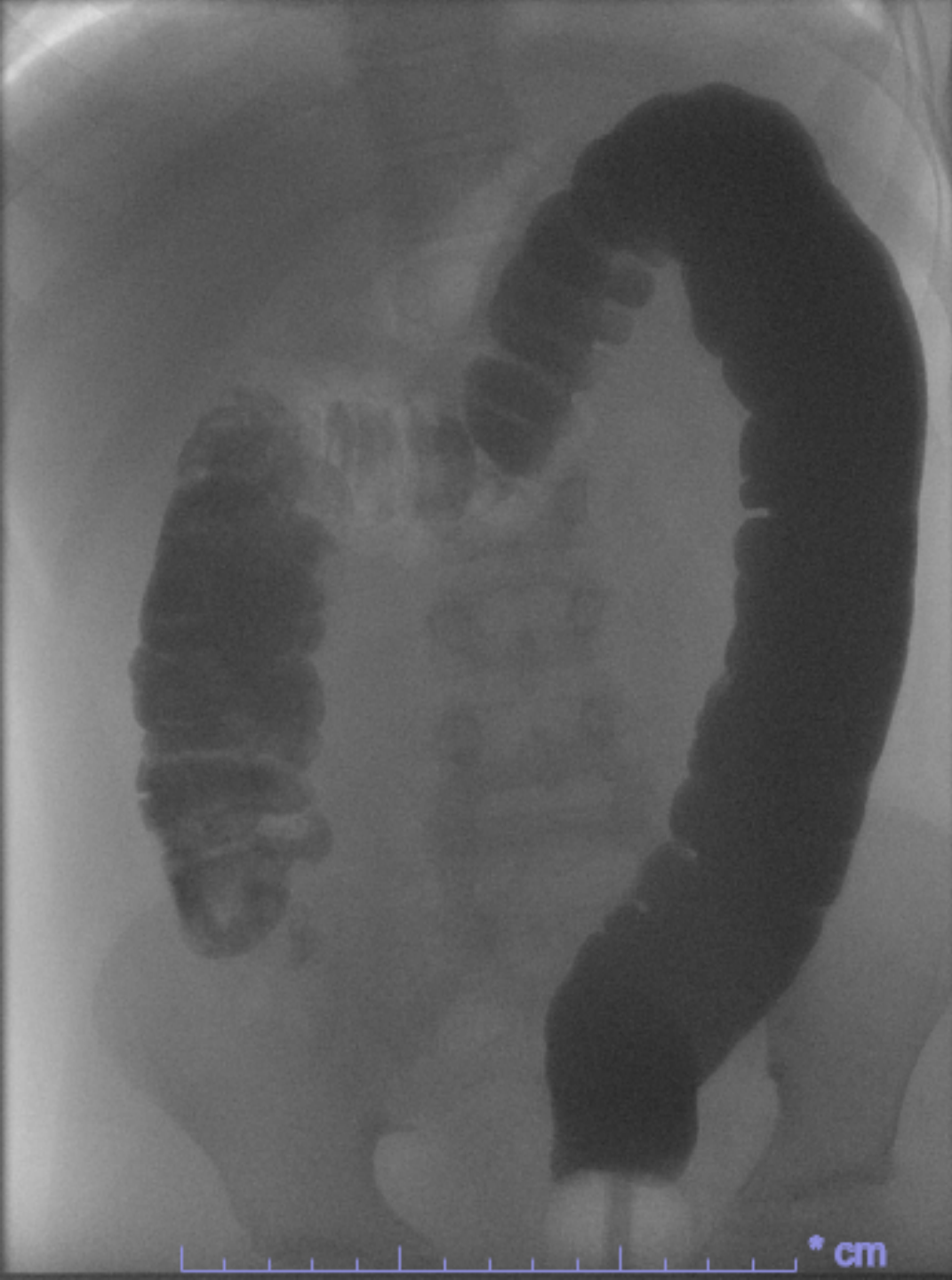With this finding is botox still a good plan?

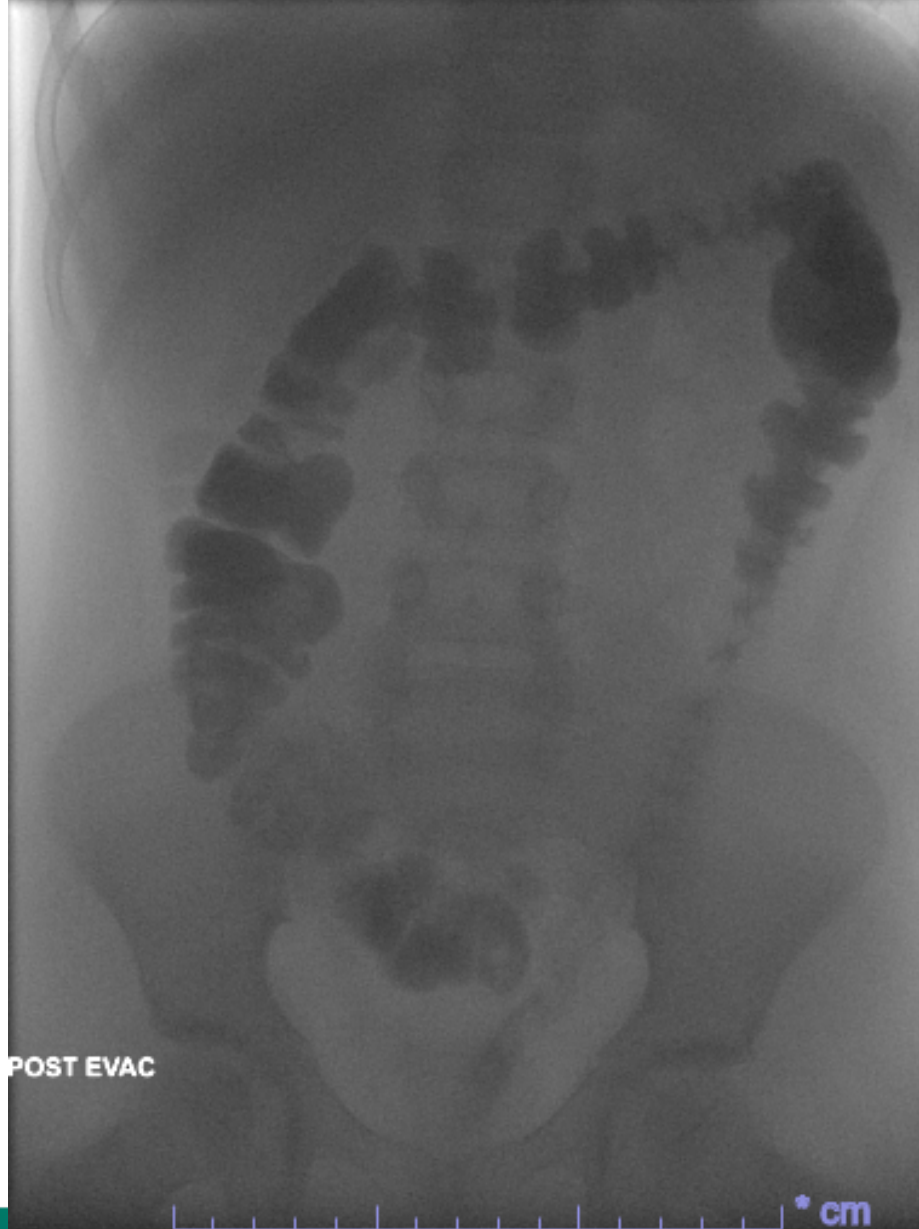1. Yes
2. No
3. I don't know

What would you recommend?



1. Permanent colostomy
2. Redo pull-through
3. Contrast enema and bowel management with laxatives
4. Contrast enema and bowel management with enemas





INTERNATIONAL CENTER FOR
**COLORECTAL AND
UROGENITAL CARE**



Patient started our bowel management program with enemas and was clean with 250 ml of normal saline + 10 ml of glycerin.

After 2 months, he underwent a Malone procedure and he continues to be clean for stool in the underwear.