

Case #1

Andrea Bischoff

07/23/2020



Children's Hospital Colorado

INTERNATIONAL CENTER FOR
**COLORECTAL AND
UROGENITAL CARE**



16-month-old, female patient

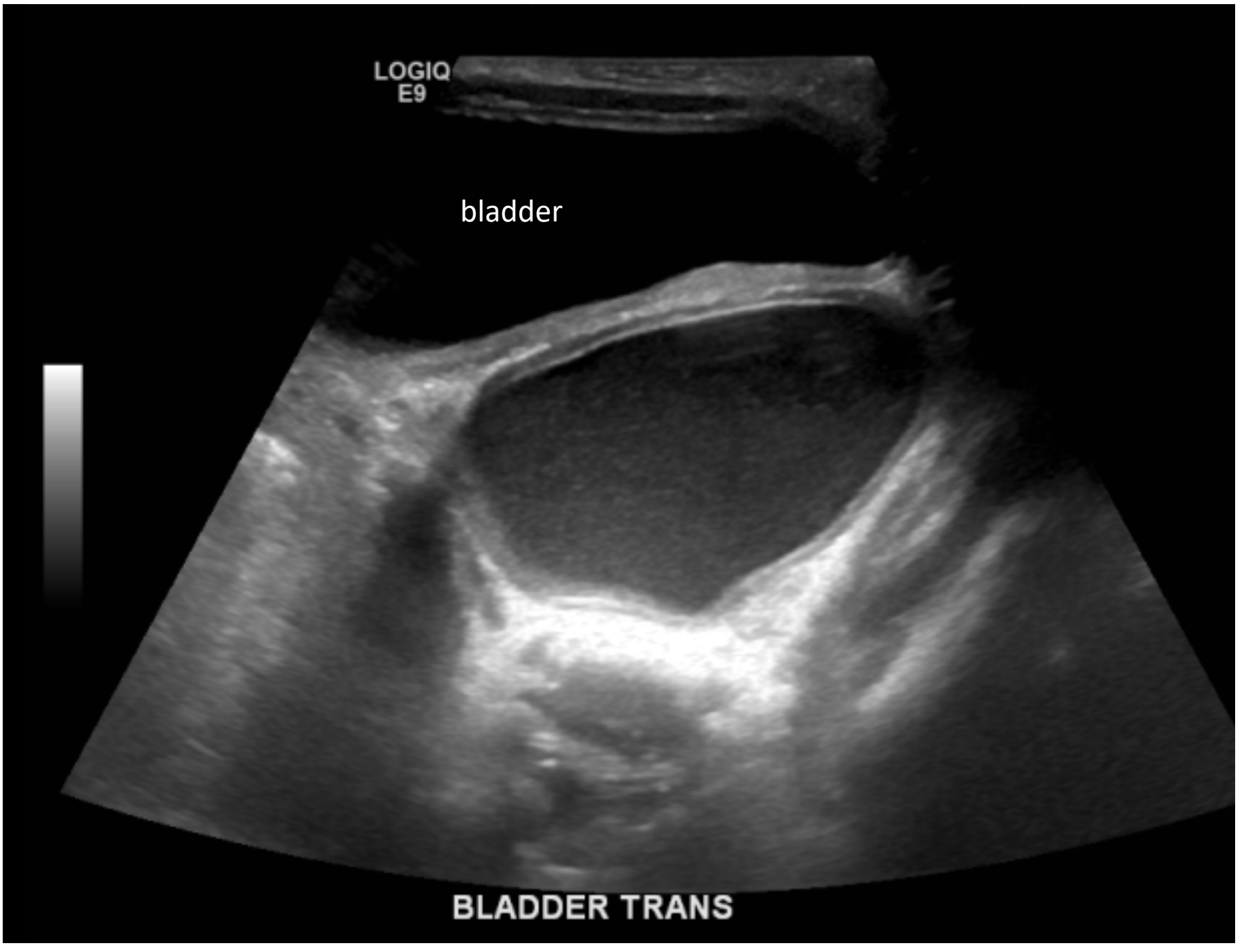
- Prenatally suspected to have ureterocele
- Postnatally images:

LOGIQ
E9

bladder



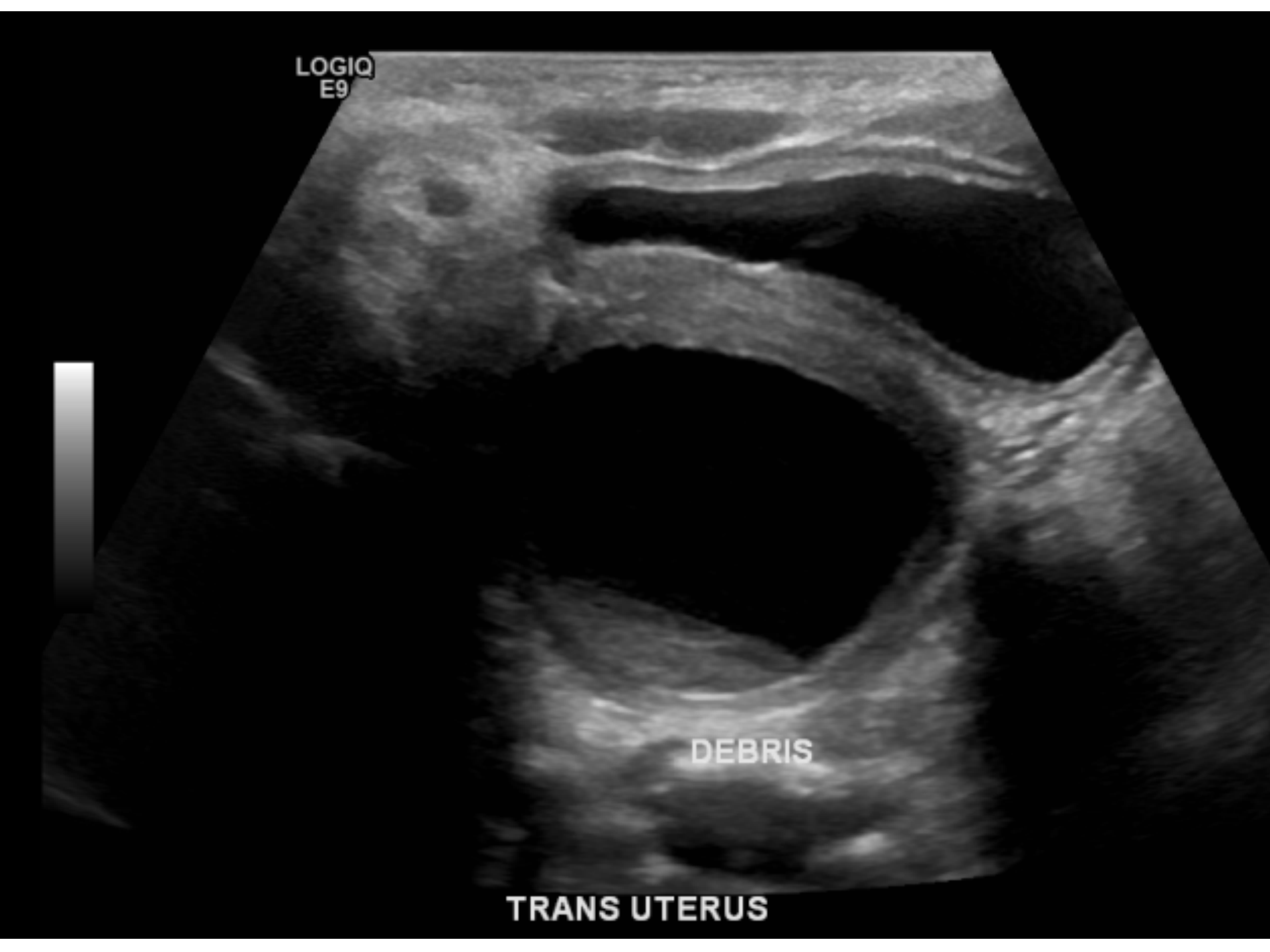
BLADDER TRANS



LOGIQ
E9

DEBRIS

TRANS UTERUS





What is the diagnosis?

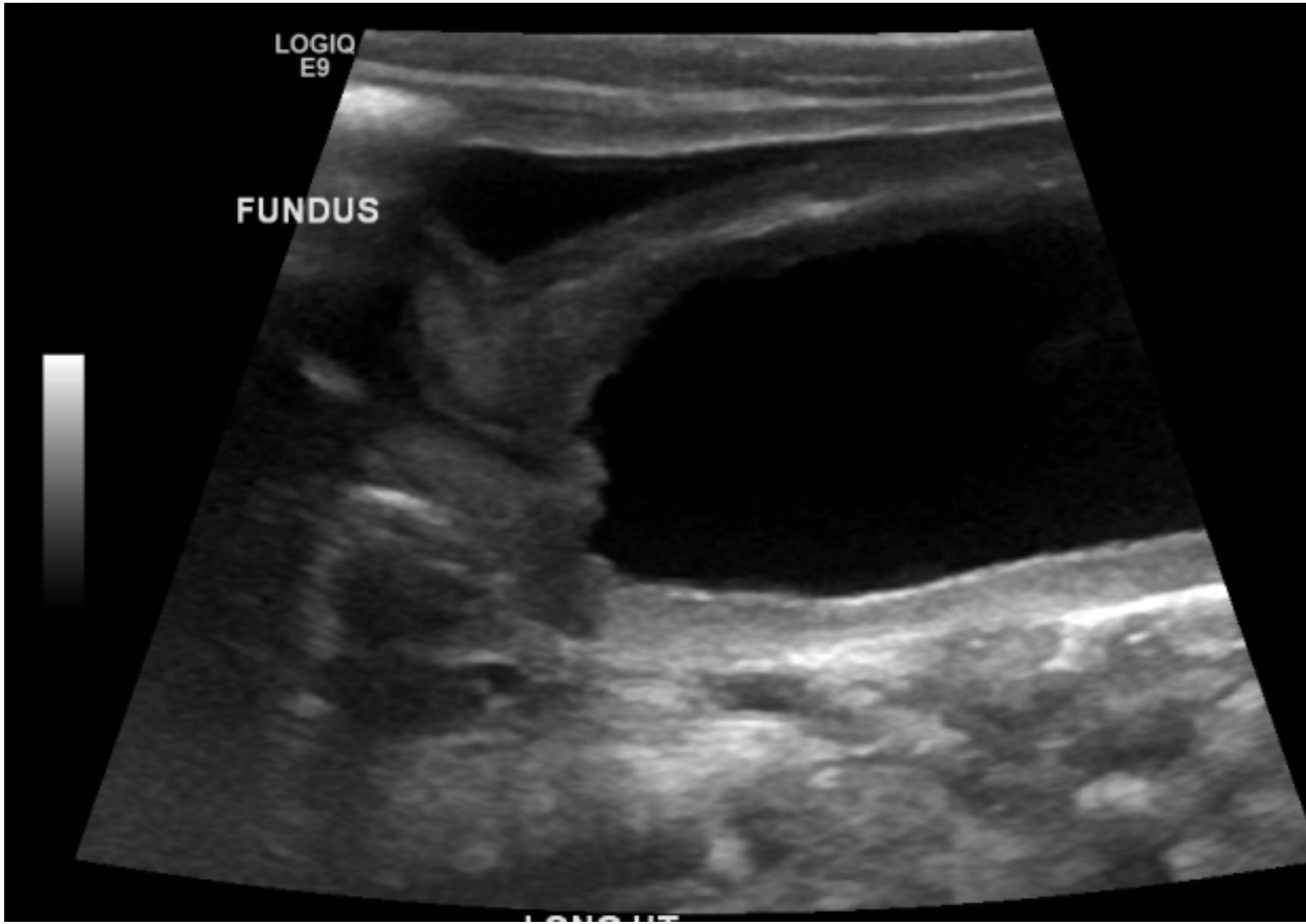
1. Giant hydrocele
2. Ovarian cyst
3. Hydrocolpos
4. I don't know

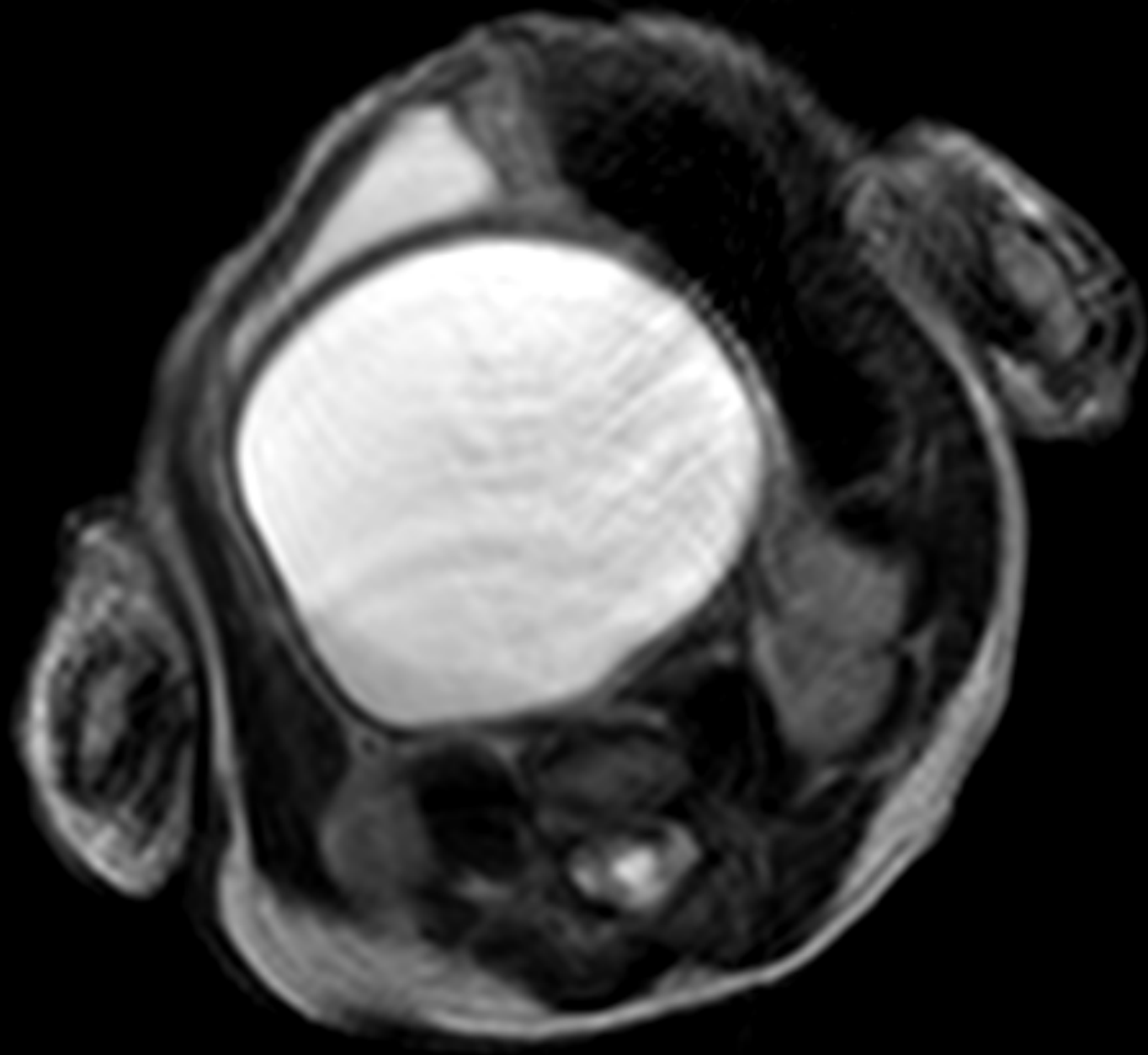
LOGIQ
E9

FUNDUS

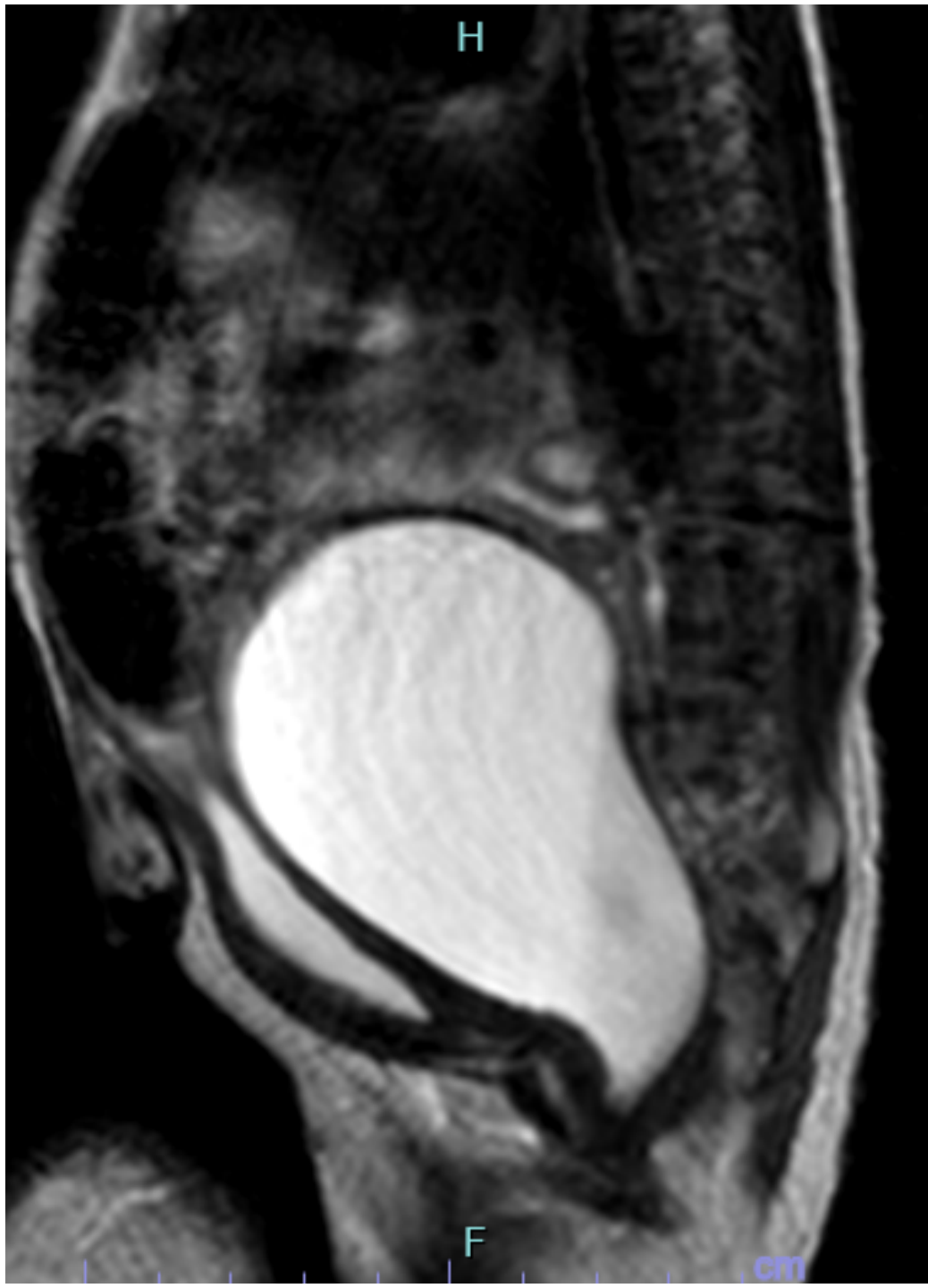


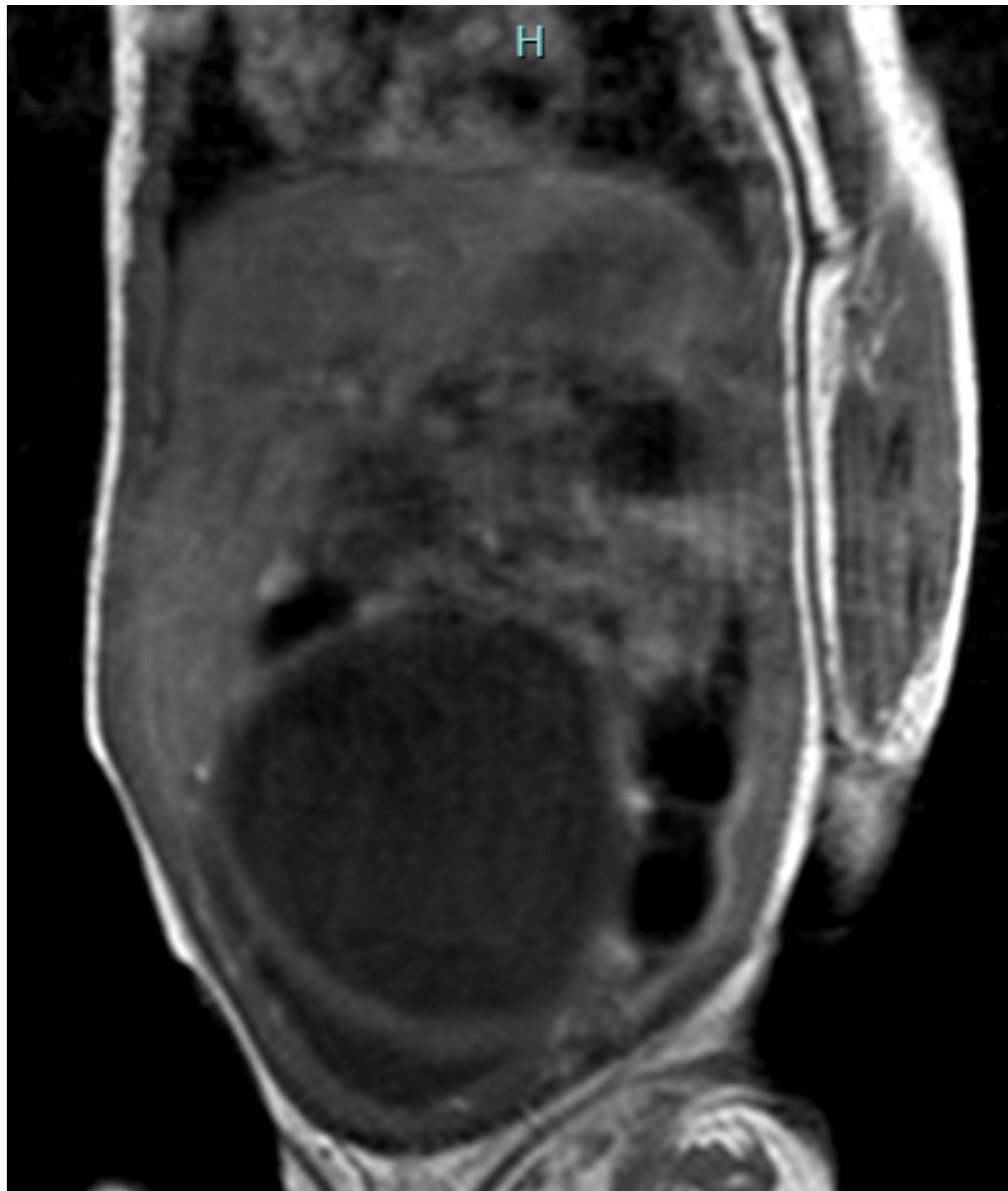
LONG UT





P







Patient underwent excision of urachal cyst and attempted vaginal septum removal

Follow-up image showed re-accumulation of hydrocolpos



Final diagnosis: 2 cm urogenital sinus with normal anus.



