

Case #4

Andrea Bischoff

June 20th, 2024.



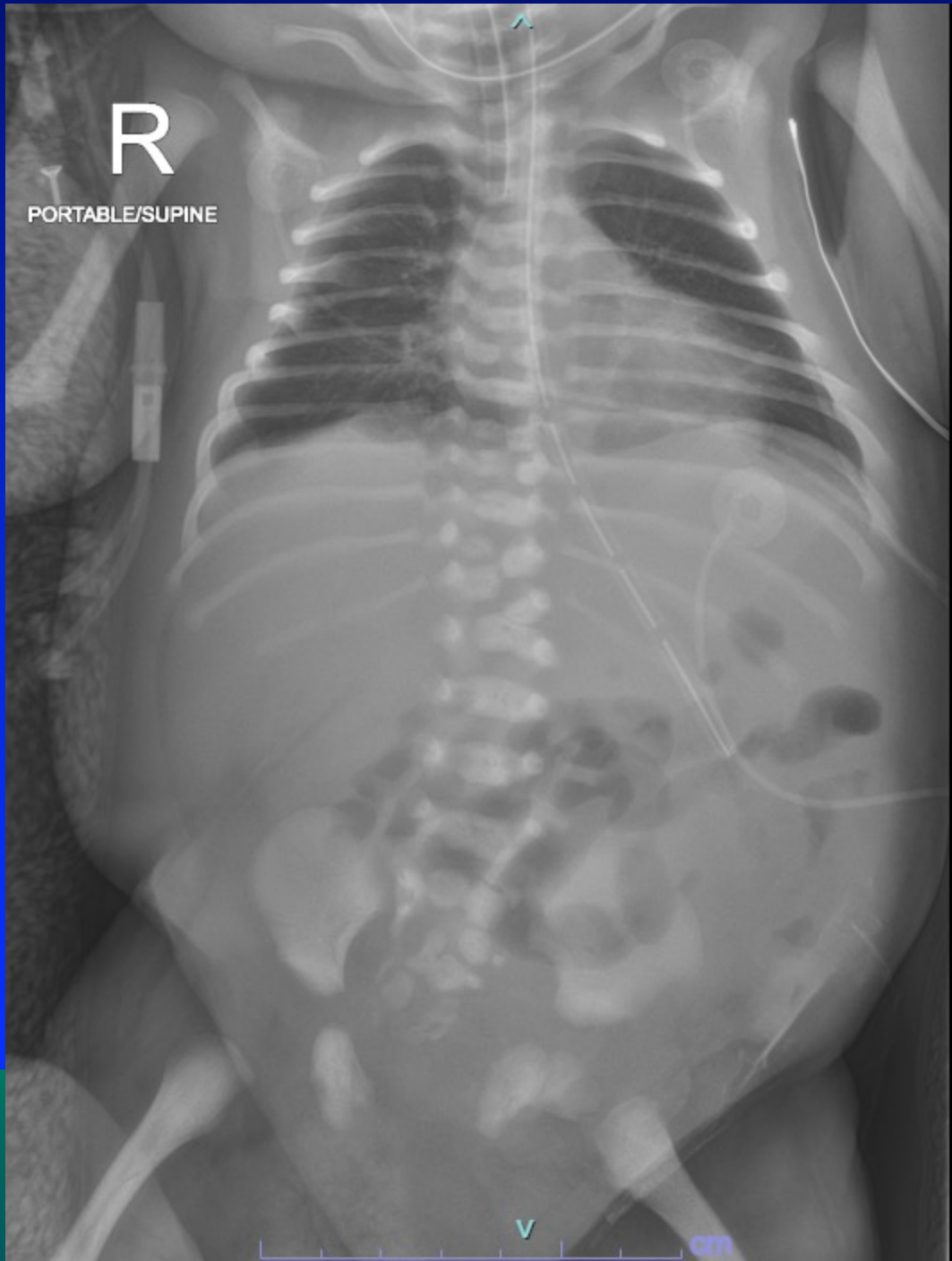Children's Hospital Colorado

INTERNATIONAL CENTER FOR
**COLORECTAL AND
UROGENITAL CARE**

3-month-old female patient born with a “cloaca” at an outside hospital



- Underwent ileostomy and mucous fistula opening
- Two admissions in the PICU with hyponatremia



R

PORTABLE/SUPINE

v

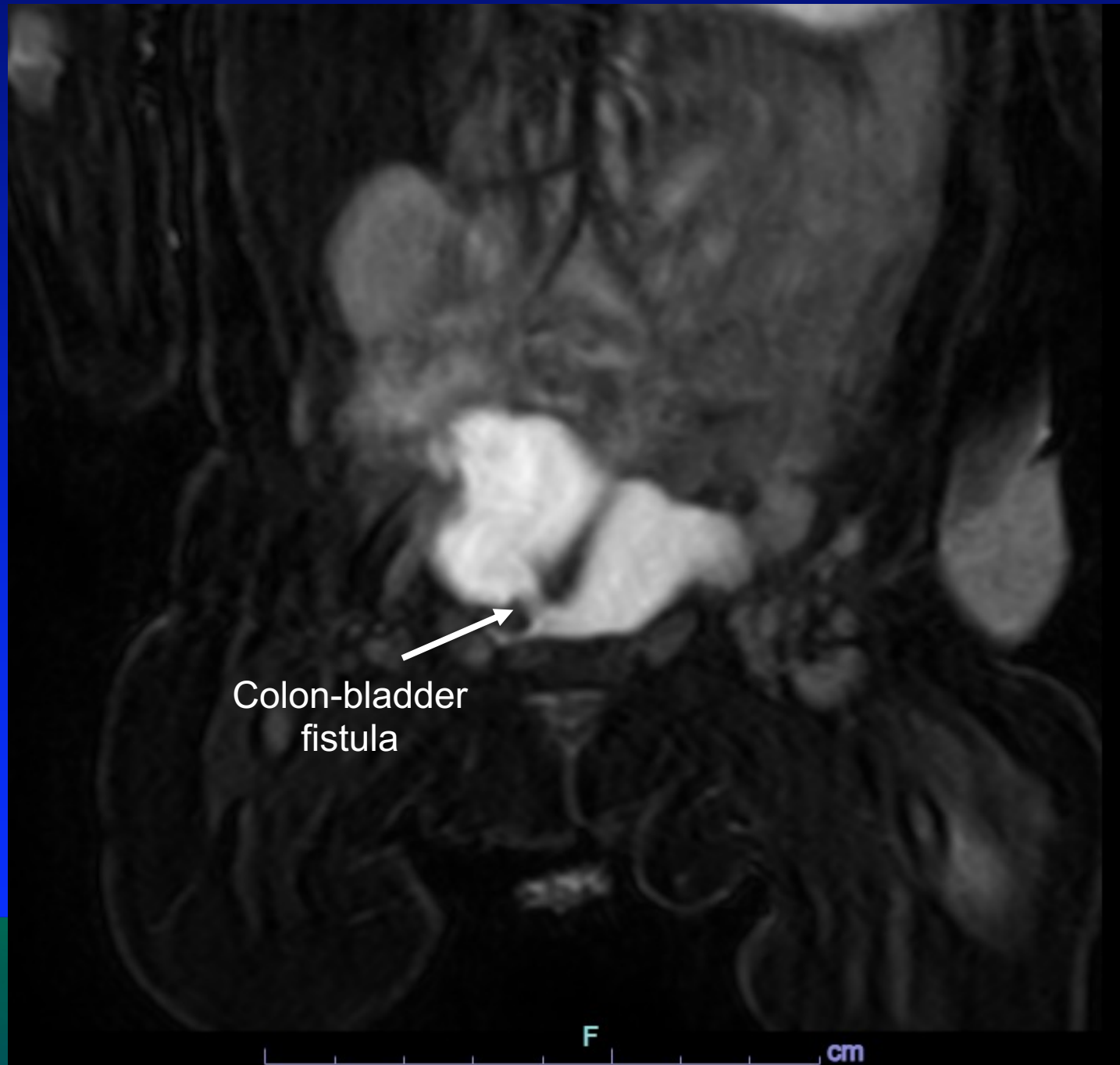cm



NATIONAL CENTER FOR
**RECTAL AND
PERIANAL CARE**

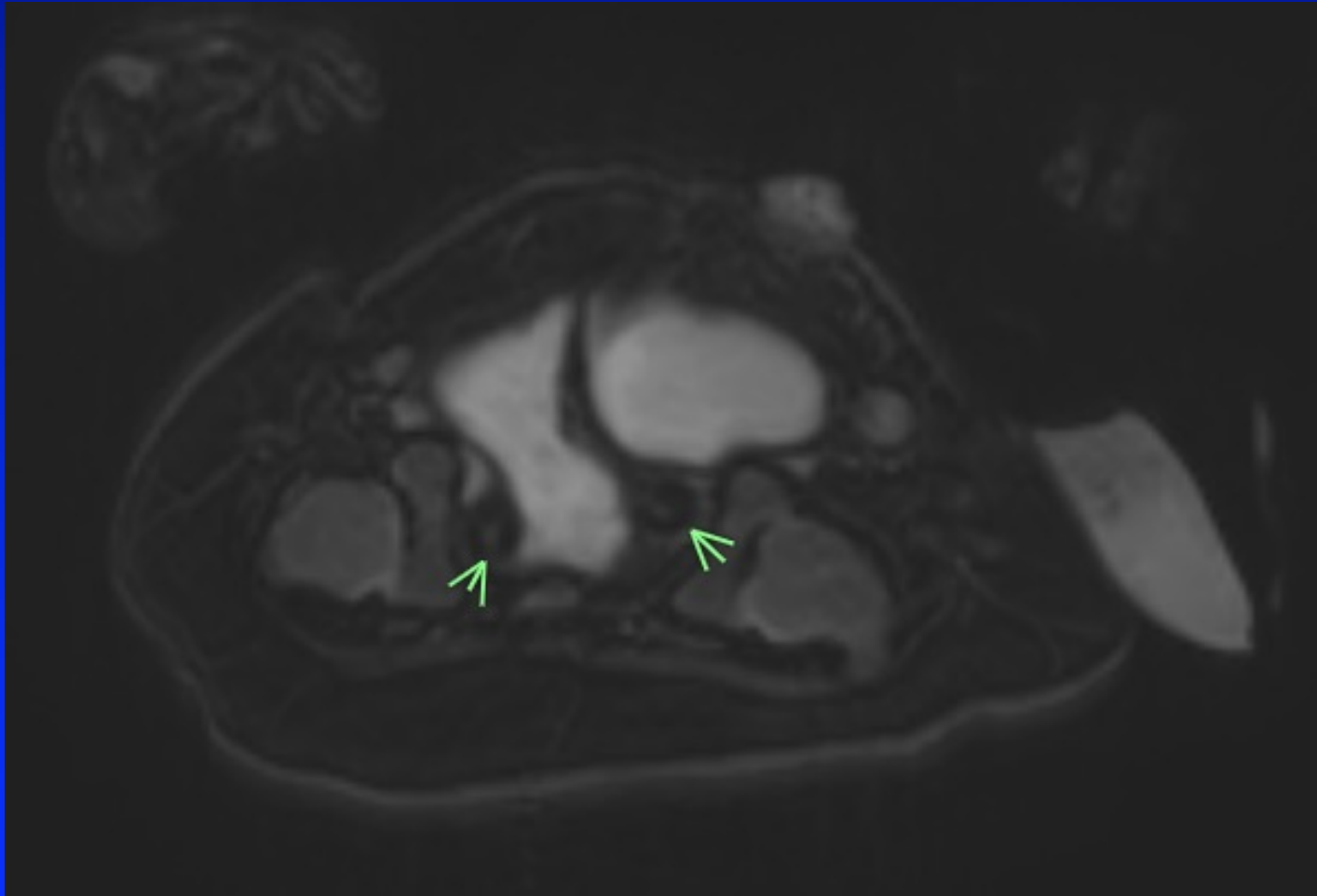
What is the implication of separated pubic bones?

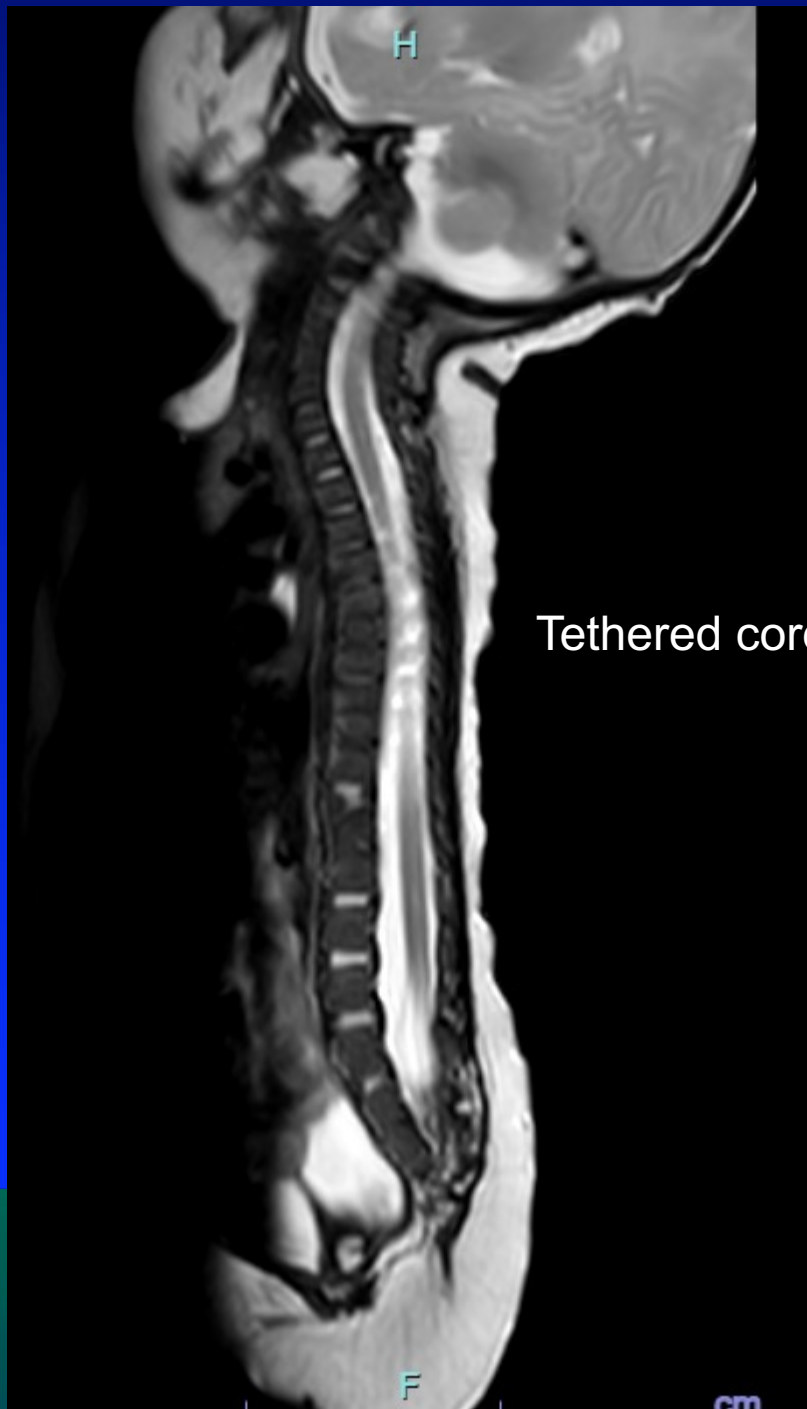
1. Difficulty walking
2. Absent bladderneck
3. I don't know



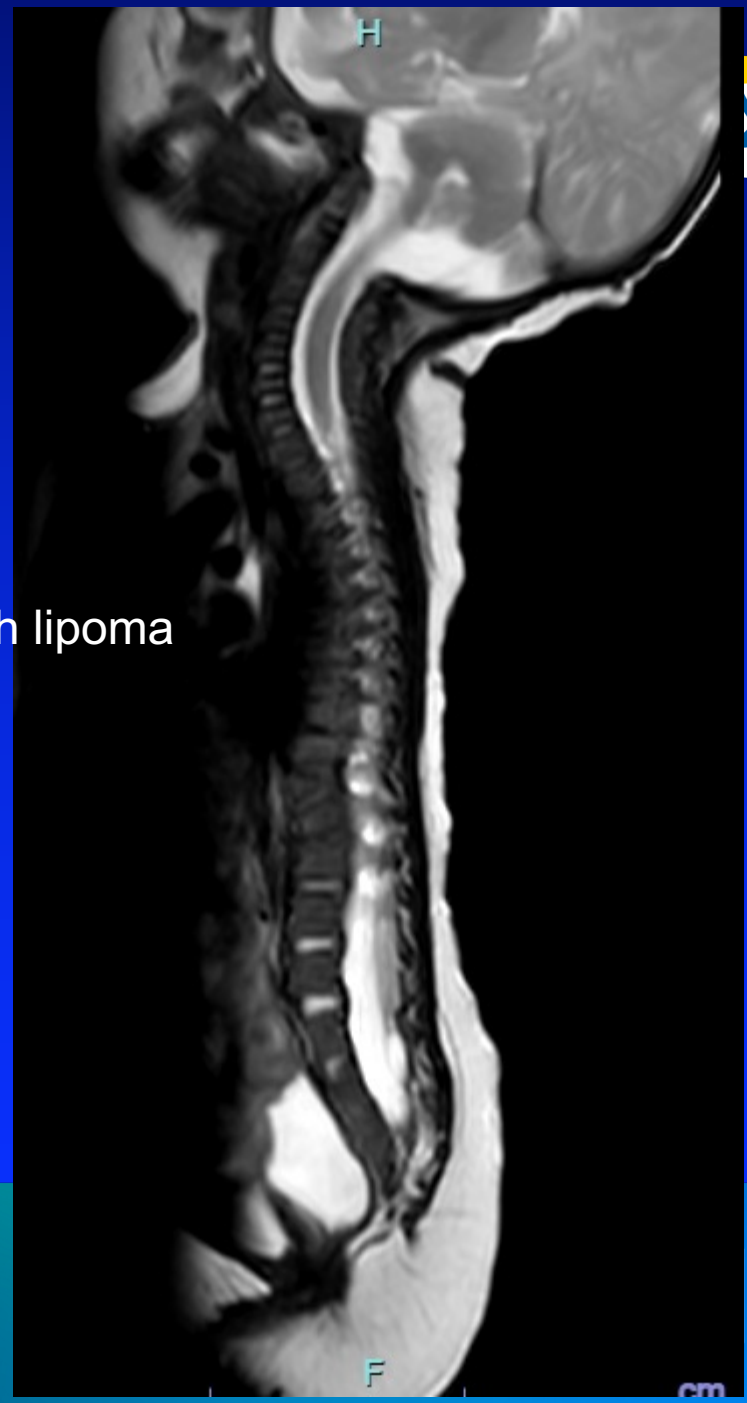Colon-bladder
fistula

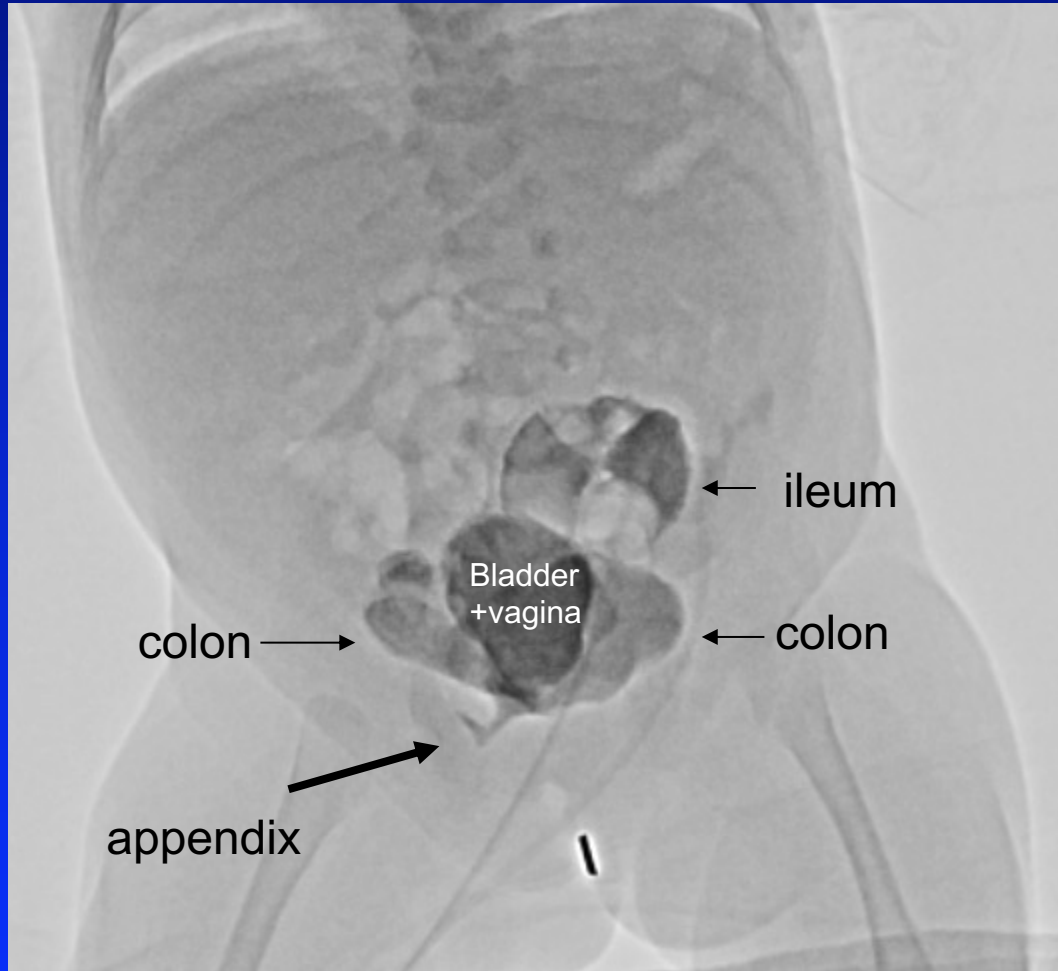
Hemi-uterii



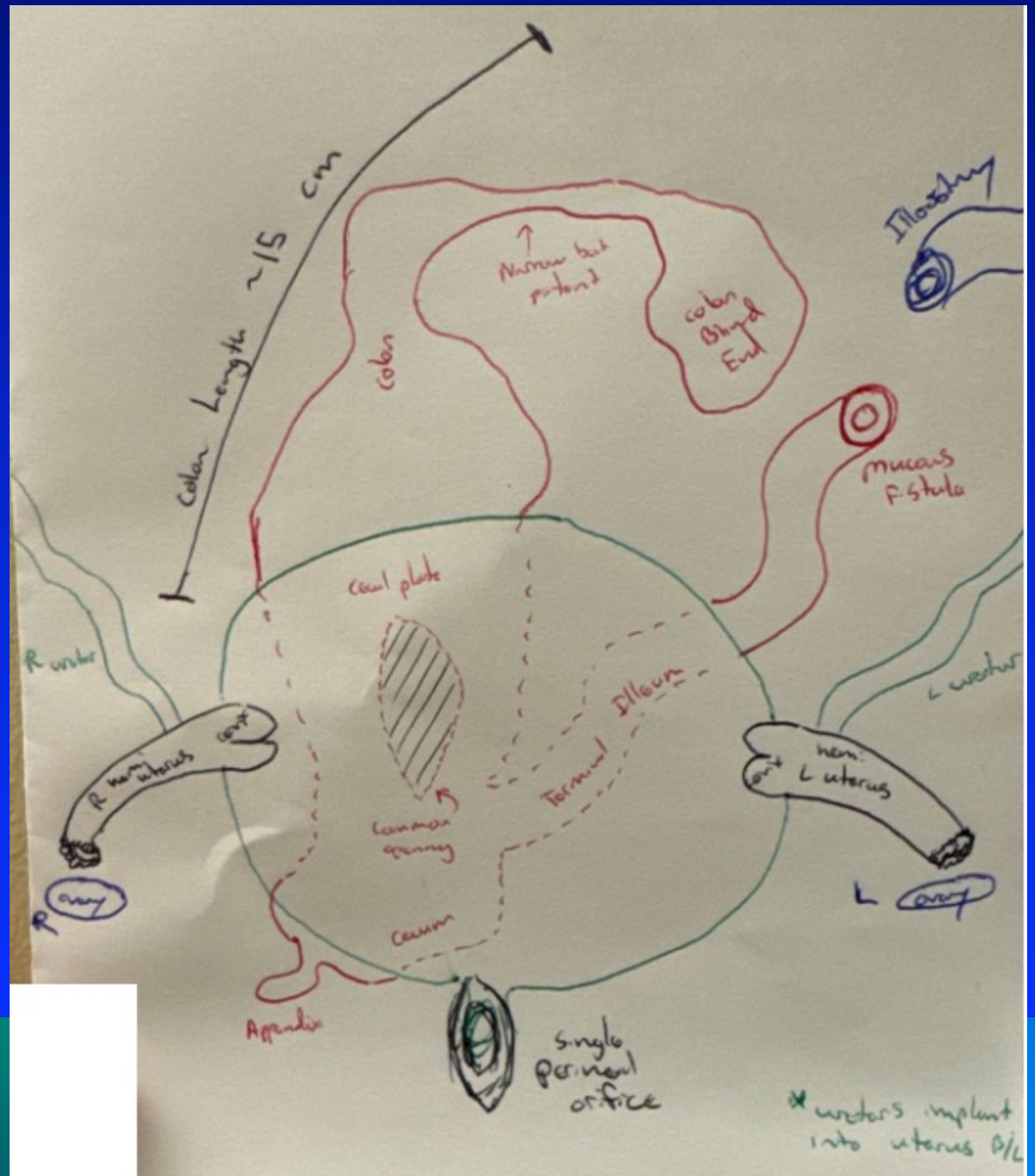


Tethered cord with lipoma

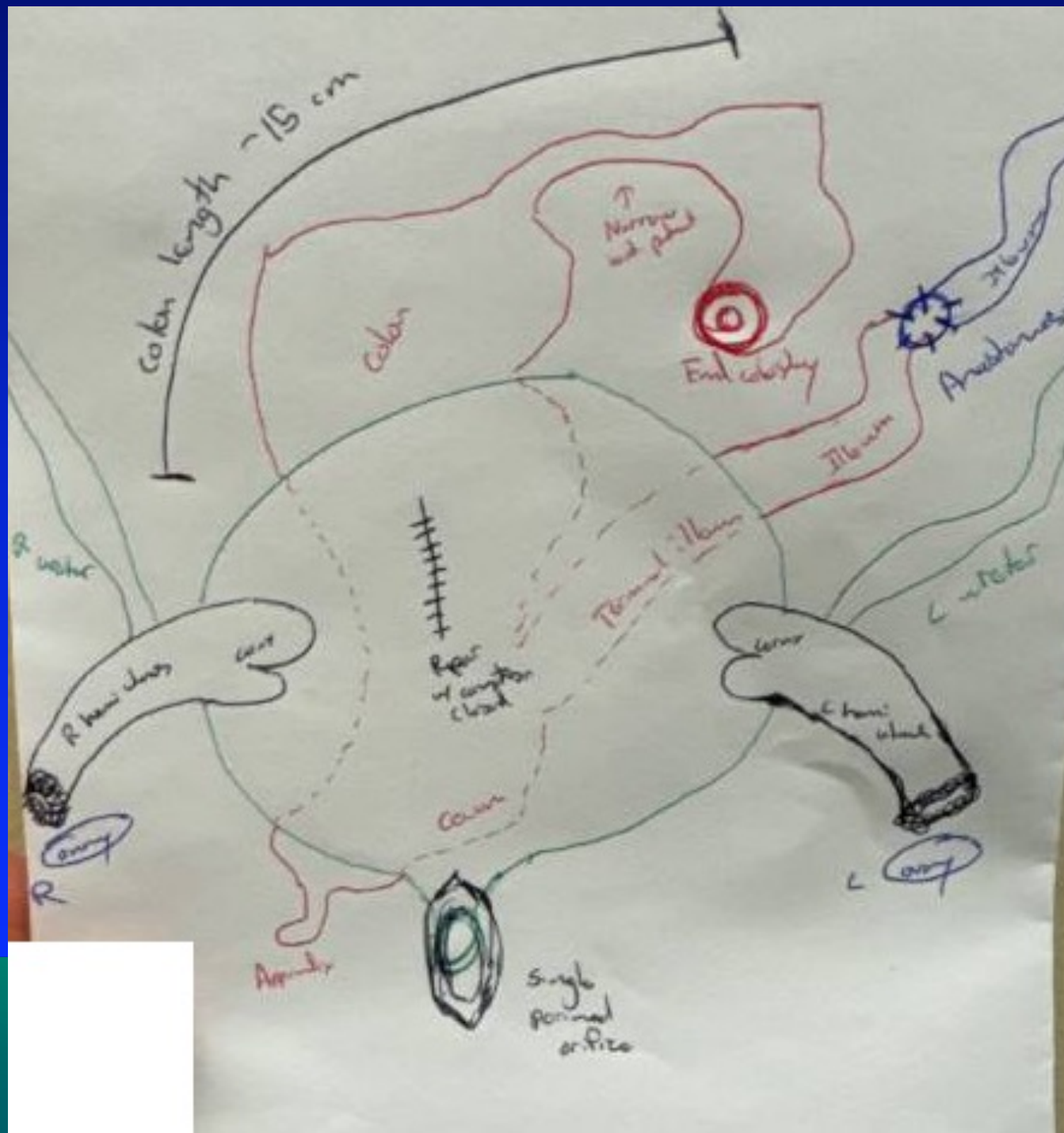


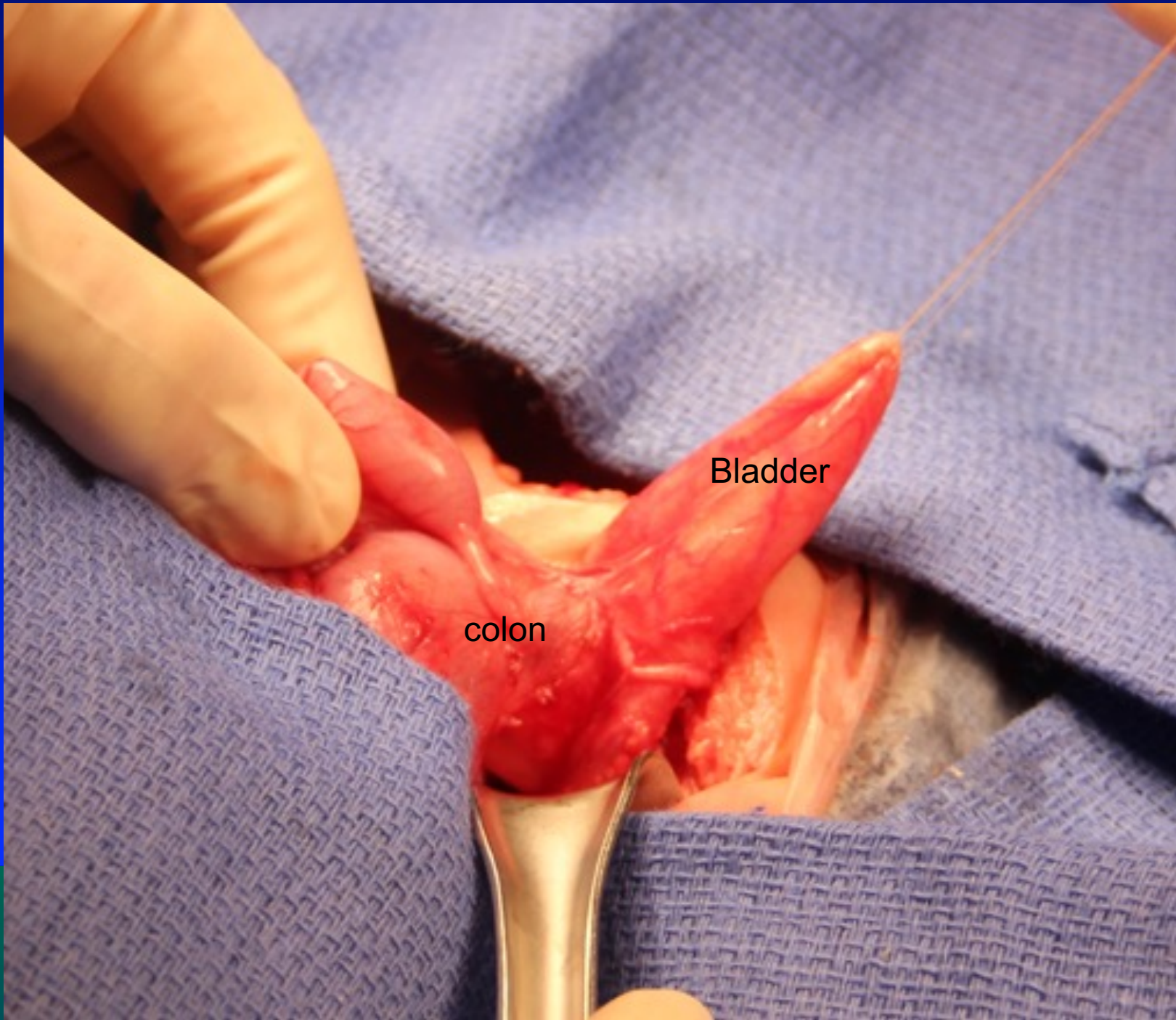


Pre-Op



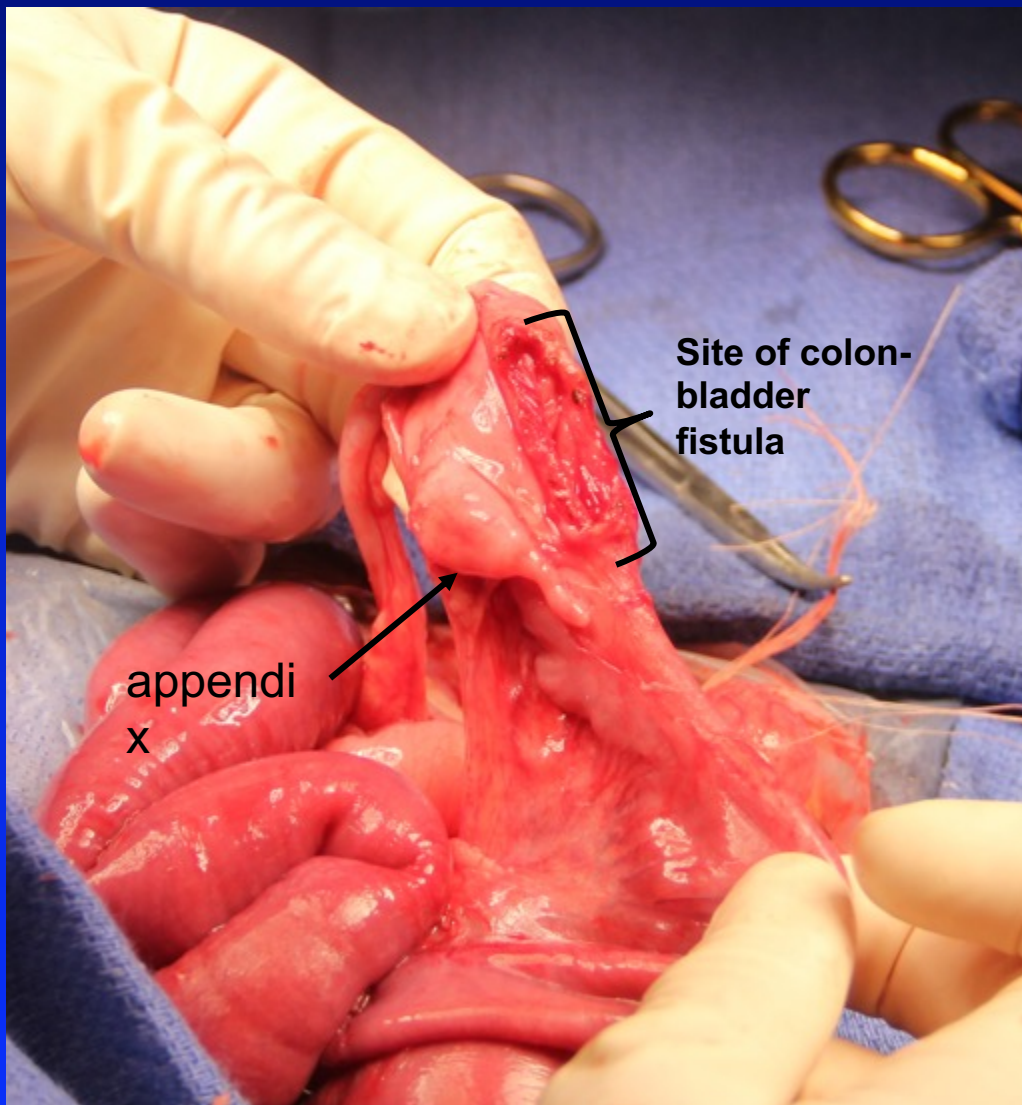
Post-Op

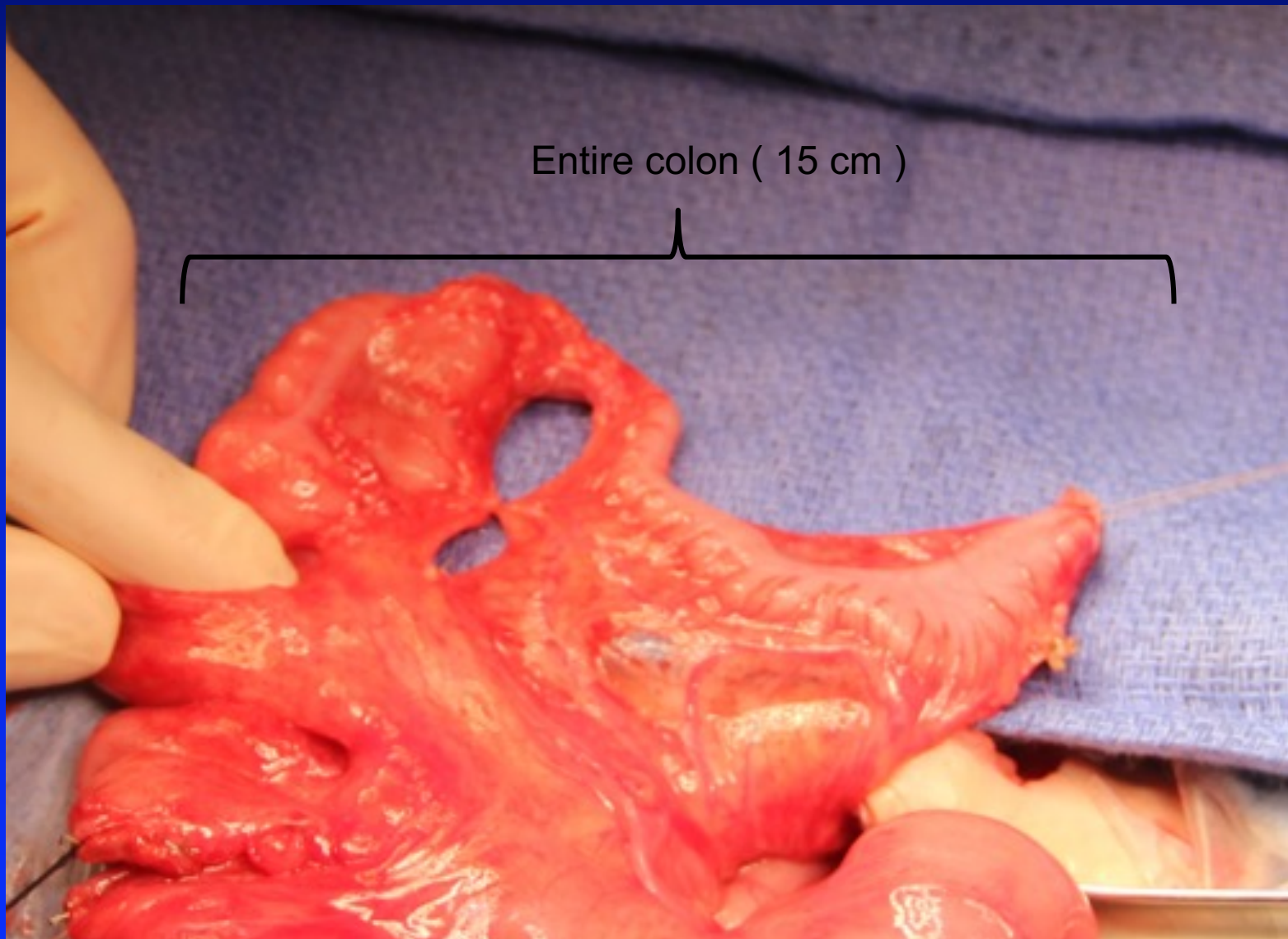




Bladder

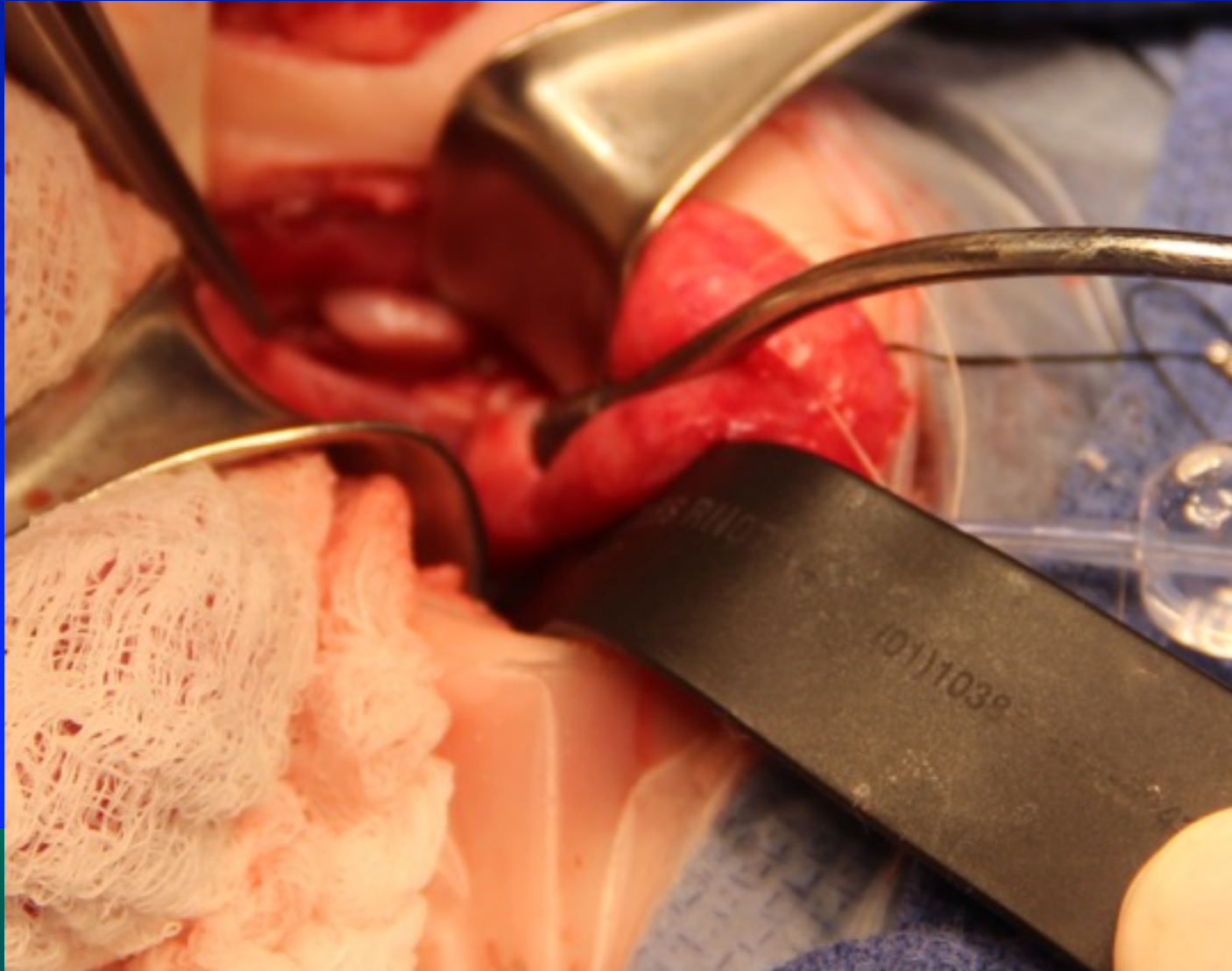
colon

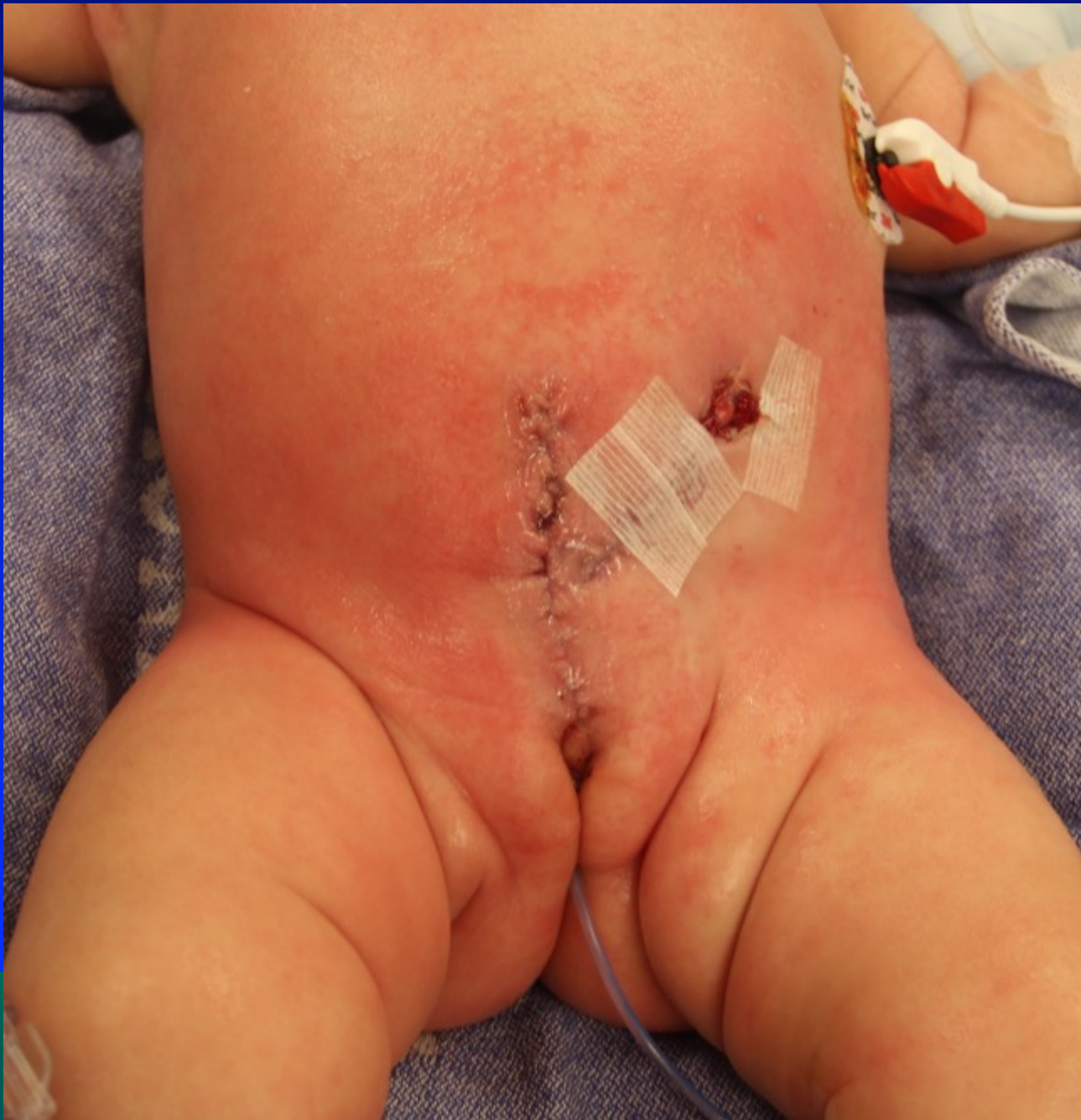



Entire colon (15 cm)

Ureters implanted on each hemi-uteri
(bladder and vaginas as single chamber)







What is next?

At 3 years of age, contrast enema through the stoma and bowel management through the stoma.