

Case #3

Andrea Bischoff

June 20th, 2024.



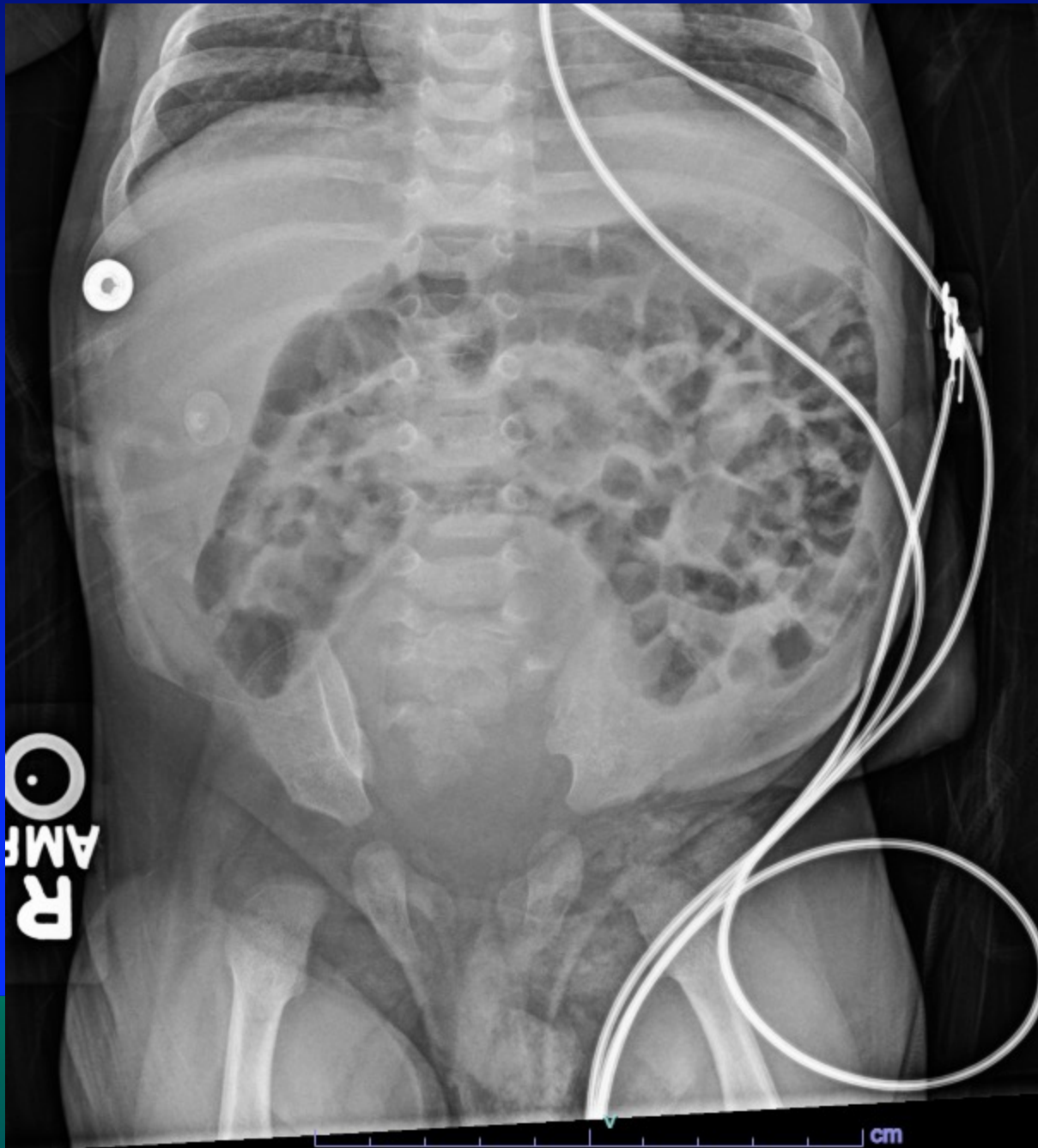
Children's Hospital Colorado

INTERNATIONAL CENTER FOR
**COLORECTAL AND
UROGENITAL CARE**

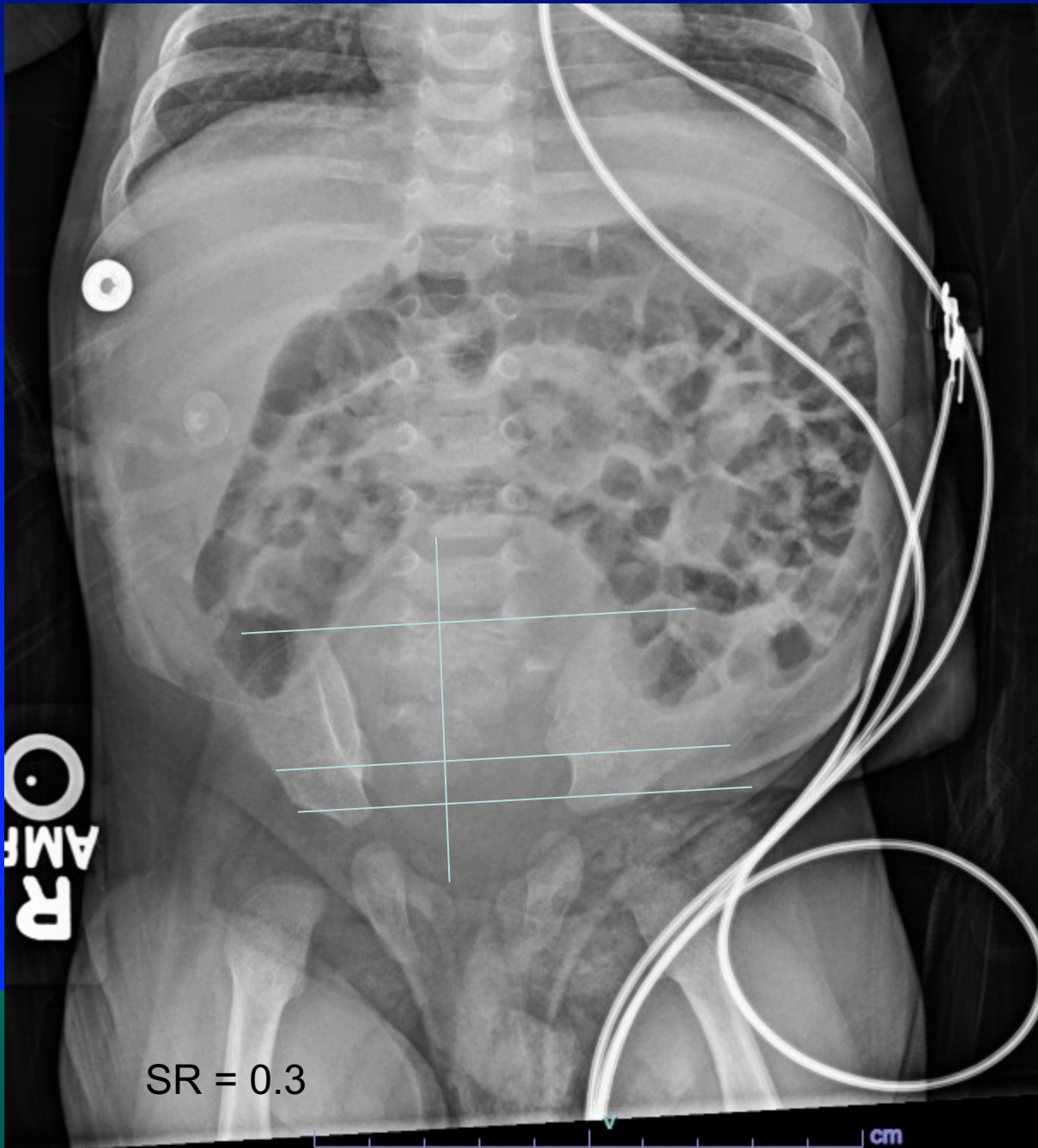
3 months old male patient born in an outside hospital with anorectal malformation




- Underwent colostomy opening
- Two previous admissions to the intensive care unit due to urinary tract infection and sepsis



NATIONAL CENTER FOR
ABDOMINAL AND
GASTROINTESTINAL CARE



 The picture can't be displayed.





The picture can't be displayed.





SR = 0.4


What is his prognosis for bowel control?

1. It depends on the type of anorectal malformation
2. Good
3. Poor
4. I don't know



 The picture can't be displayed.


 The picture can't be displayed.

 The picture can't be displayed.






The picture can't be displayed.





The picture can't be displayed.




 The picture can't be displayed.




bladder

What malformation is this?

1. Recto-bladderneck fistula
2. Recto-prostatic fistula
3. Recto-bulbar fistula
4. I don't know

 The picture can't be displayed.



 The picture can't be displayed.



What could that be?




1. Rectal duplication
2. Ectopic ureter
3. Posterior urethral diverticulum
4. Mullerian remnant
5. I don't know



The picture can't be displayed.




 The picture can't be displayed.





The picture can't be displayed.



 The picture can't be displayed.



The picture can't be displayed.





During PSARP, no abnormal structure was identified. What would you do next?

1. Voiding cystogram
2. Repeat the MRI
3. CT scan
4. I don't know

Voiding cystogram



 The picture can't be displayed.


 The picture can't be displayed.





The picture can't be displayed.



 The picture can't be displayed.






The picture can't be displayed.




Cystic structure


Scheduled for repeated cystoscopy + colostomy closure and exploratory laparotomy



 The picture can't be displayed.

Cystic
Structure 
Filled with
urine




 The picture can't be displayed.



ns



 The picture can't be displayed.



Pathology

- Ectopic ureter without a kidney remnant.