



CLINICAL CASE

INTERNATIONAL COLORECTAL WEB MEETING

ELIANE HEFTYE SANCHEZ MD

Colorectal Surgery Resident Fellow

KARLA SANTOS JASSO MD

Chief of department

MEDICAL RECORDS

Male, 6 years old

DIAGNOSIS

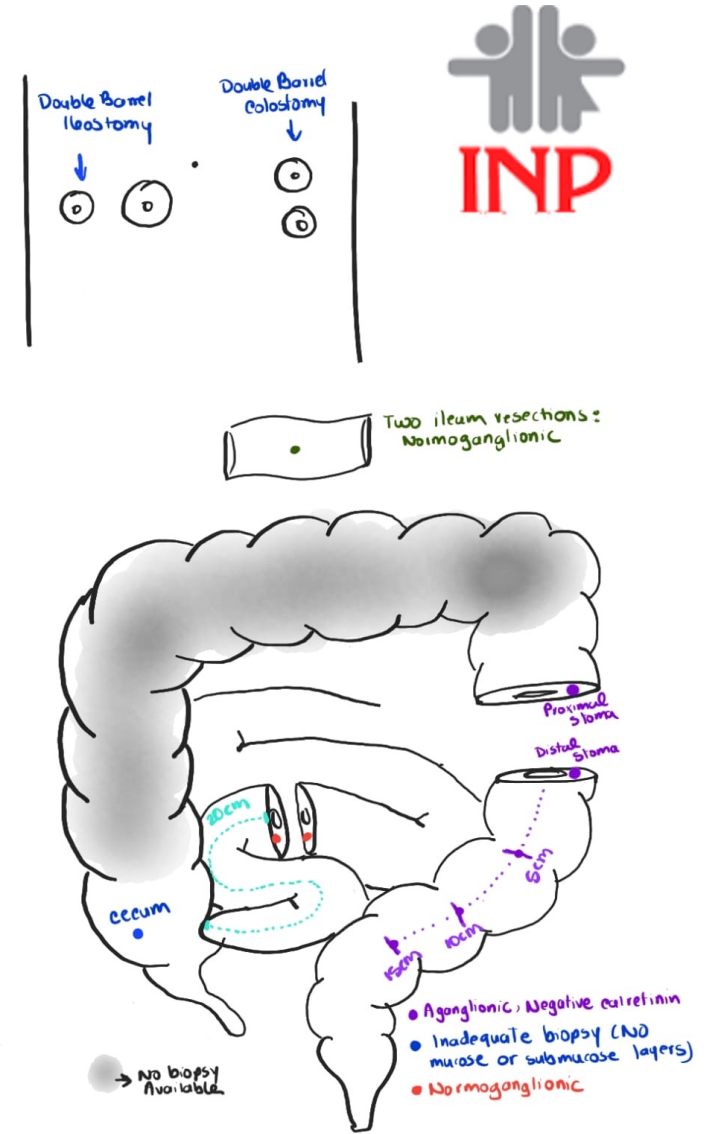
Down Syndrome

4 surgical events
(colostomy and
posterior ileostomy)

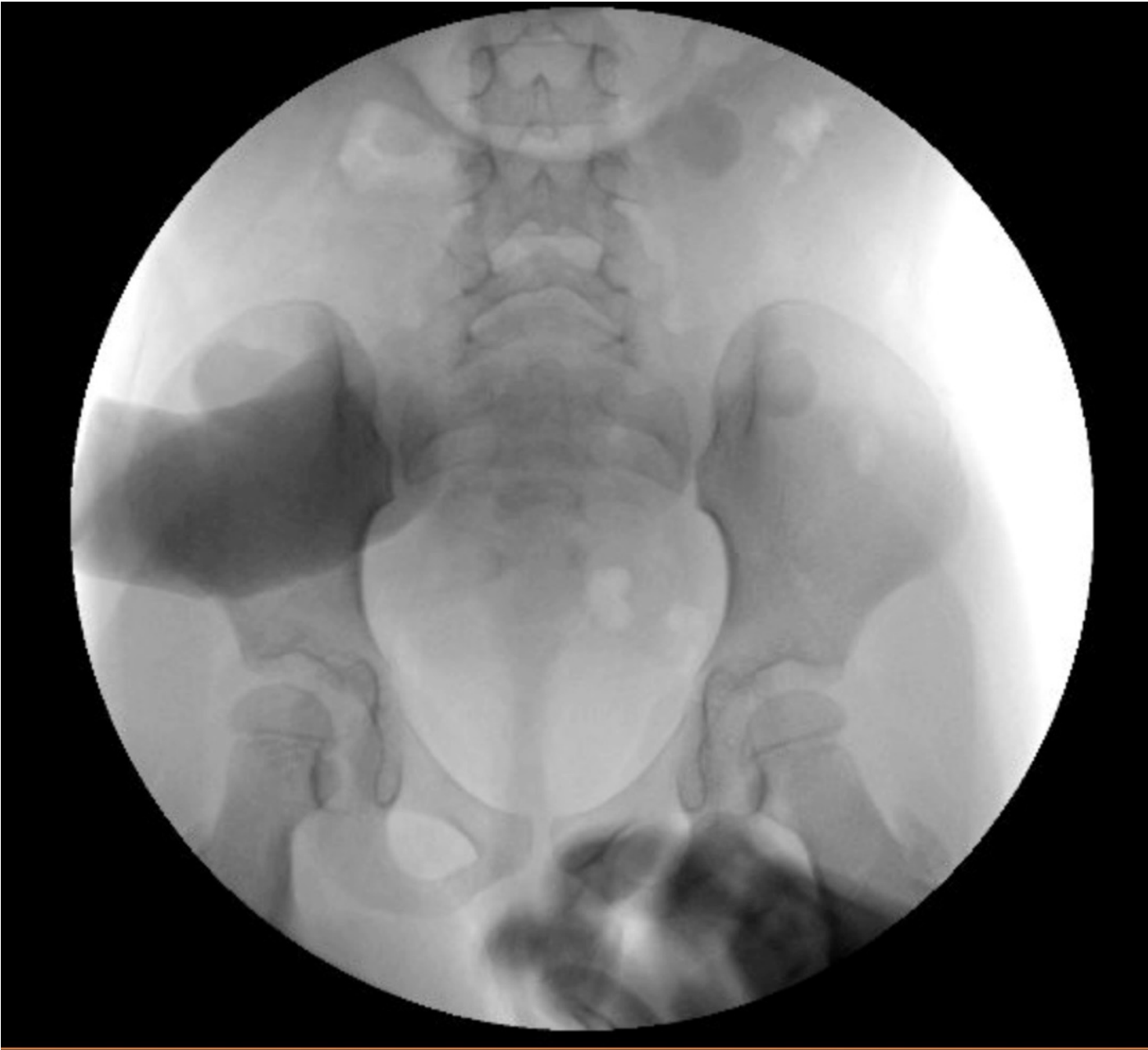- 1 colostomy two stomas (1st day after birth)
- 2 ileostomy two stomas (1 yo)
- 3 redo ileostomy (4 yo) occlusion bowel
- 4 redo ileostomy (4 yo + 3 months)

Recurrent events of
enterocolitis

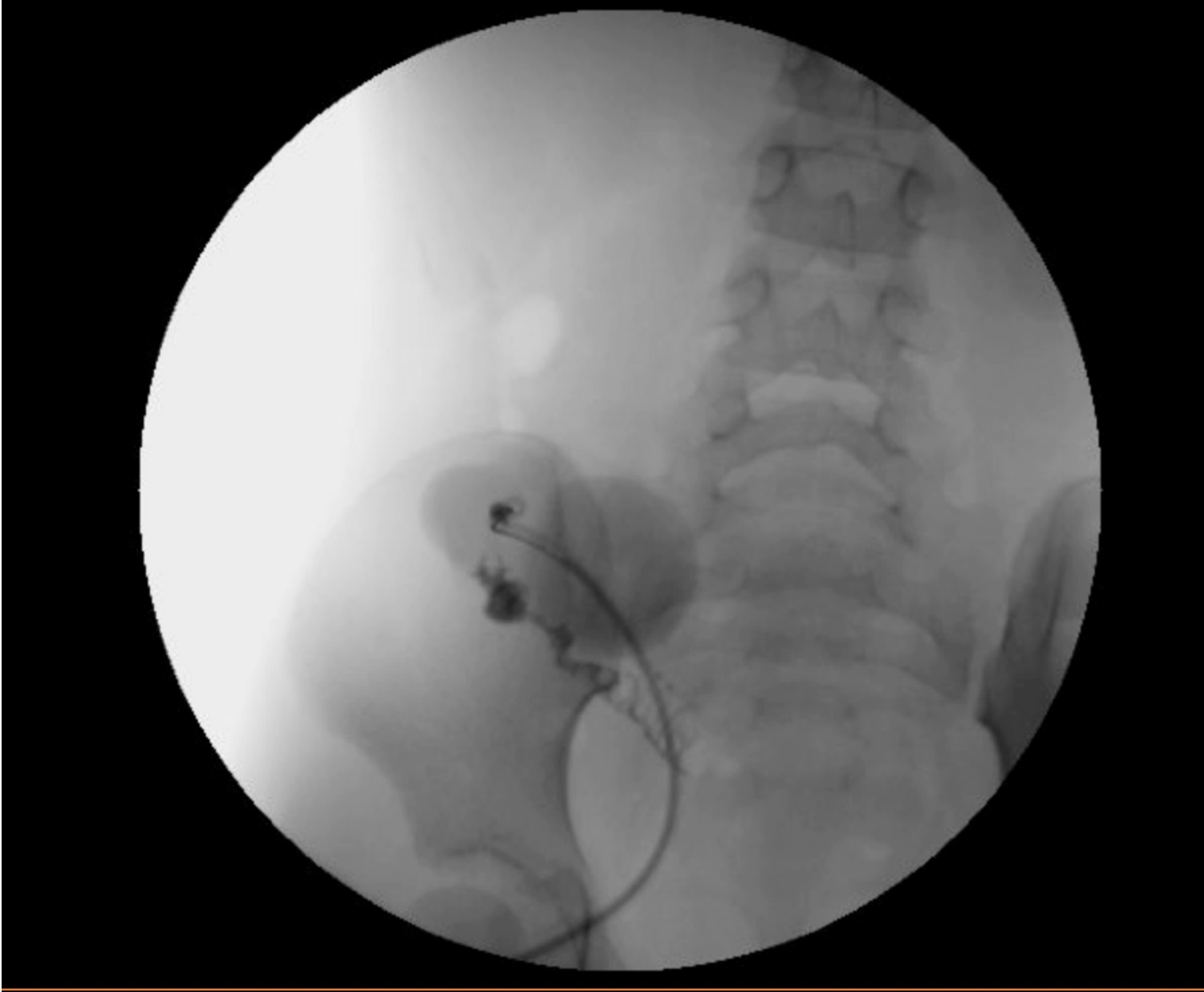Treatment: Irrigations + Metronidazole



Contrast enema



Ileogram
(contrast)

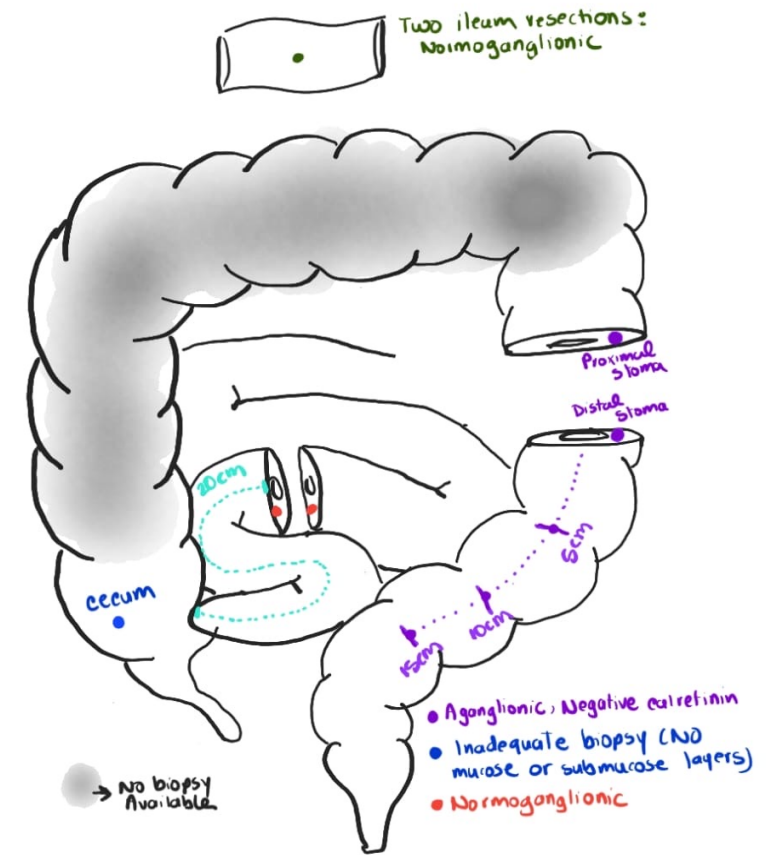
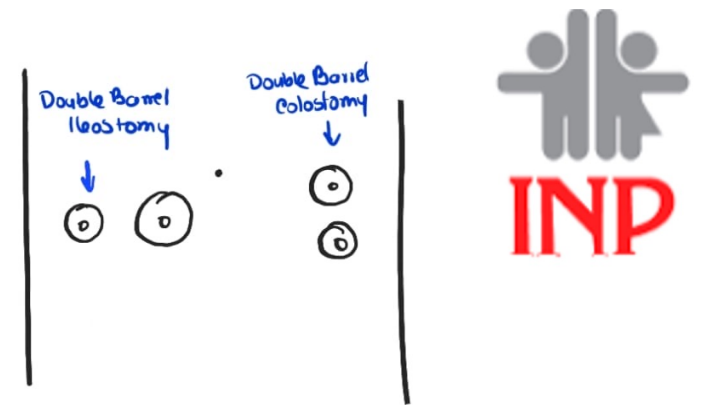


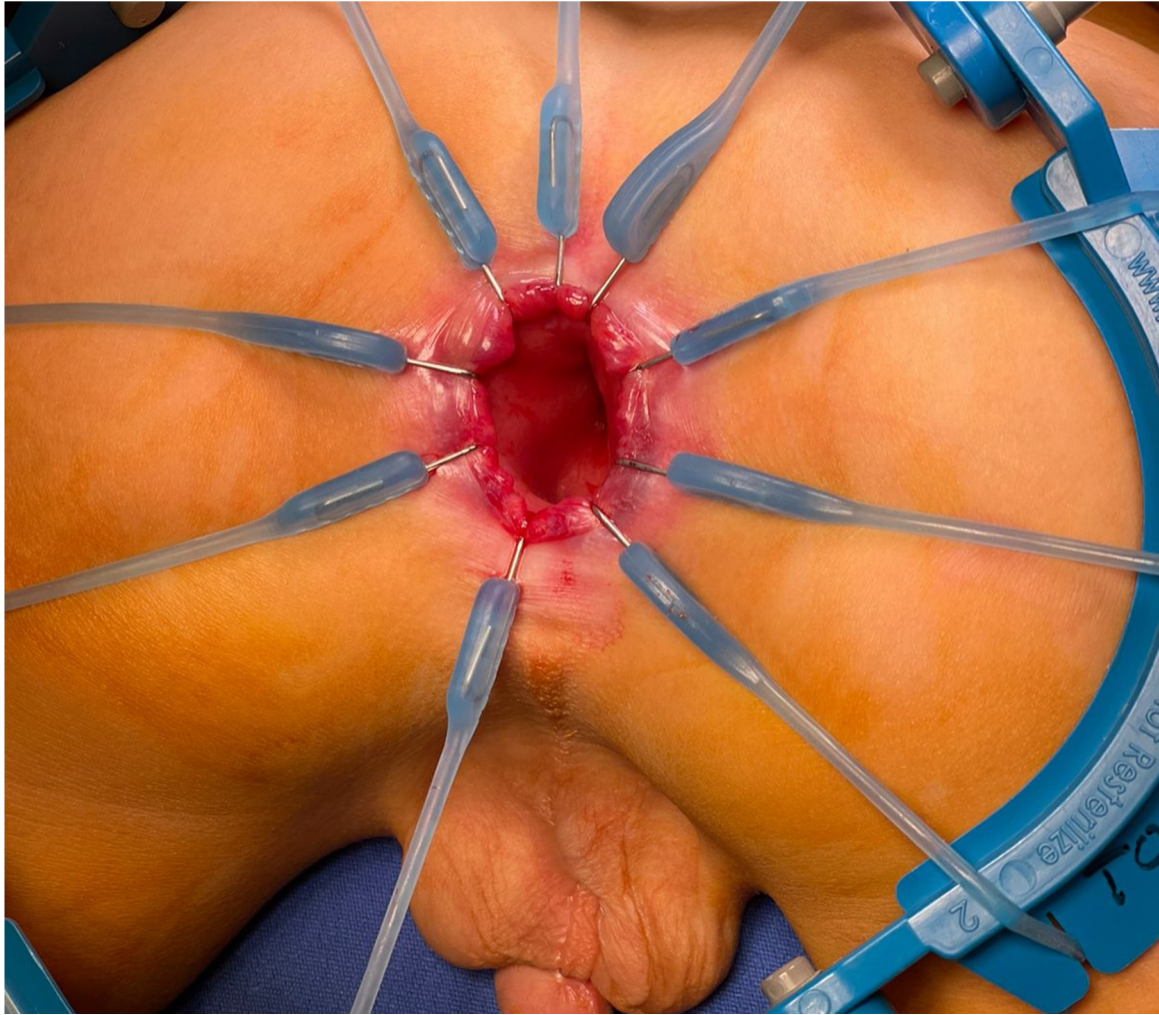Based on this contrast study and background information, what would you plan for your surgery?

- ▶ A) Colon mapping
- ▶ B) Biopsy of the cecum
- ▶ C) Biopsy of right colon
- ▶ D) I have no idea

SURGICAL PLAN

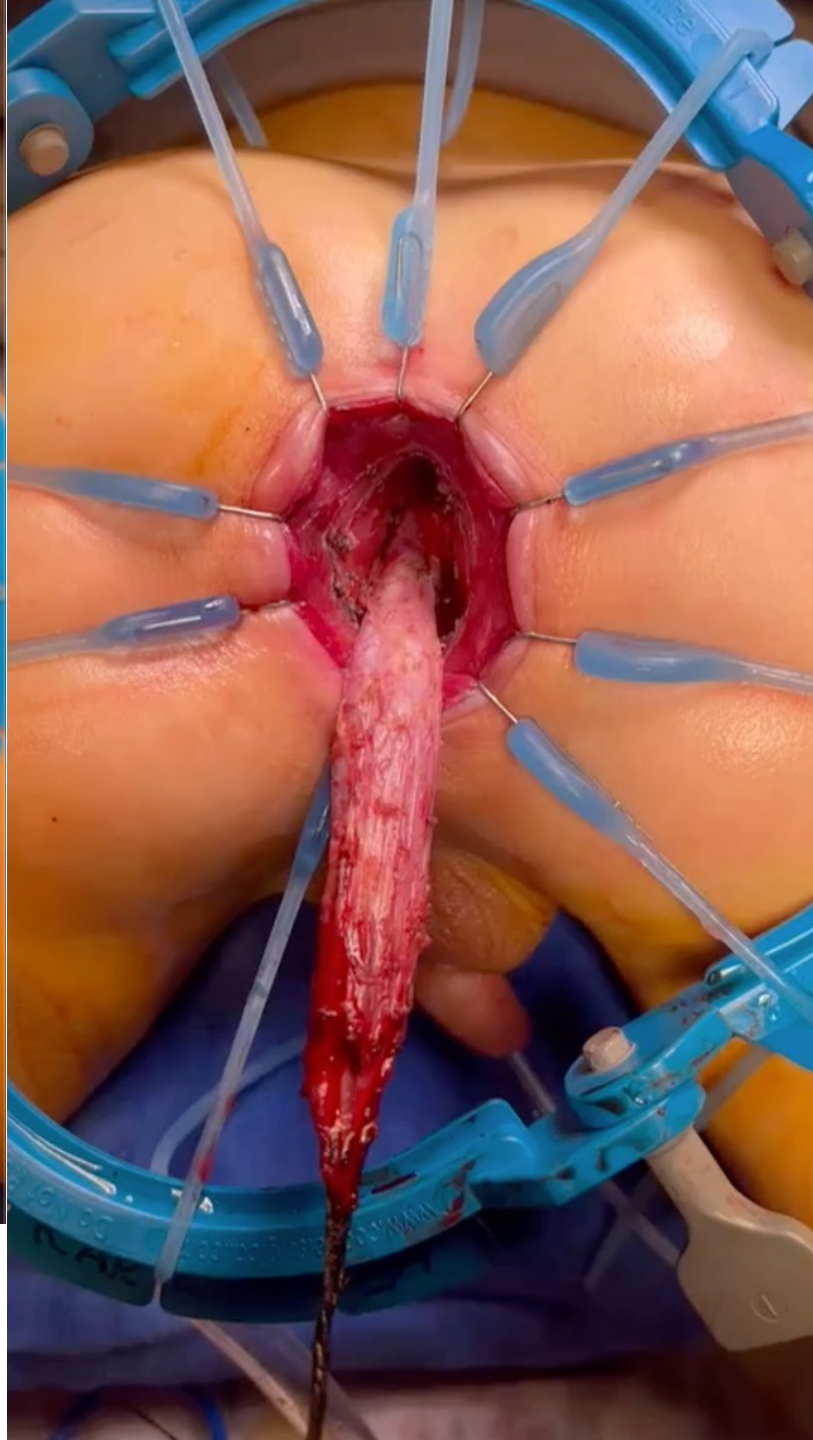
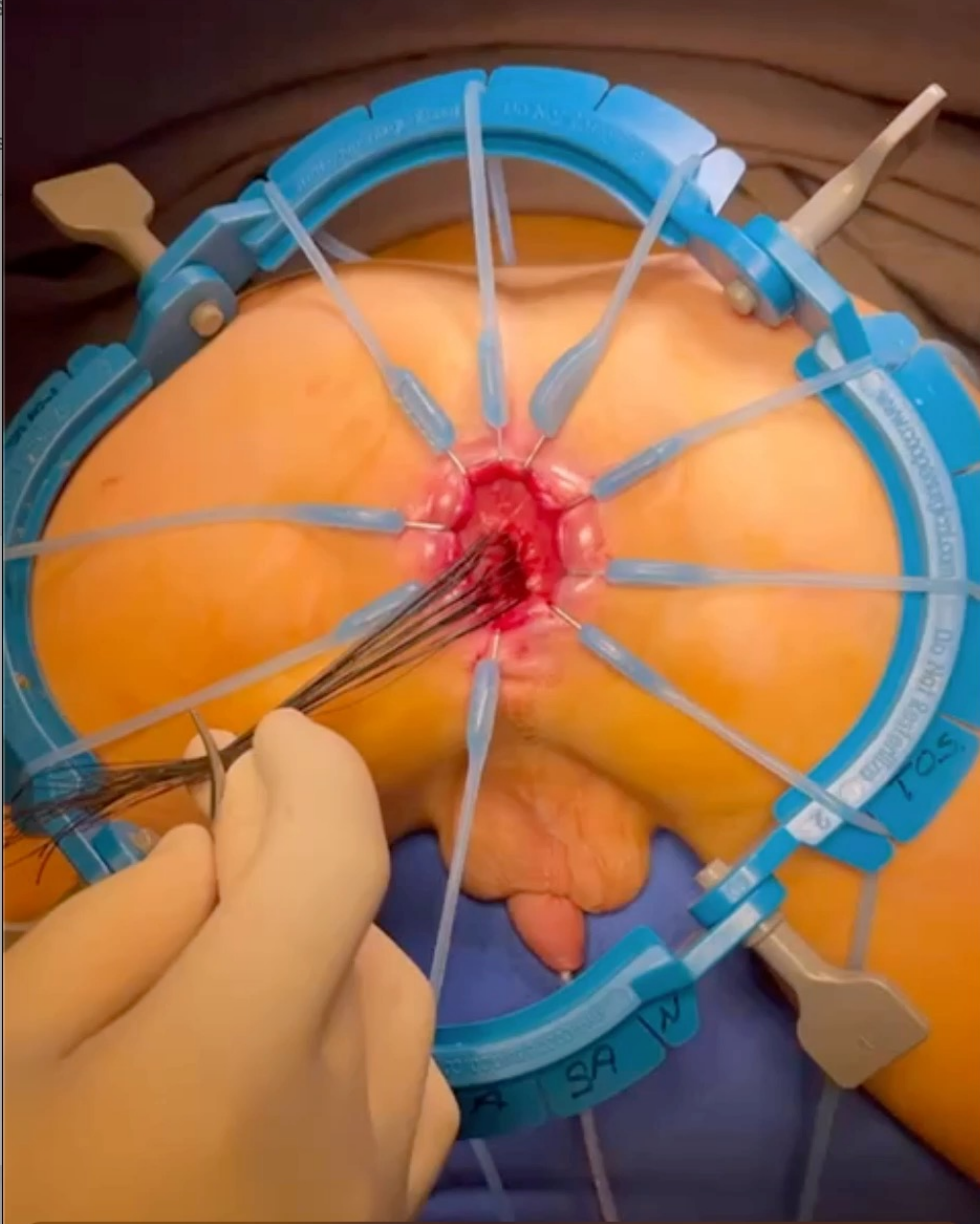
- ▶ Preoperative plan
 - ▶ Metronidazole + irrigations
- ▶ Surgery plan
 - ▶ Surgical biopsy of a segment of the appendix
 - ▶ Ileal Swenson abdominal and transanal pull-through + central venous catheter for parenteral nutrition



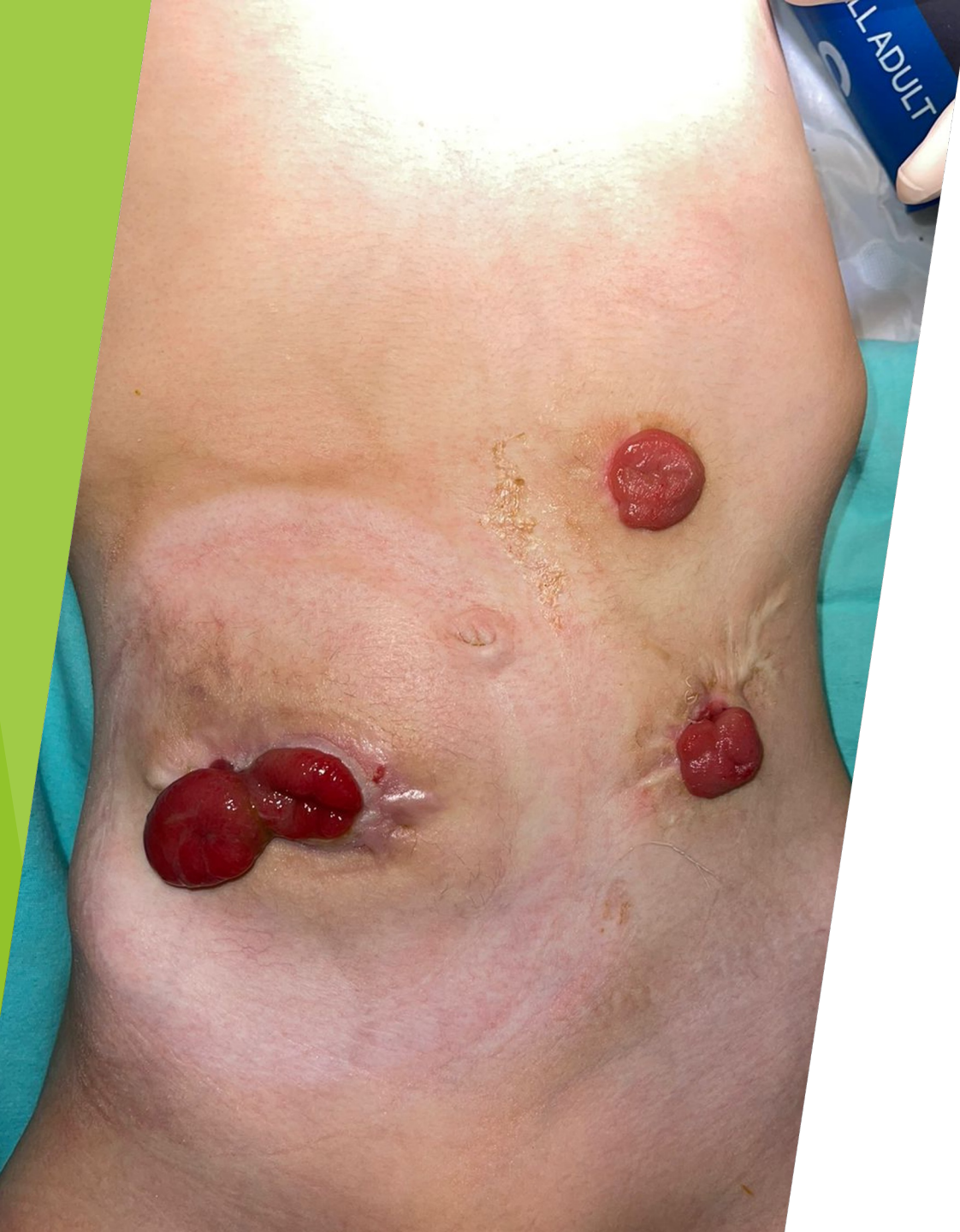

TRANSANAL APPROACH

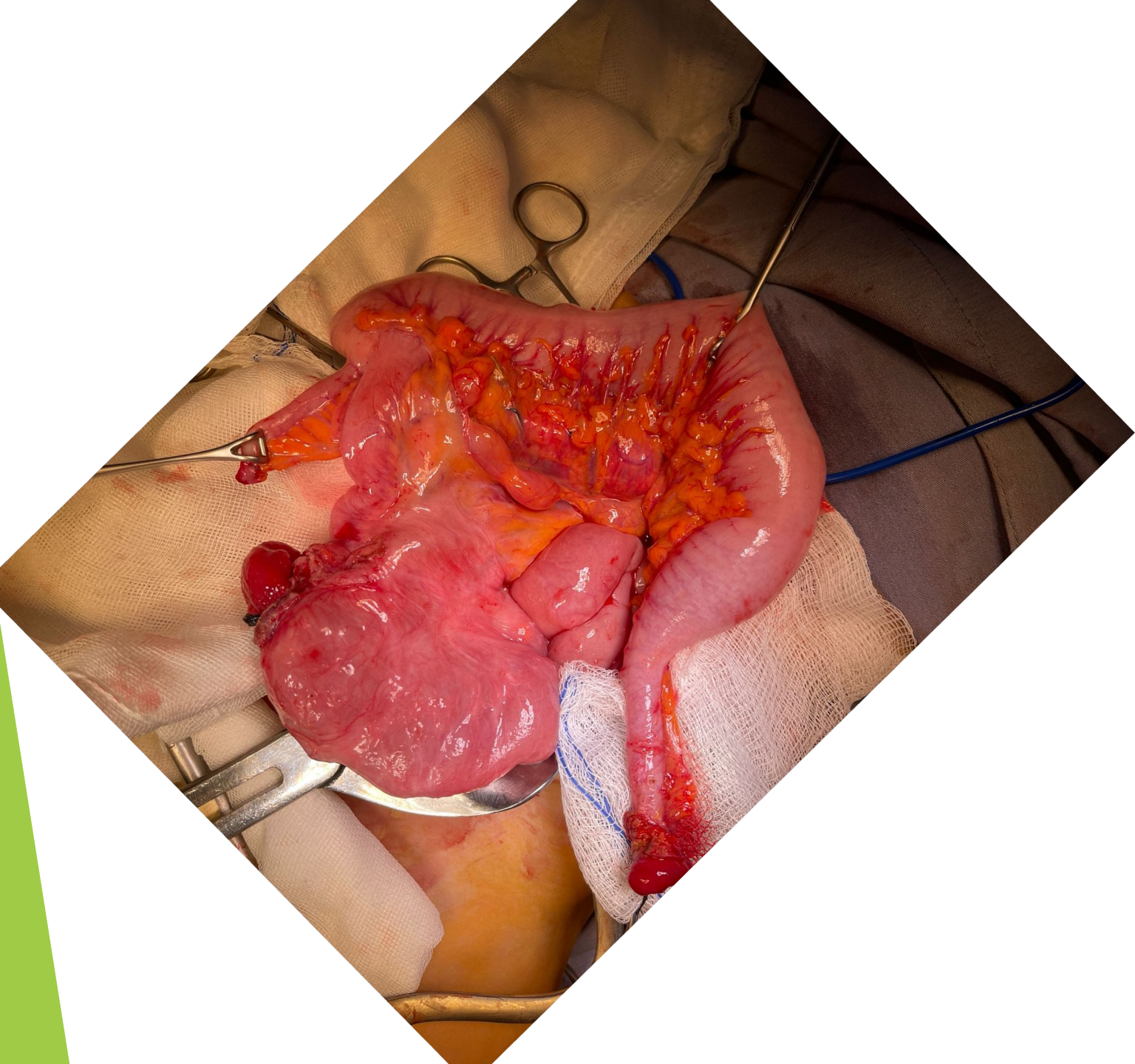
-



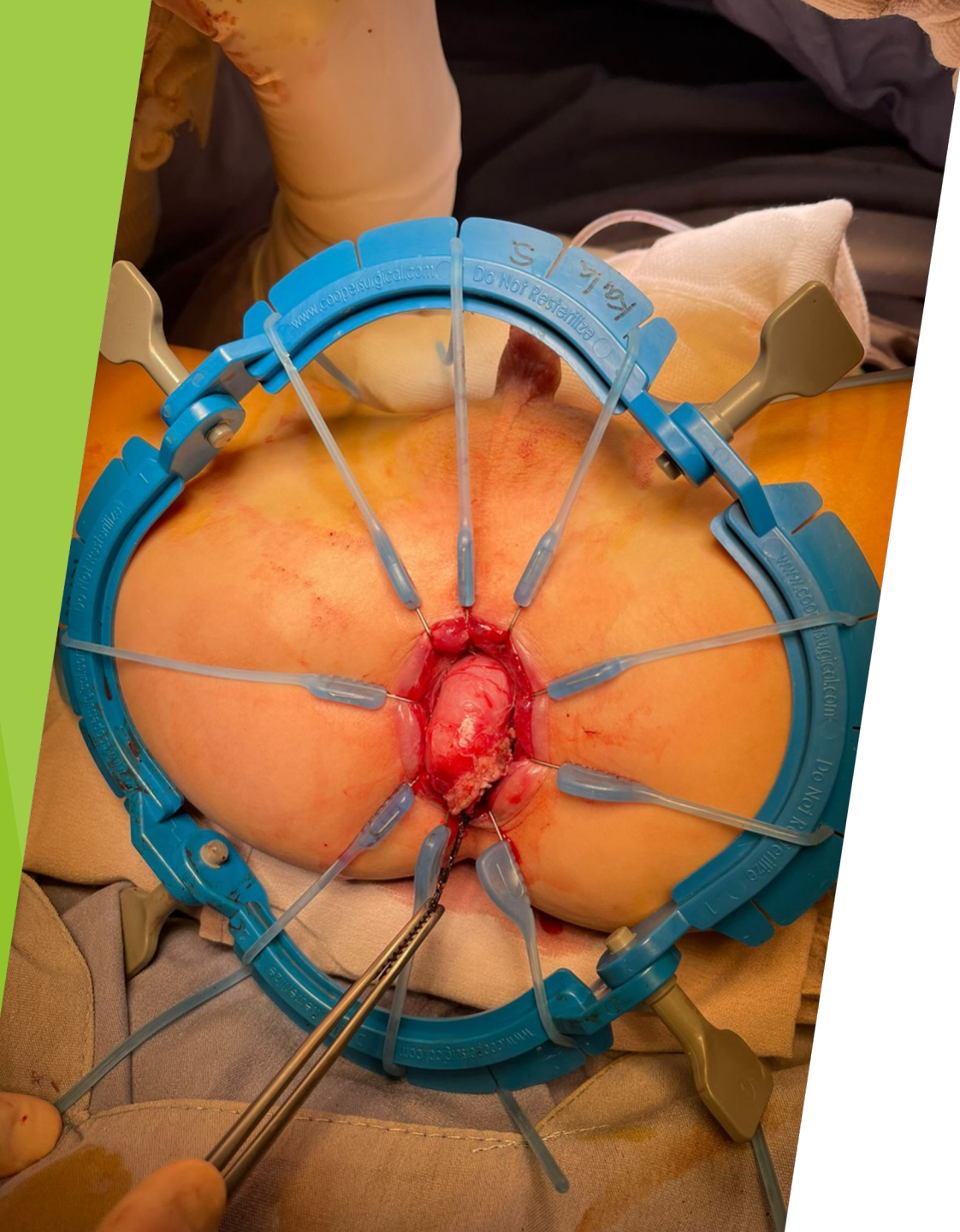Protectomy



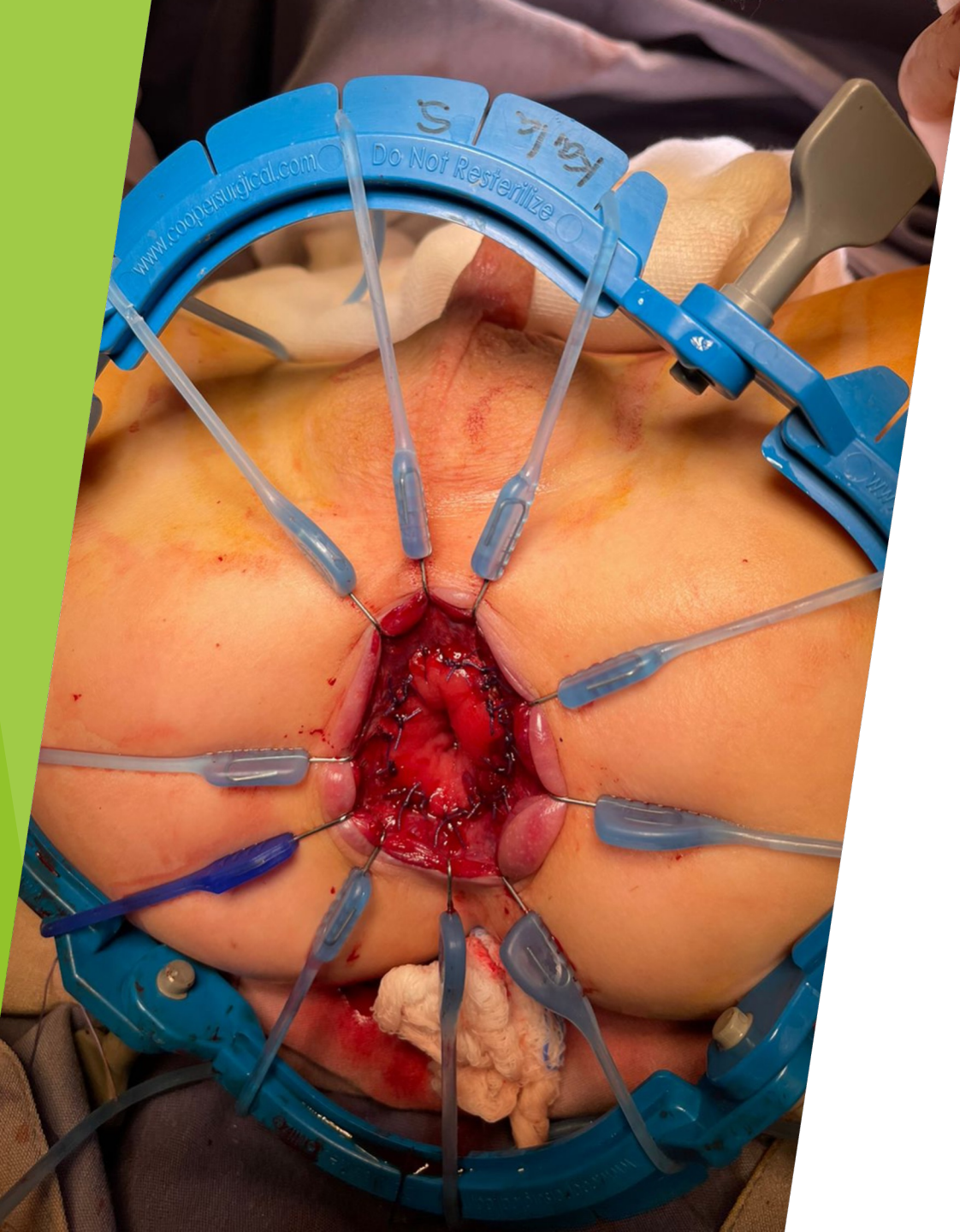Abdominal approach



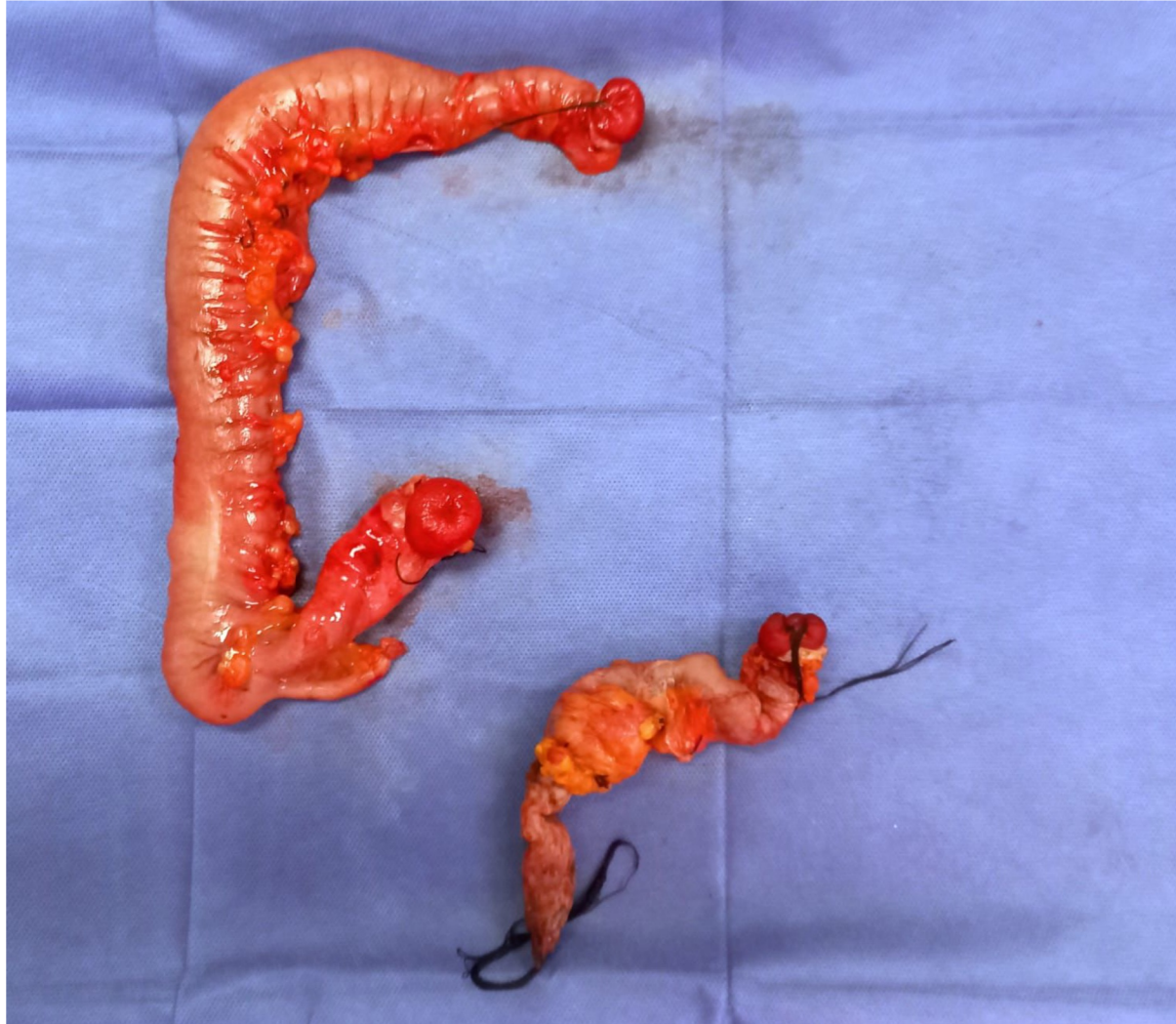► Surgical biopsy of a segment of the appendix



ILEAL PULL-THROUGH



ILEO-RECTAL ANASTOMOSIS



THANK
YOU! 🙏