

Case # 4 and # 5

Andrea Bischoff, M.D.

May 23rd, 2024



Children's Hospital Colorado

INTERNATIONAL CENTER FOR
**COLORECTAL AND
UROGENITAL CARE**



10 months old non-identical twin boys

On a fever work up, one twin was found to have a presacral mass and when the other twin underwent screening, he was also found to have a presacral mass

Family history: mother with history of malignant sacrococcygeal teratoma that was excised and required chemotherapy



Do you think we should get Alpha-feto protein and B-HCG for them?

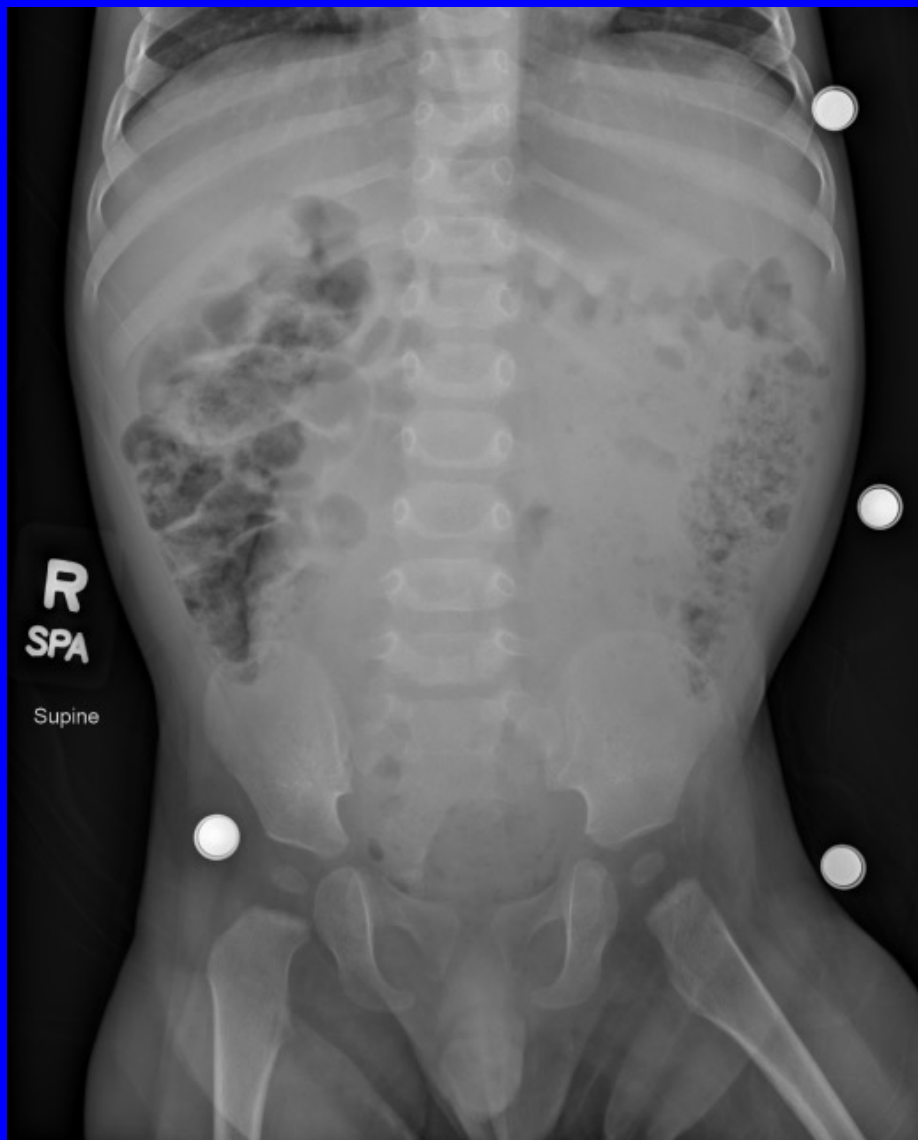1. Yes

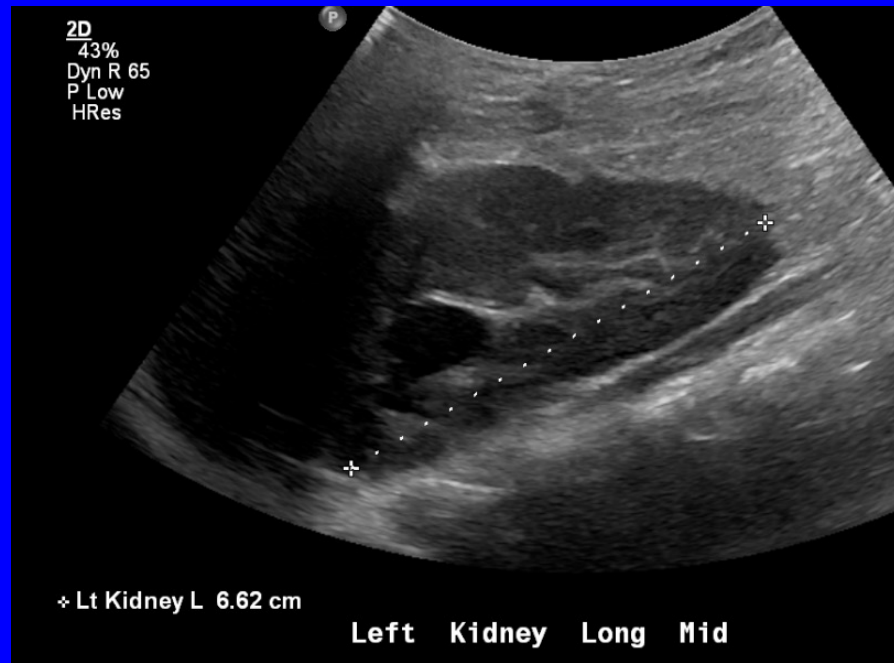
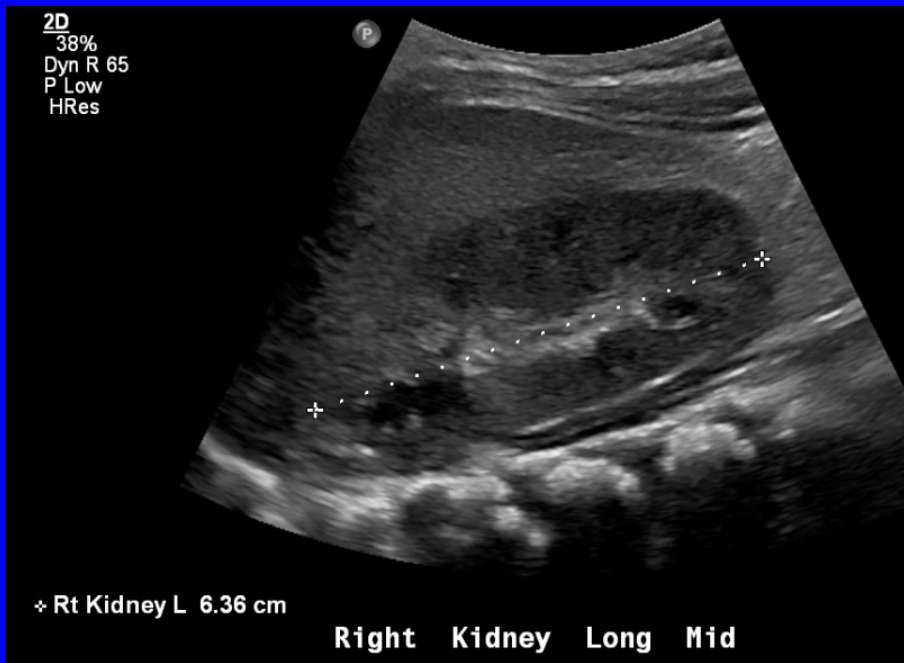
2. No

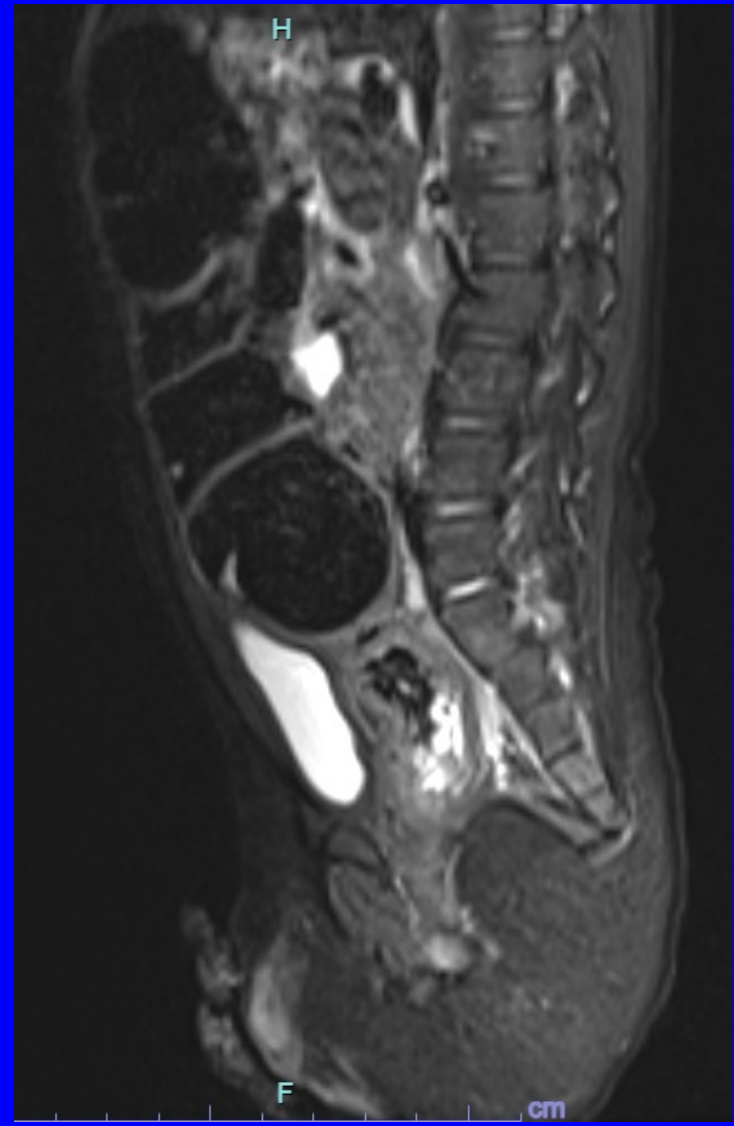
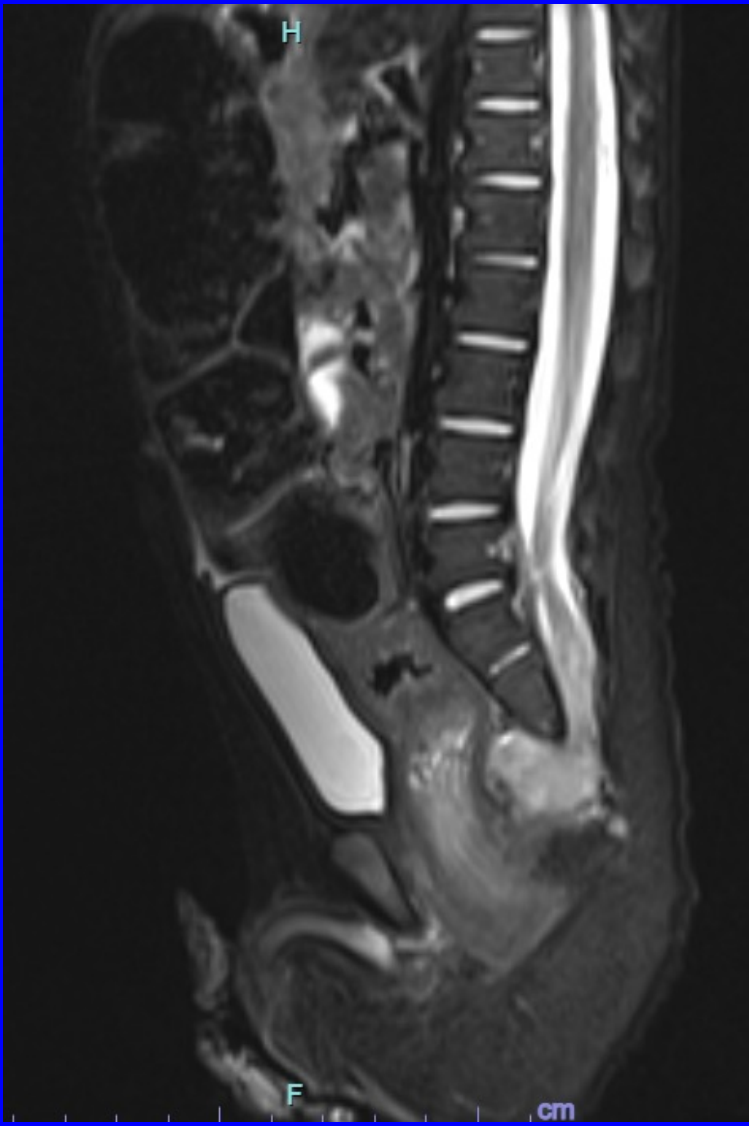

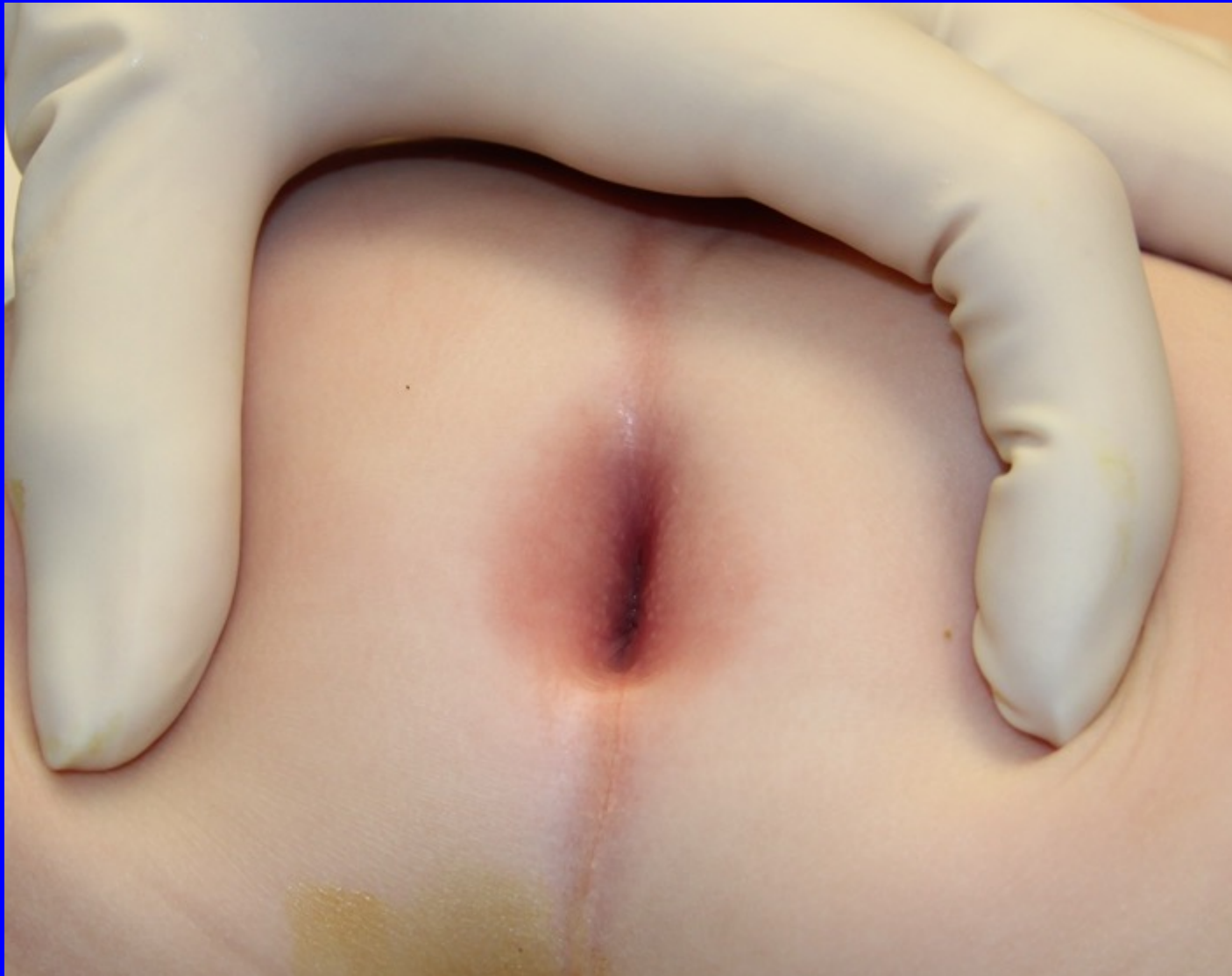Due to family history, we got for both
and they were normal.

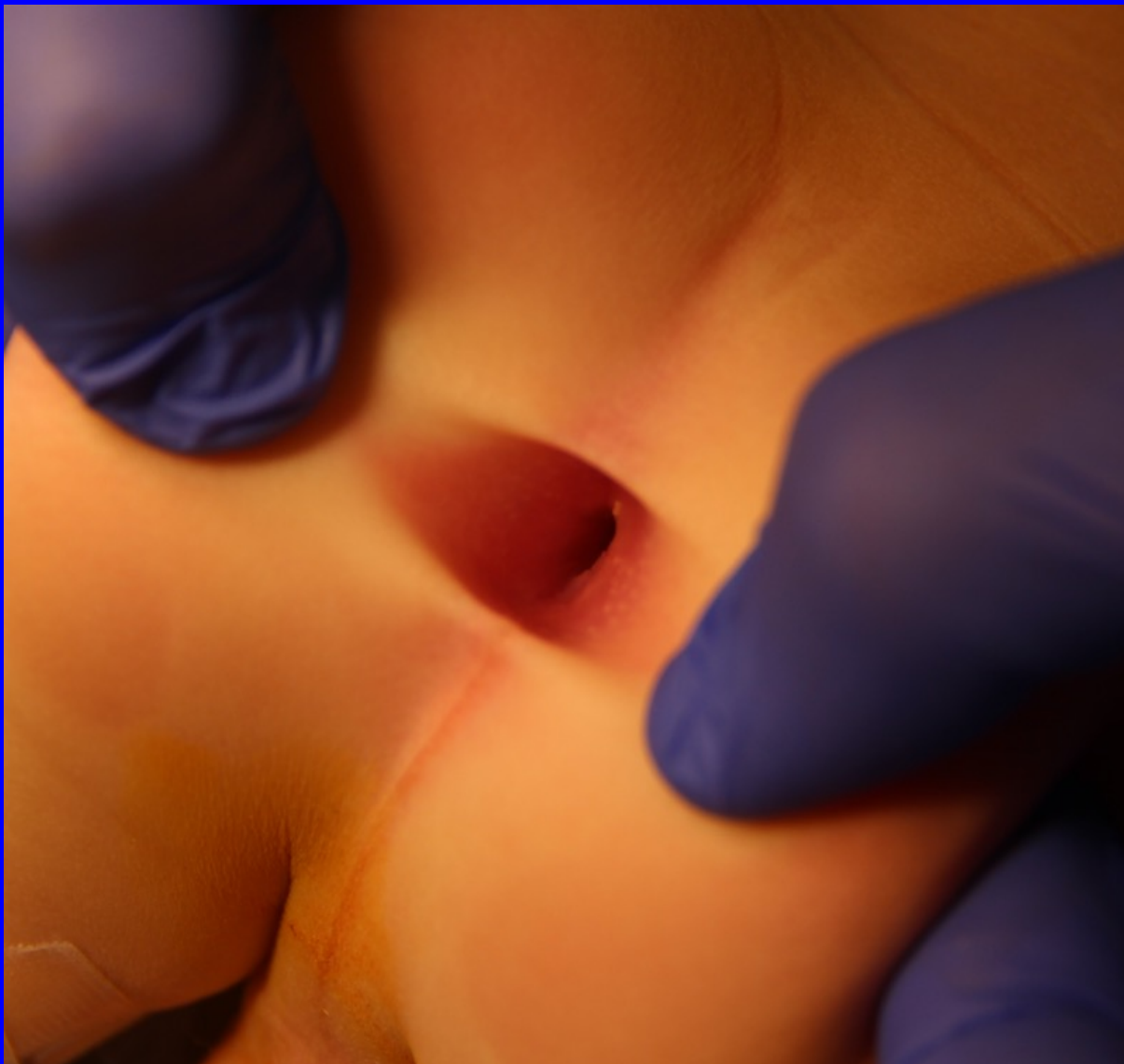Twin 1





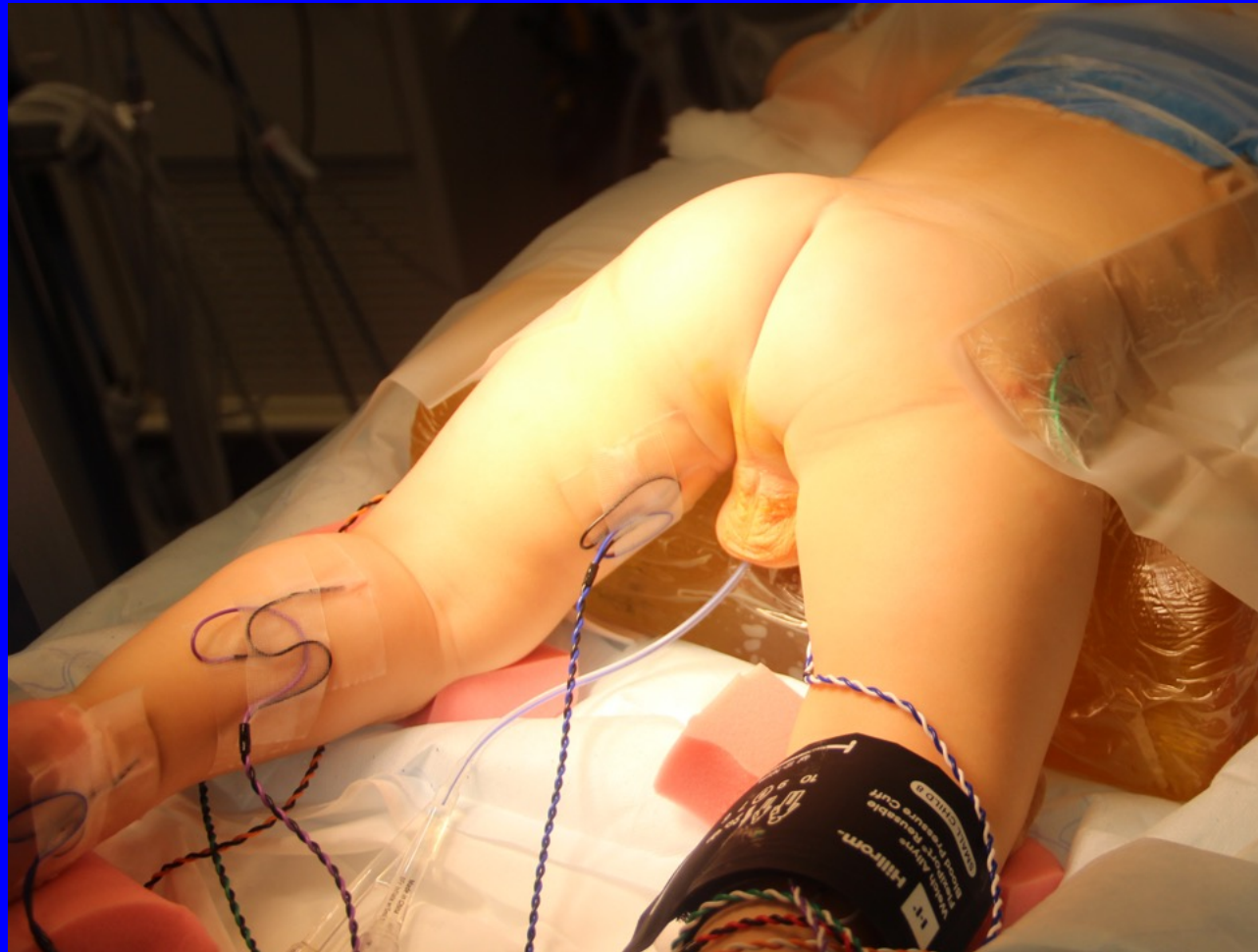

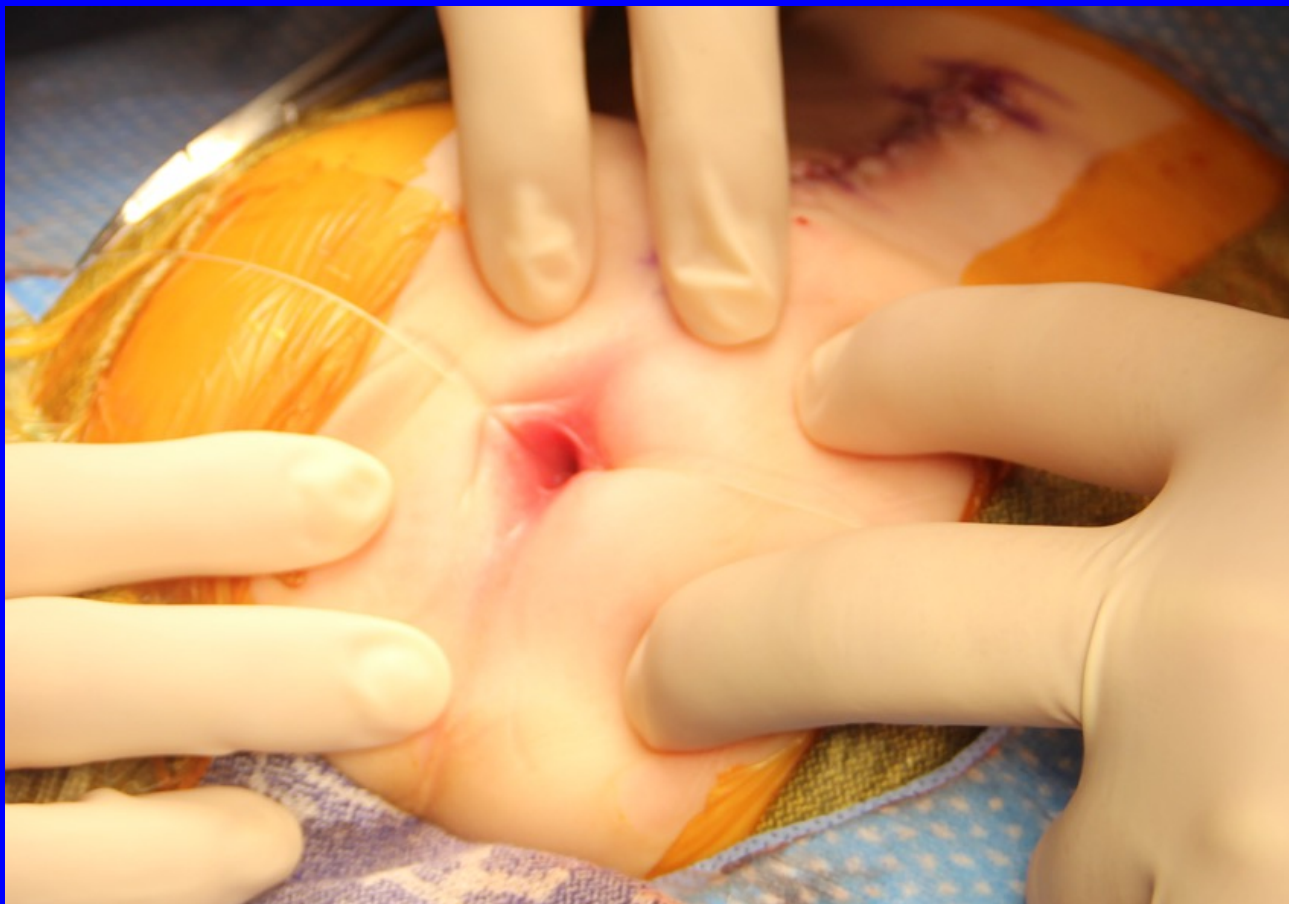




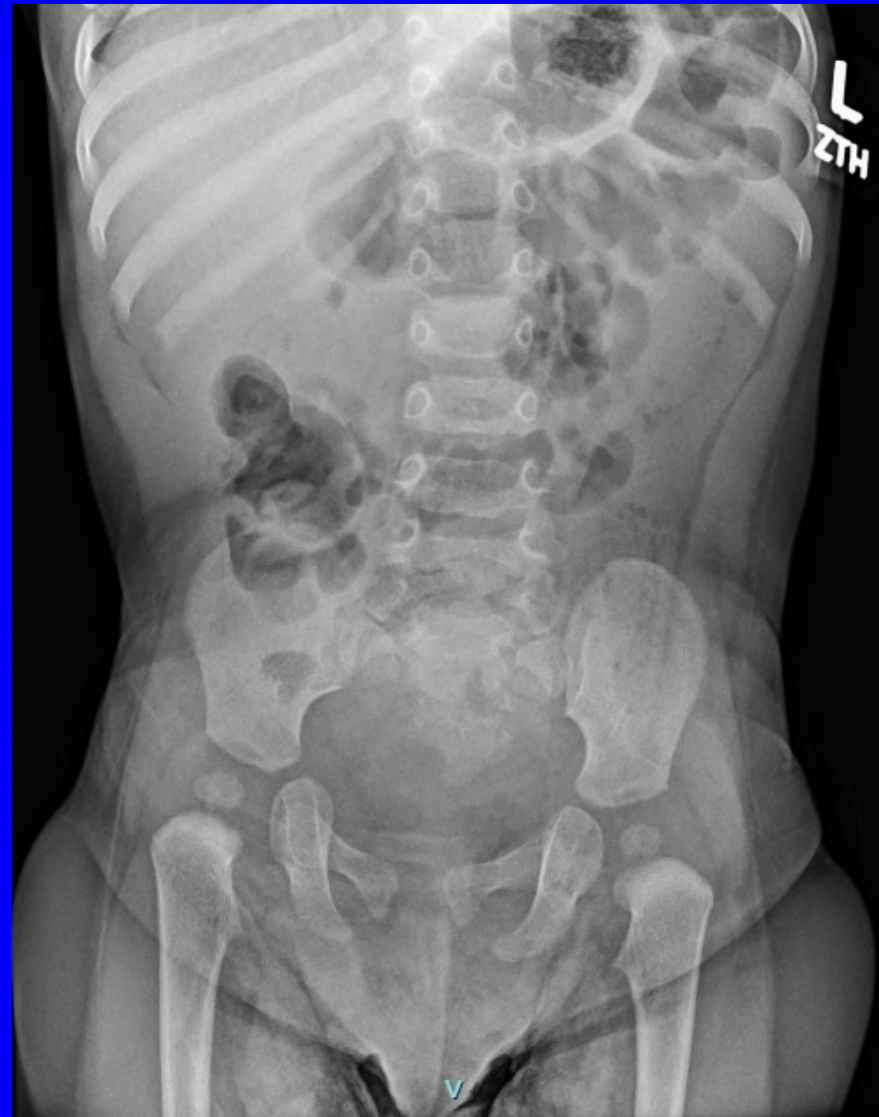INTERNATIONAL CENTER FOR
**COLORECTAL AND
UROGENITAL CARE**

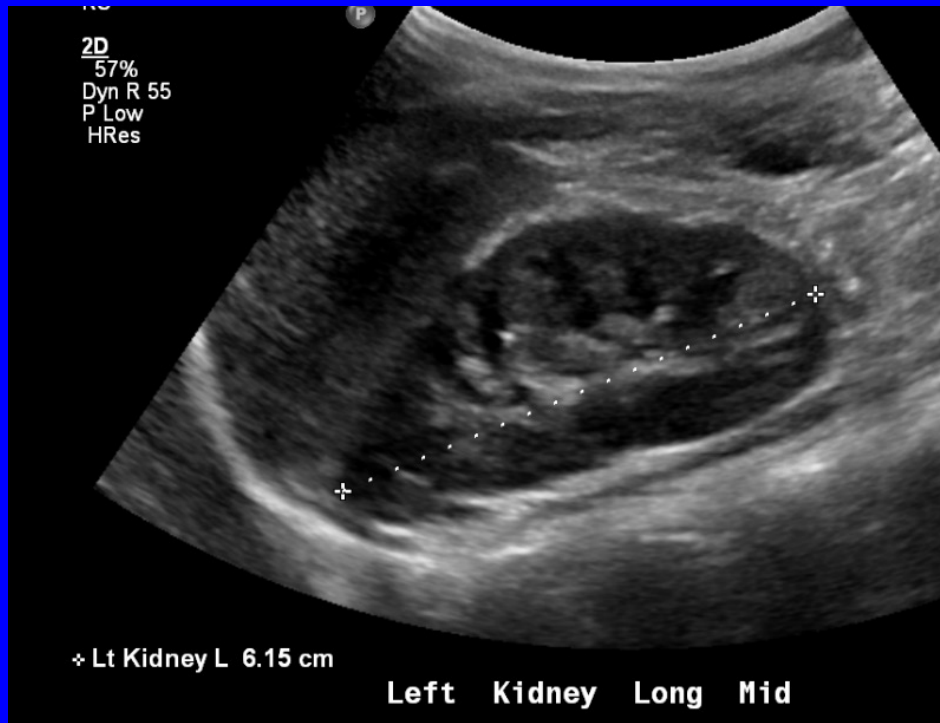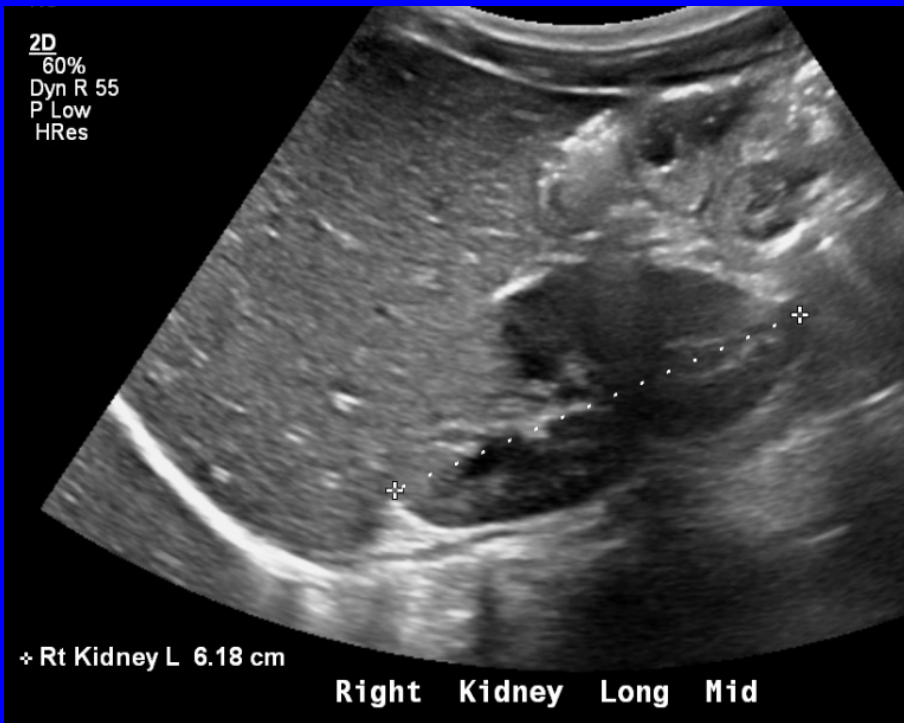Neuromonitoring

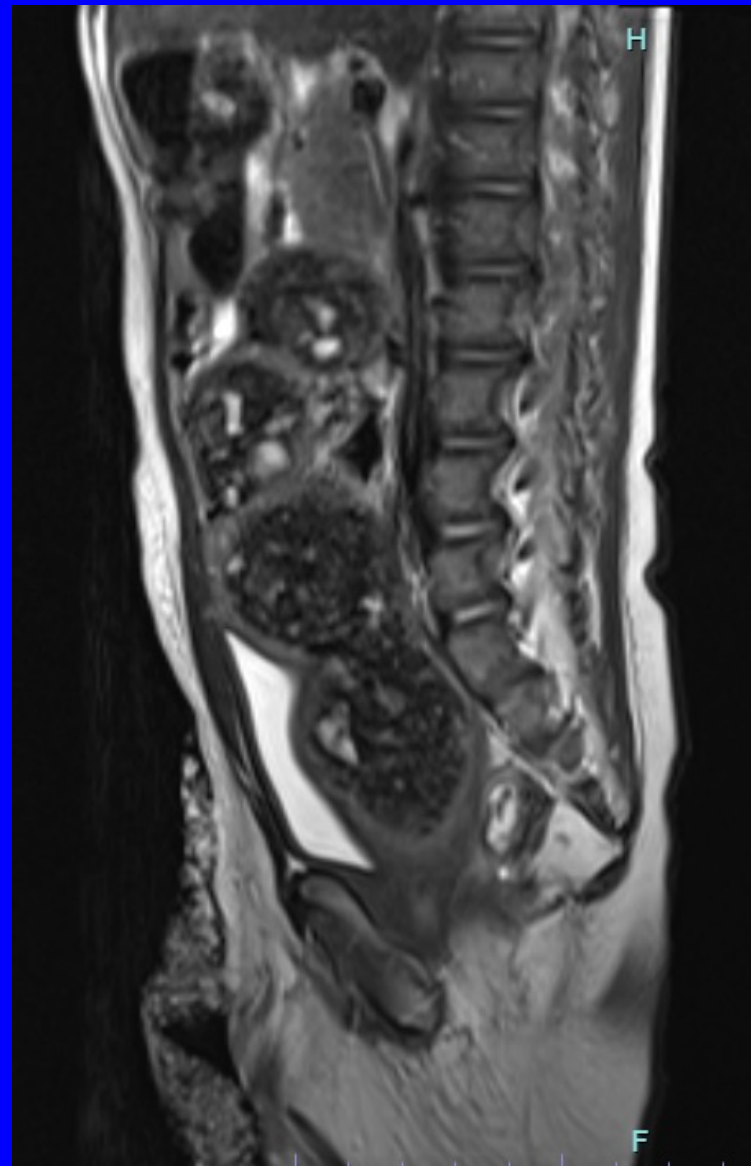
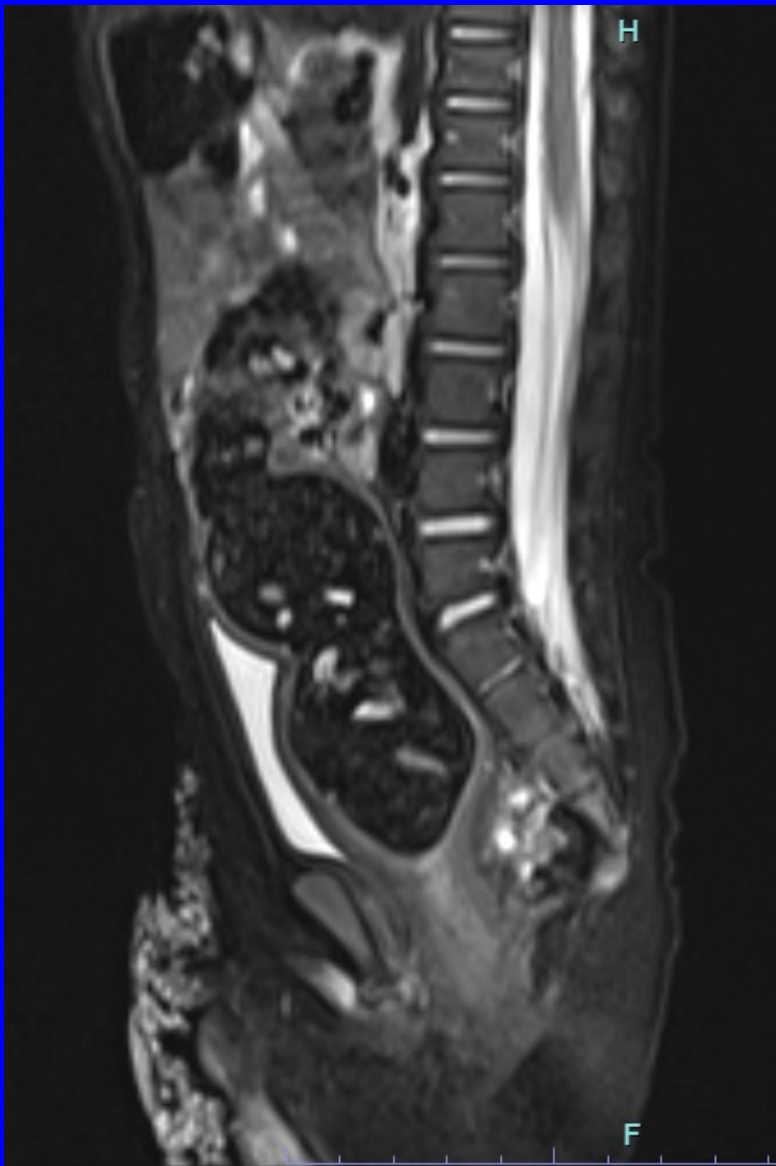


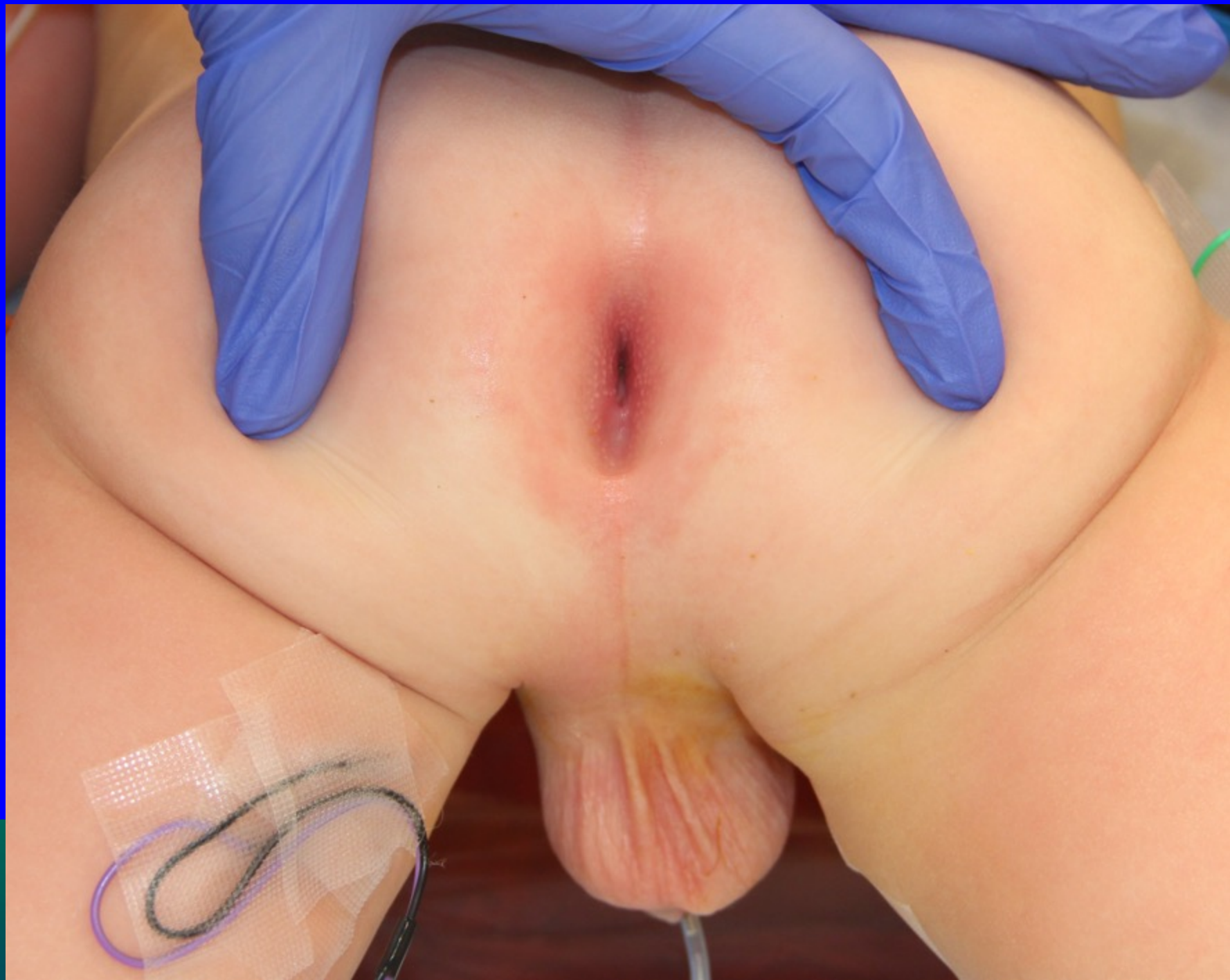

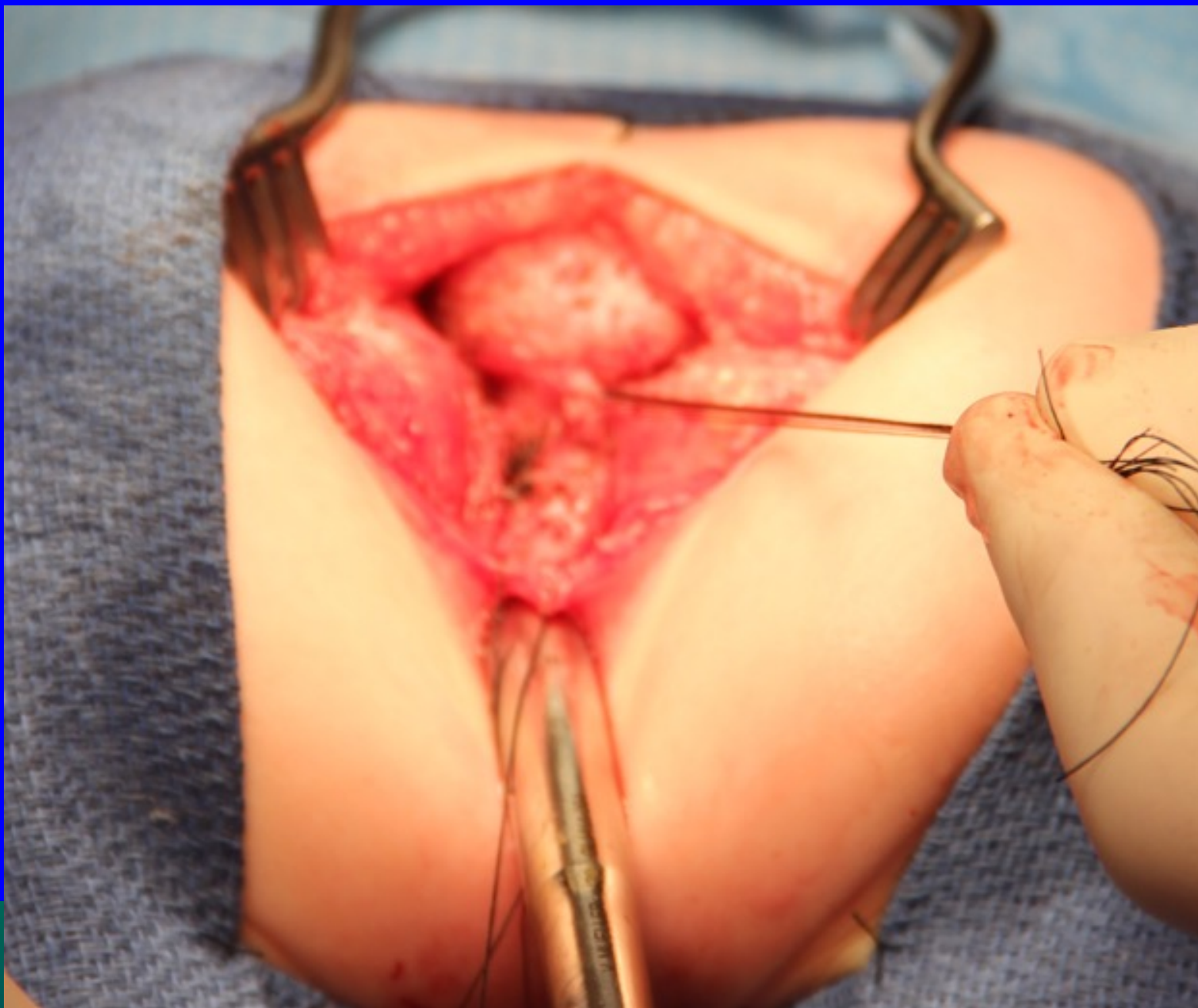
Twin 2



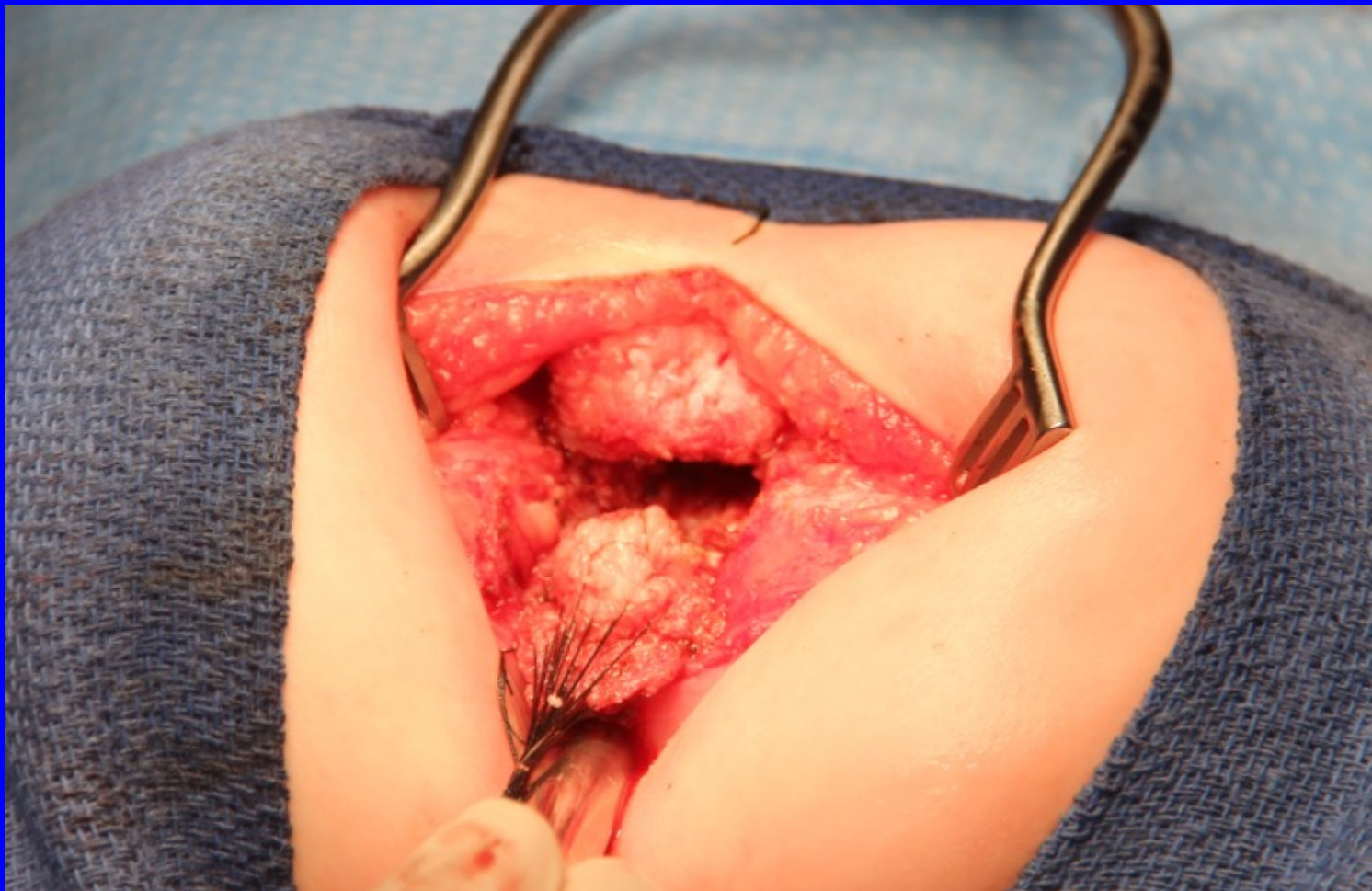



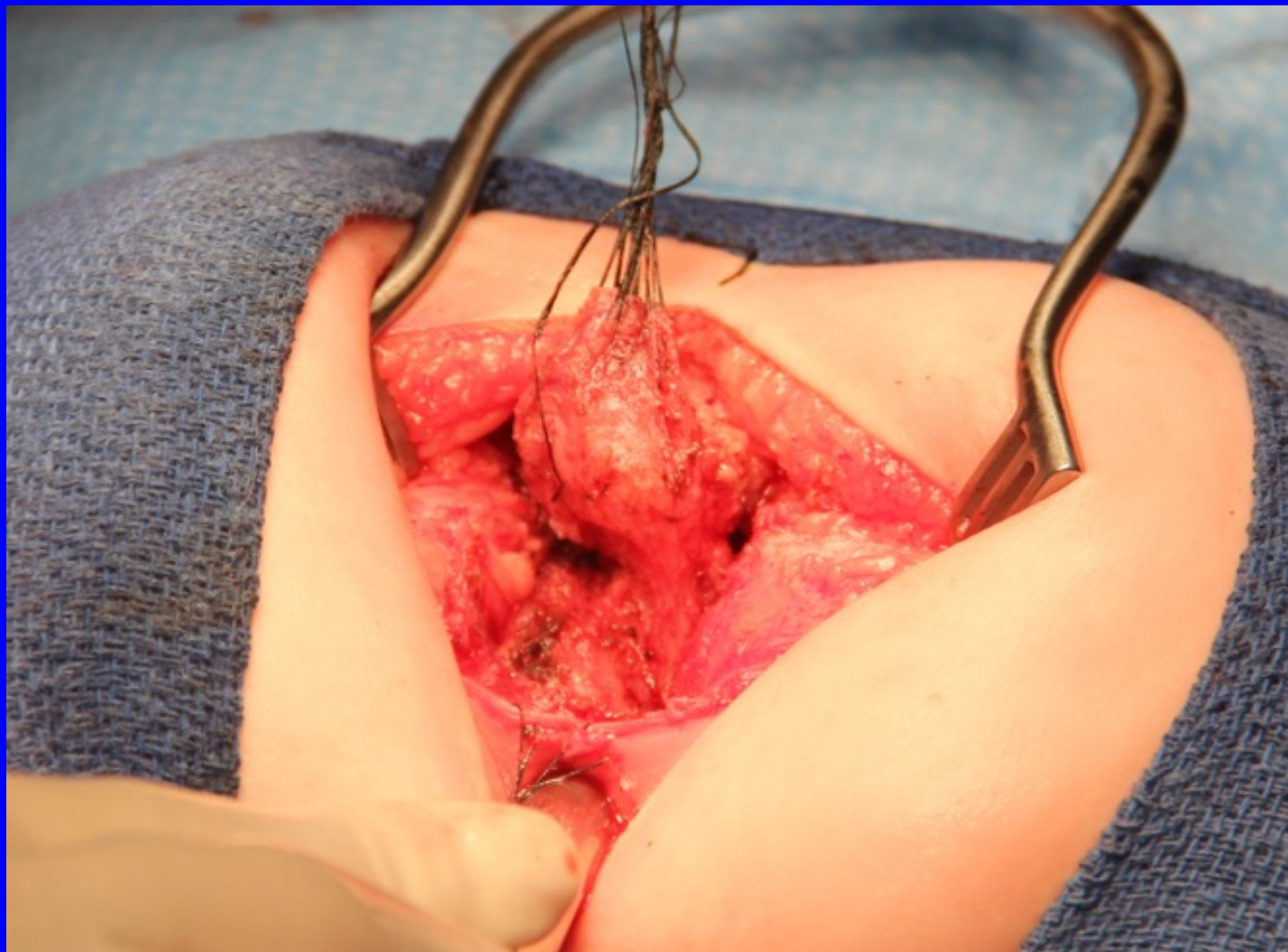




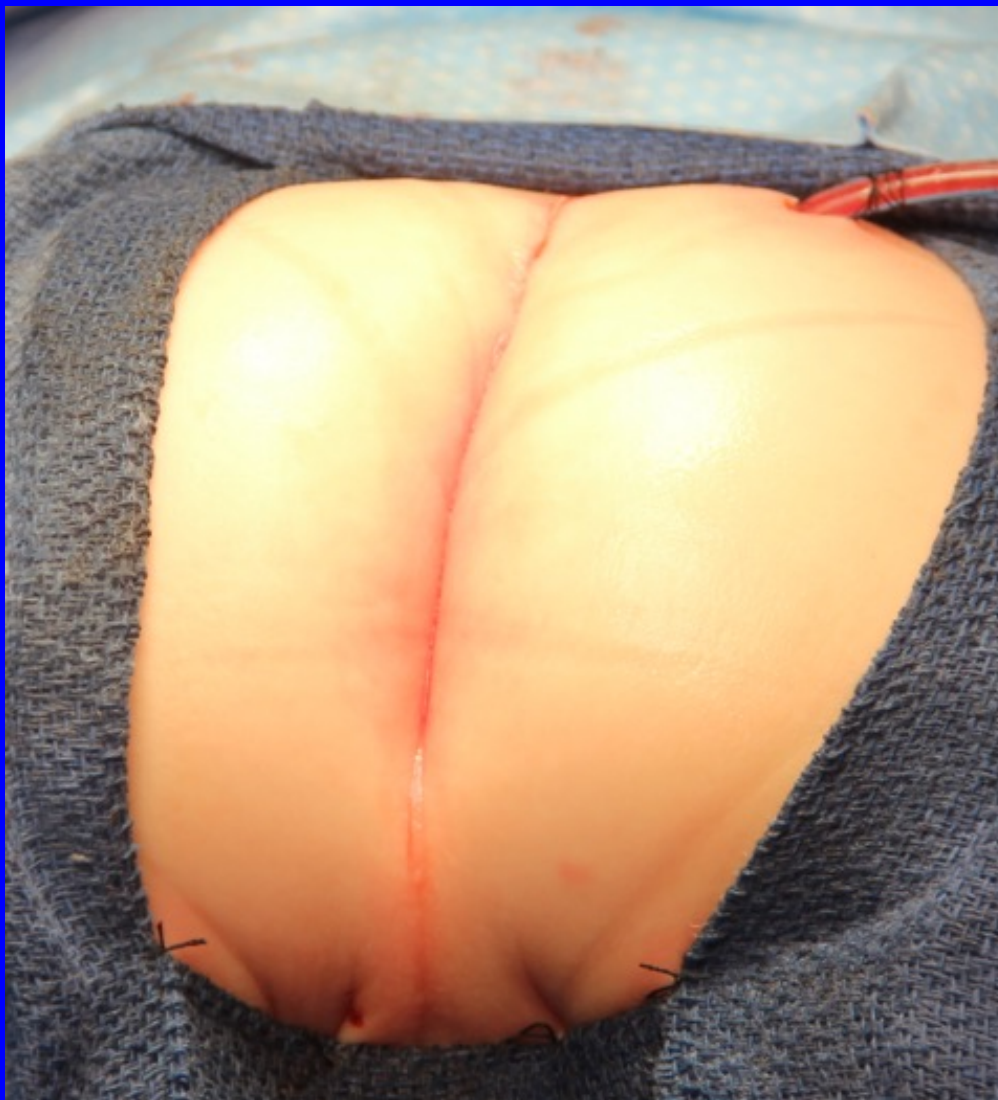FOR
AND
UROGENITAL CARE



INTERNATIONAL CENTER FOR
**COLORECTAL AND
UROGENITAL CARE**



INTERNATIONAL CENTER FOR
**COLORECTAL AND
UROGENITAL CARE**





Hystopathology

- Twin 1: benign cystic teratoma (intra-dural)
- Twin 2: benign cystic teratoma



Do both twins have the same prognosis for bowel and bladder control?

1. Yes

2. No

Thank You



INTERNATIONAL CENTER FOR
**COLORECTAL AND
UROGENITAL CARE**