


CLINICAL CASE



INTERNATIONAL COLORECTAL WEB MEETING

ELIANE HEFTYE SANCHEZ MD

COLORECTAL SURGERY RESIDENT FELLOW

KARLA SANTOS JASSO MD

CHIEF OF DEPARTMENT



MEDICAL RECORDS

Male, 3 years and 4 months old

DSD (46XY) (Male gender assignment)

Complex anorectal malformation

Cardiogenital syndrome

Scrotal Hypospadias

Bilateral cryptorchidism

Gonadal dysgenesis (Müllerian persistence and partial response to the reserve test)

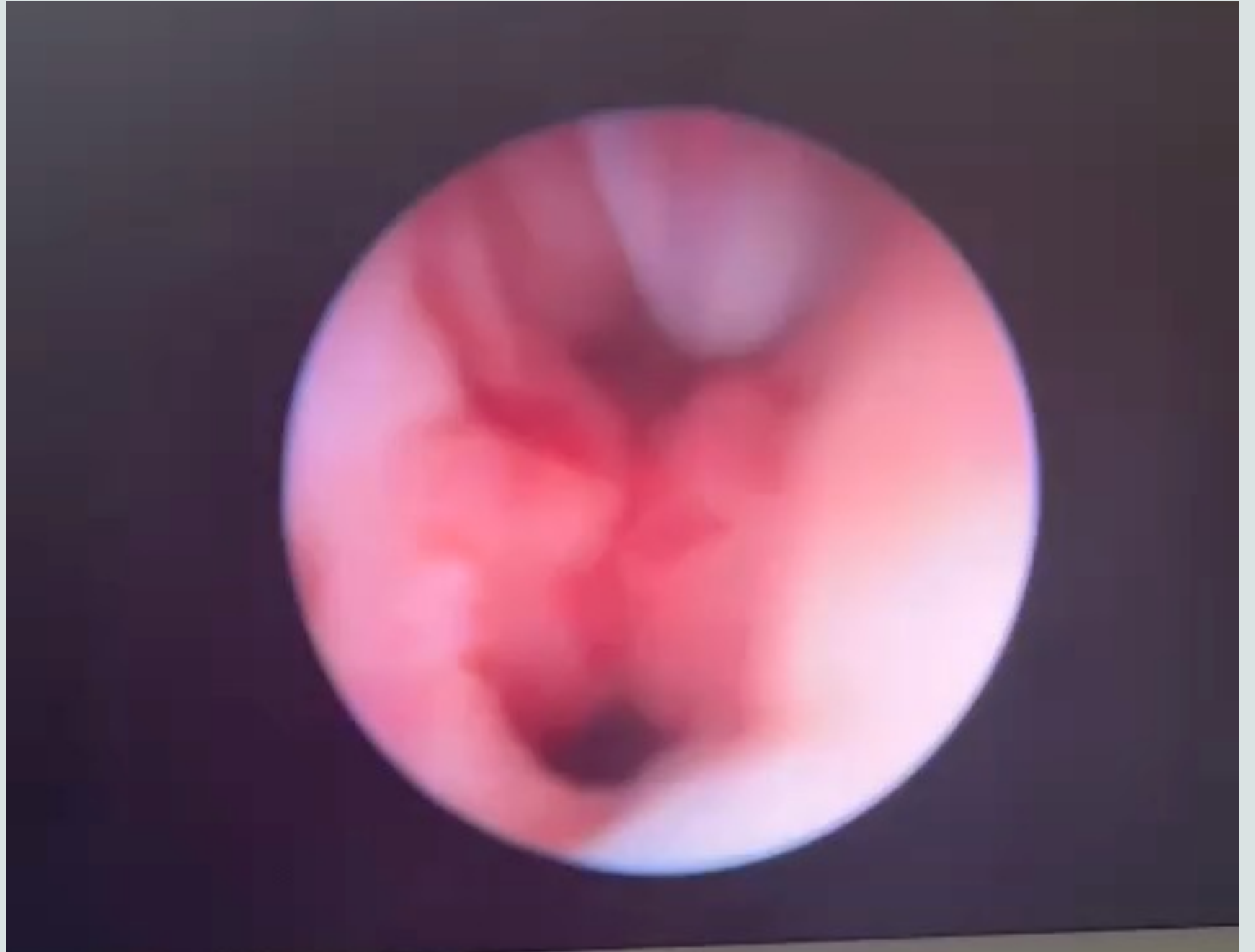SURGICAL PROCEDURES

COLOSTOMY
(2020)

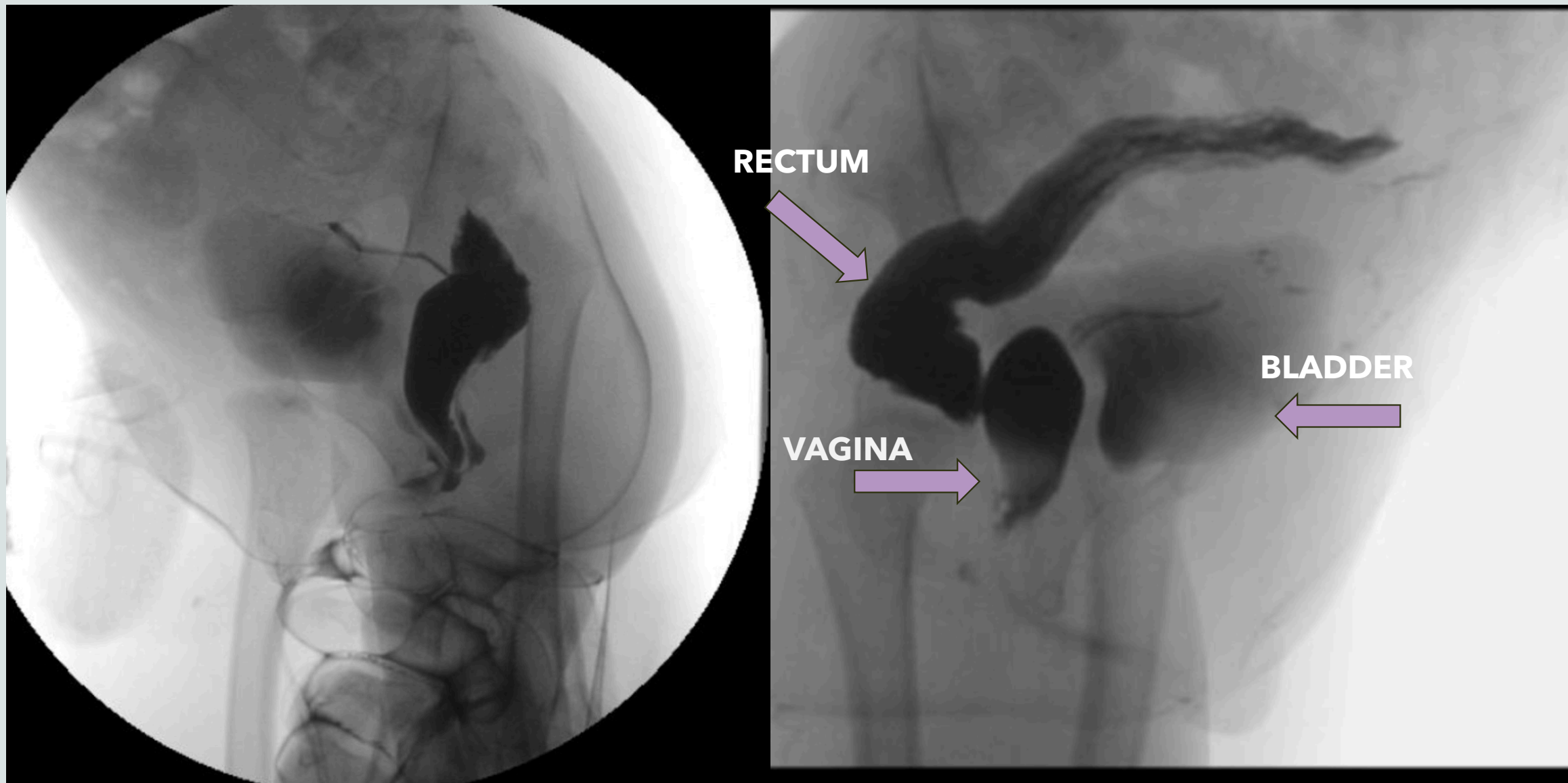
DIAGNOSTIC
LAPAROSCOPY
+
CYSTOSCOPY
(2023)

- **FINDINGS:** 2cm common channel, posterior rectum (0.5cm from orifice), anteriorly observed VAGINA with 12mm length with a single cervix. Bladder neck with 1cm length.
- Right inguinal canal (gonad and presence of fimbria, tubular structure and right hemiuterus).

CYSTOSCOPY



CONTRAST STUDY



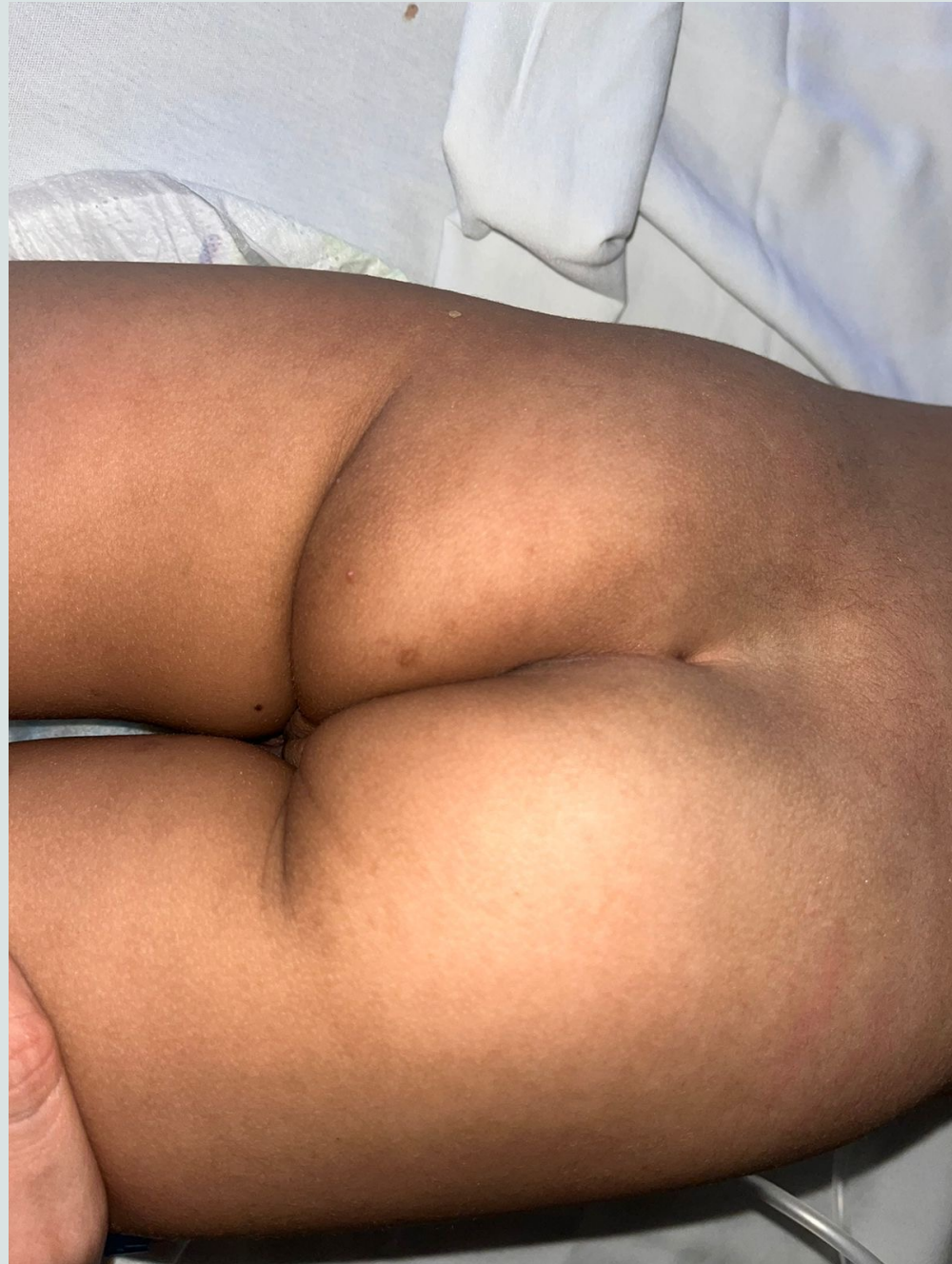
SURGICAL PLAN

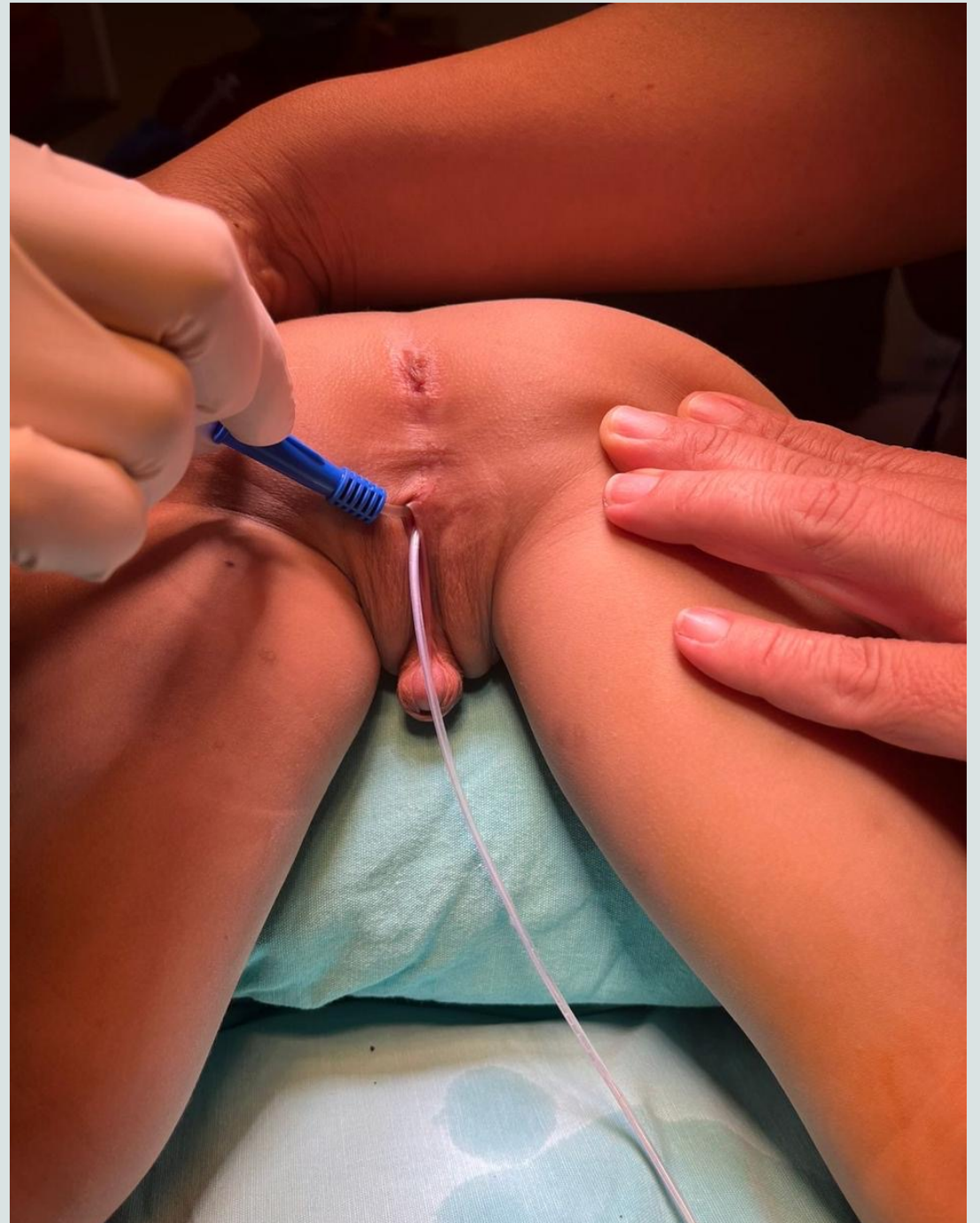
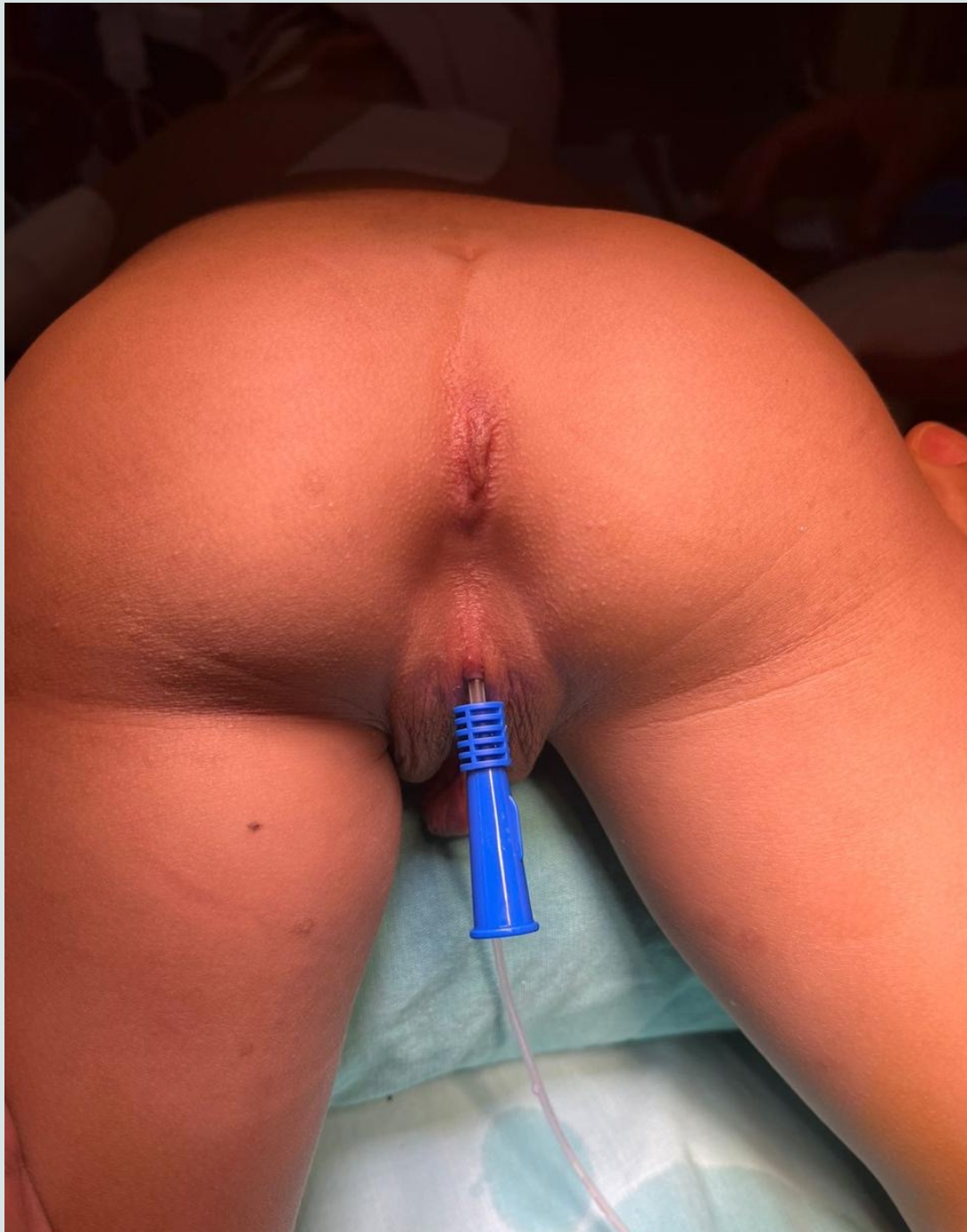
Case discussion with the
Urology department.

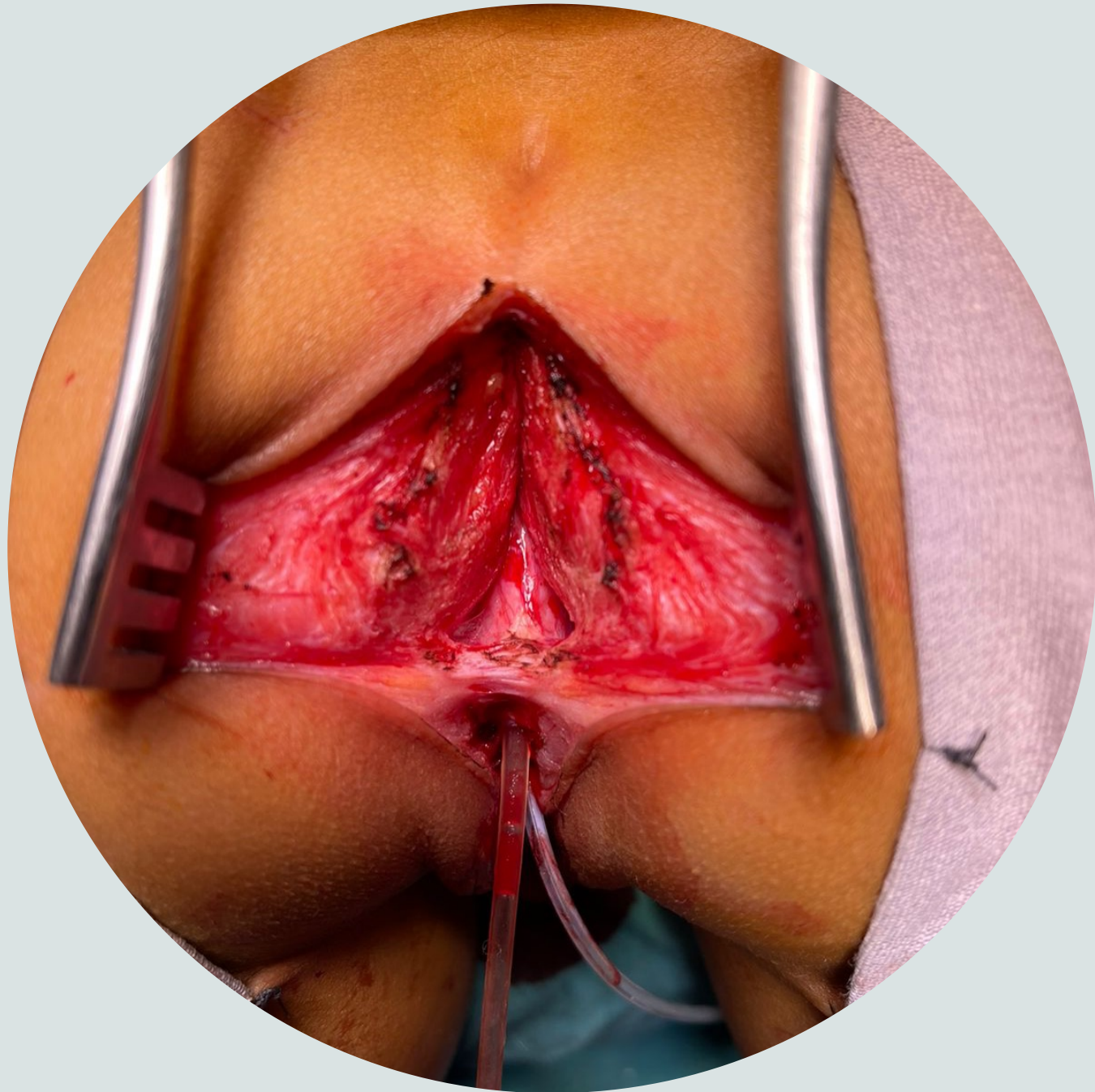
**Urology: Laparoscopic
resection of Müllerian
remnants**

- Preoperative cystoscopy and placement of transurethral catheter.

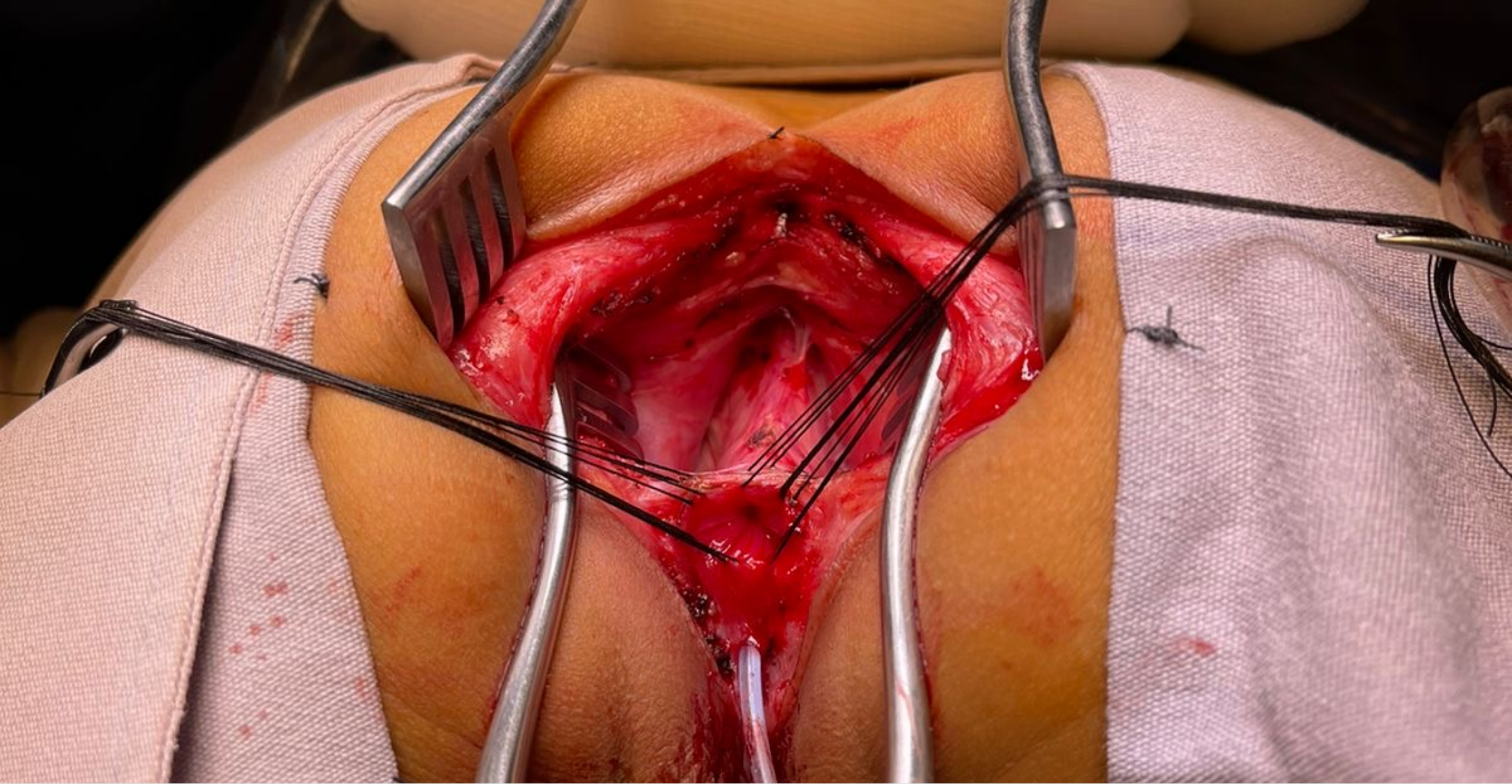**Colorectal: Reconstruction
and posterior sagittal
anorectoplasty**

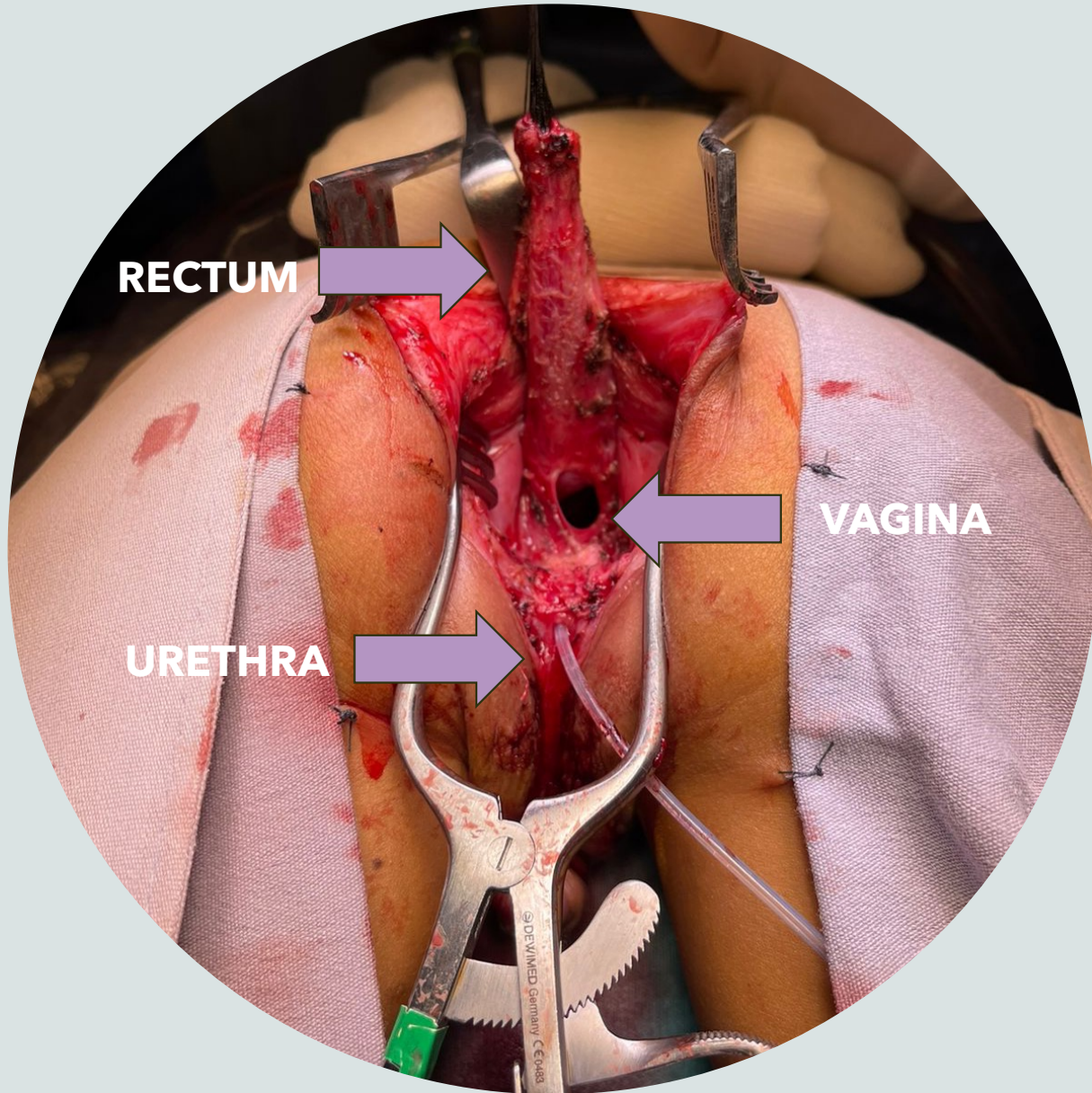







**CONVENTIONAL
POSTERIOR SAGITTAL
+ IDENTIFICATION OF
THE RECTUM FASCIA**





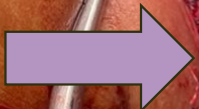
RECTUM



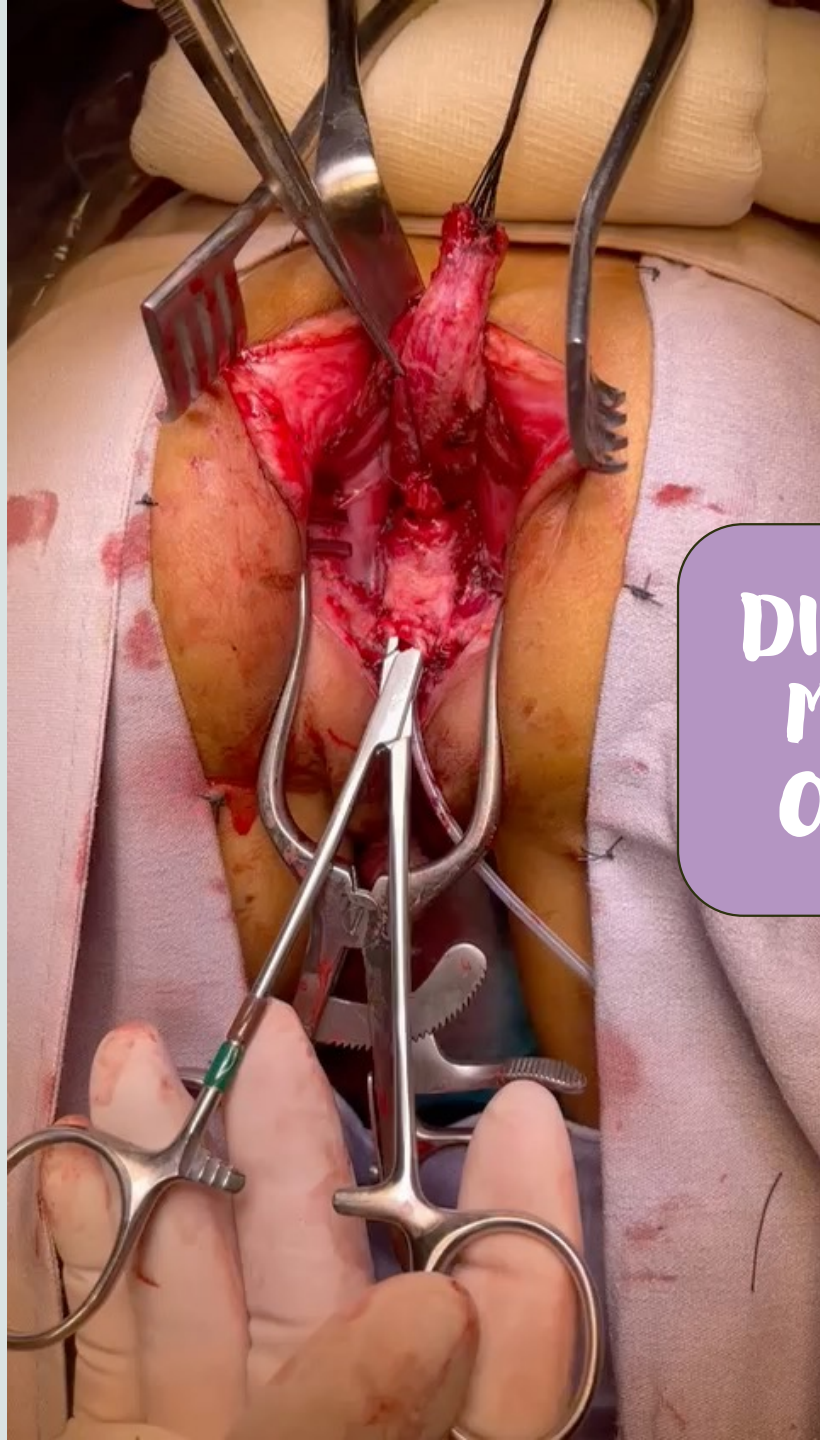VAGINA



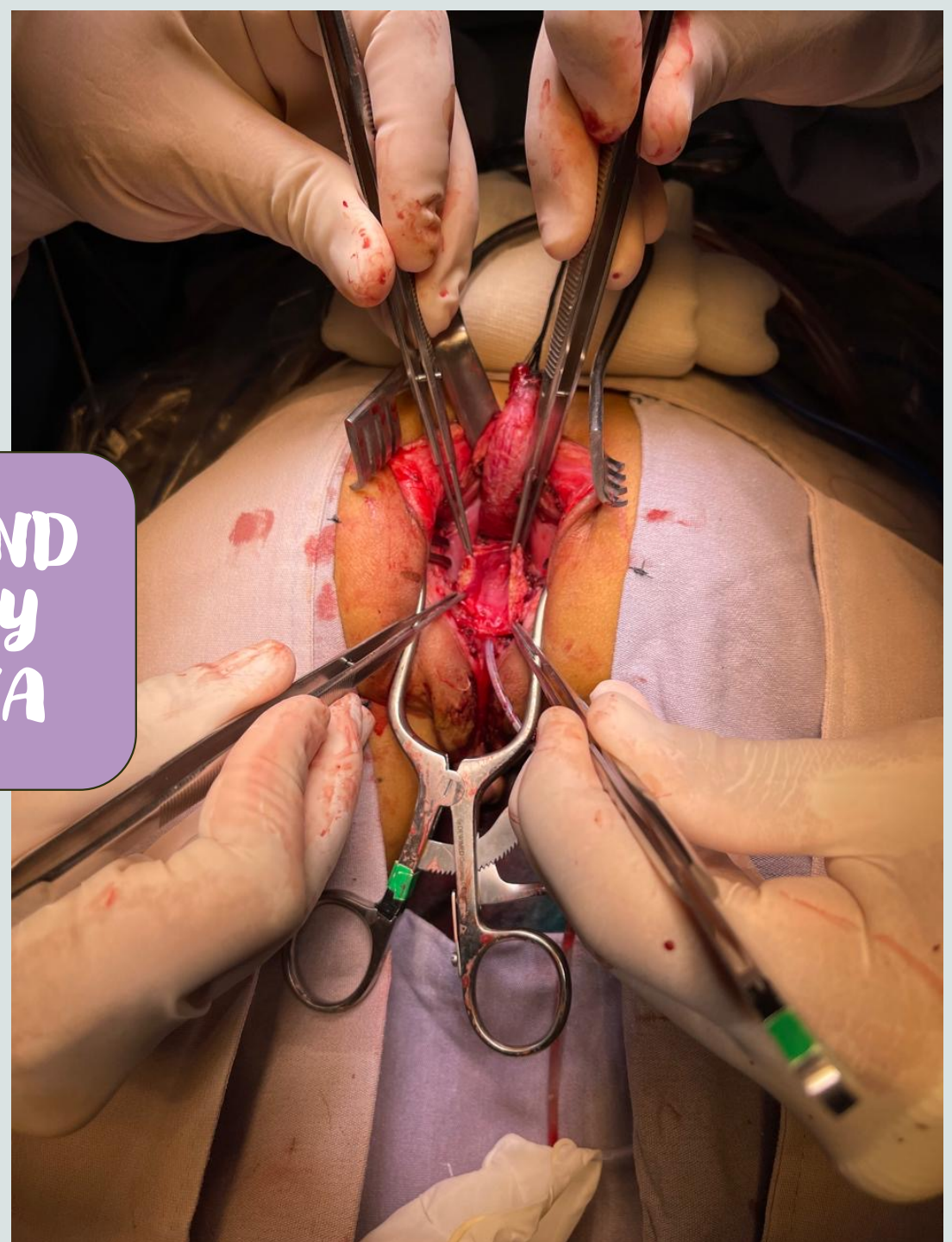
URETHRA

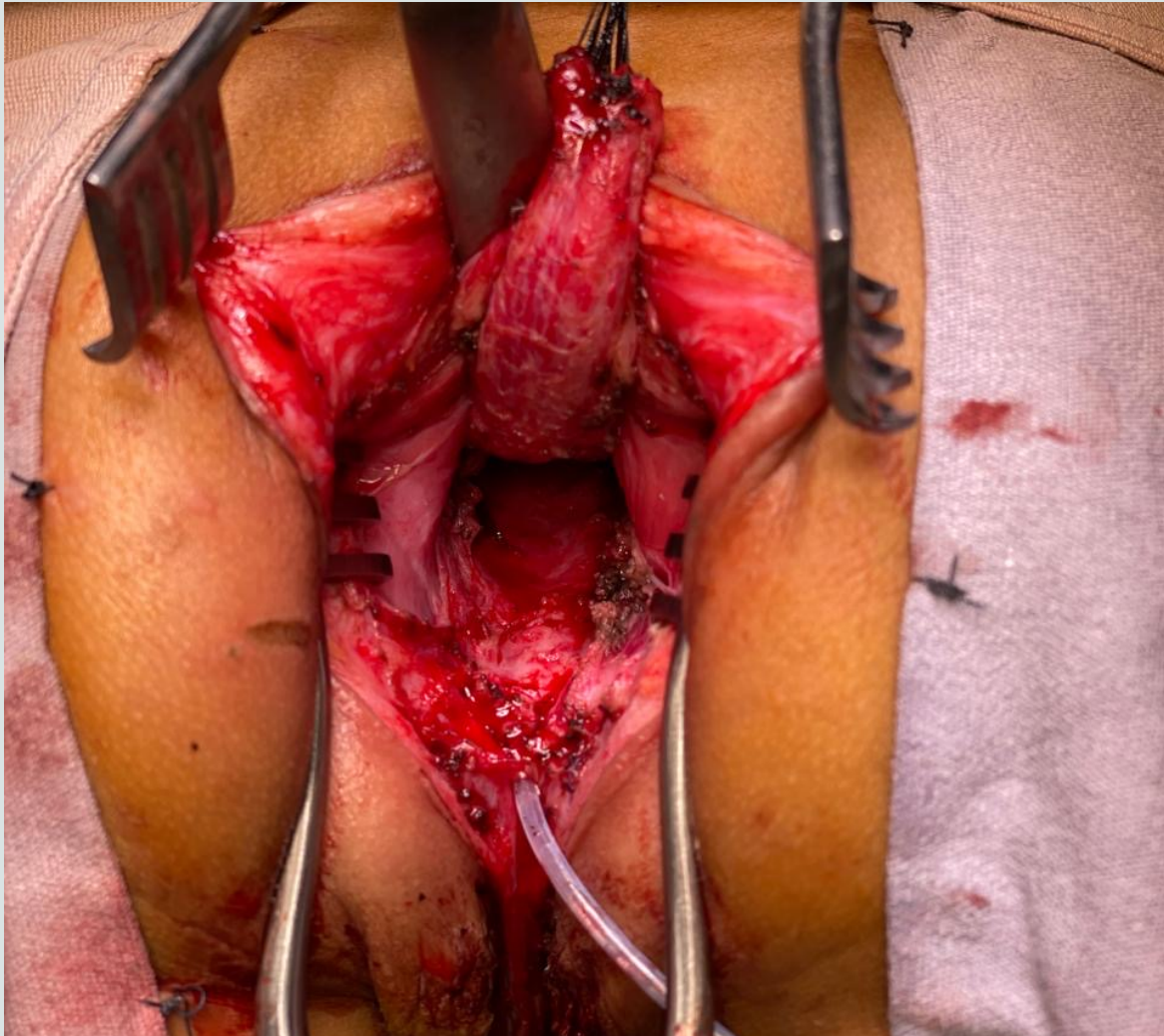


**DISSECTION OF THE
RECTUM (ANTERIOR,
POSTERIOR AND
LATERAL WALLS)**

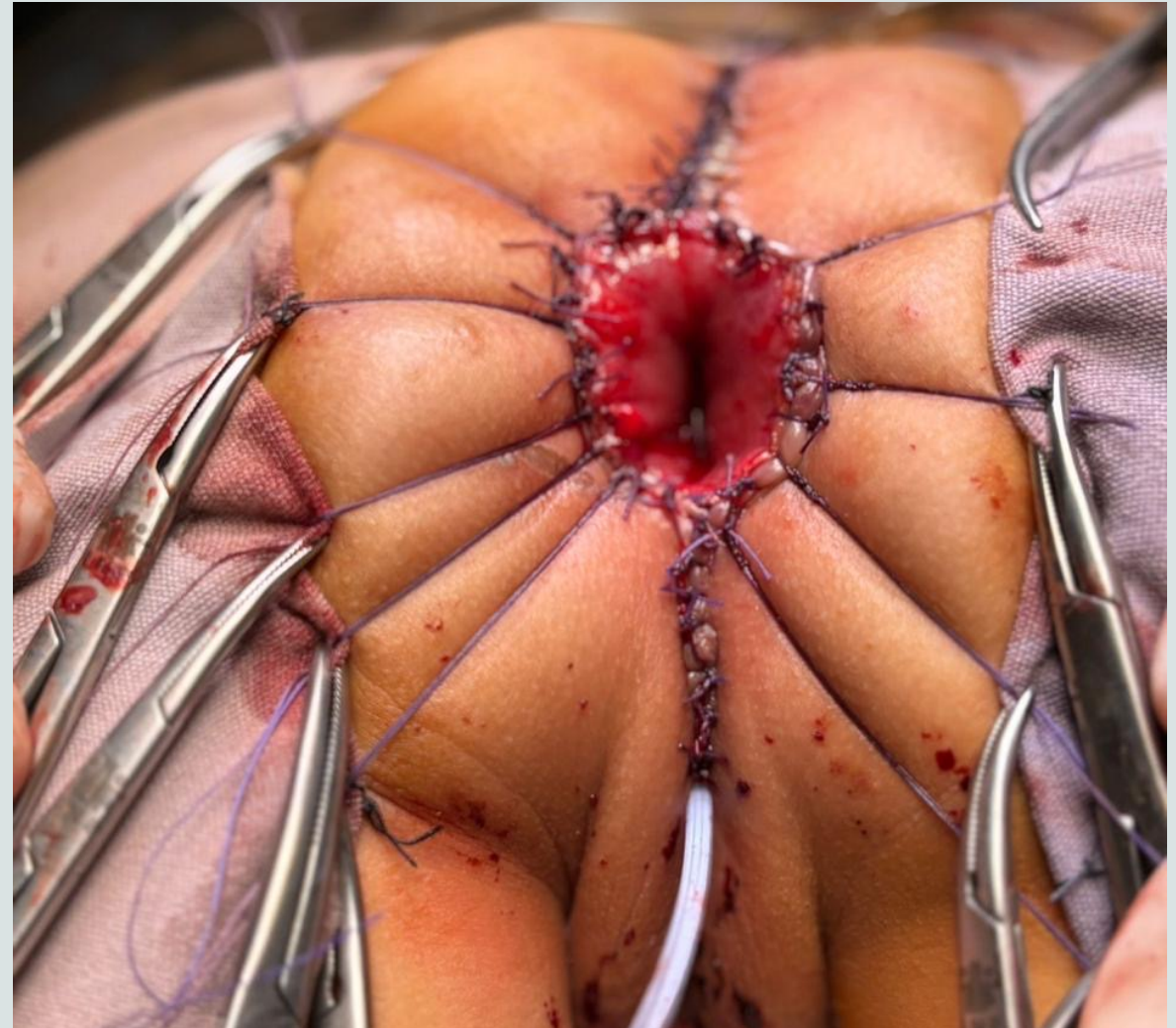


**DISSECTION AND
MUCOSECTOMY
OF THE VAGINA**





MUCOSECTOMY OF THE VAGINA



**PERINEAL RECONSTRUCTION,
POSTERIOR SAGITTAL AND ANOPLASTY**

• THANK YOU 😊