

# CLINICAL CASE



**INTERNATIONAL COLORECTAL  
WEB MEETING**

**ELIANE HEFTYE SANCHEZ MD**

COLORECTAL SURGERY RESIDENT  
FELLOW

**KARLA SANTOS JASSO MD**

CHIEF OF DEPARTMENT

# MEDICAL RECORDS

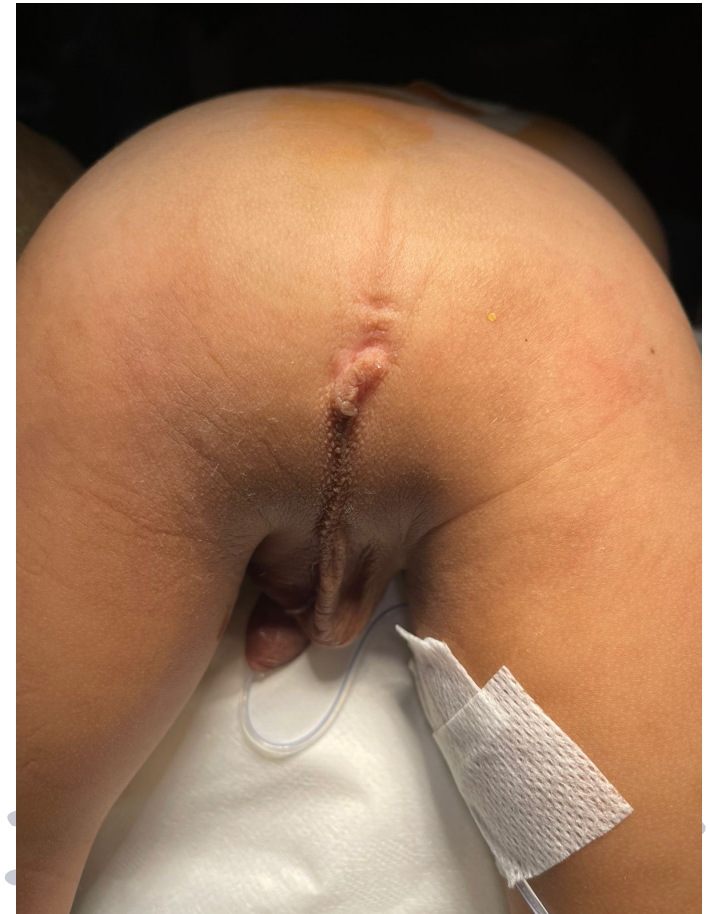Male, 1 year and 5 months old

## DIAGNOSIS:

- VACTERL Association
- Anorectal malformation with **recto-urethral fistula**
- (SCI: 0-70/RPI: 0.71)

## SURGICAL PROCEDURES:

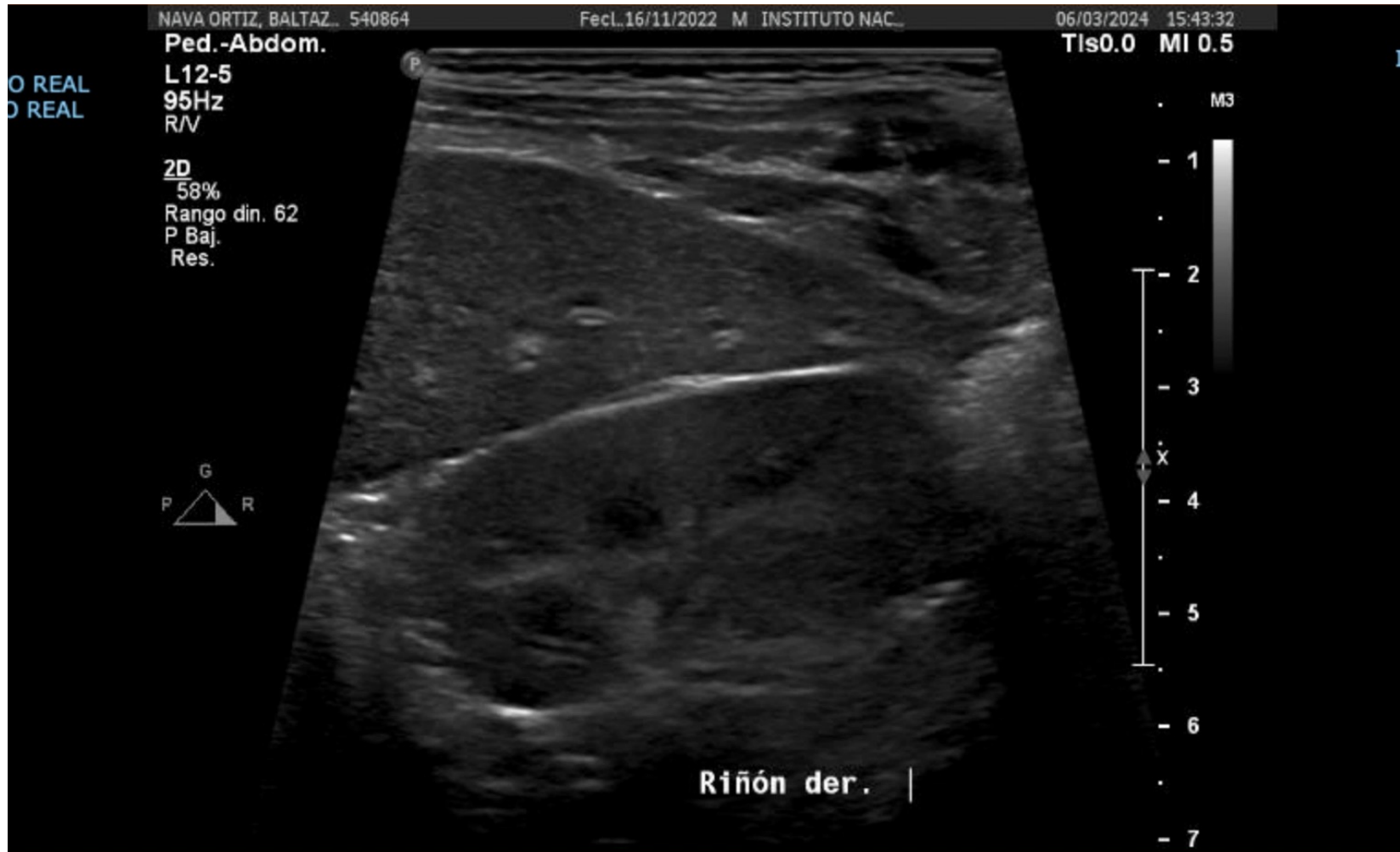- Laparotomy + repair of pinpoint ileal perforation + double-barrel colostomy ( 2022)
- Extravesical laparoscopic reimplantation (2024) (left obstructive megaureter)



# VACTERL

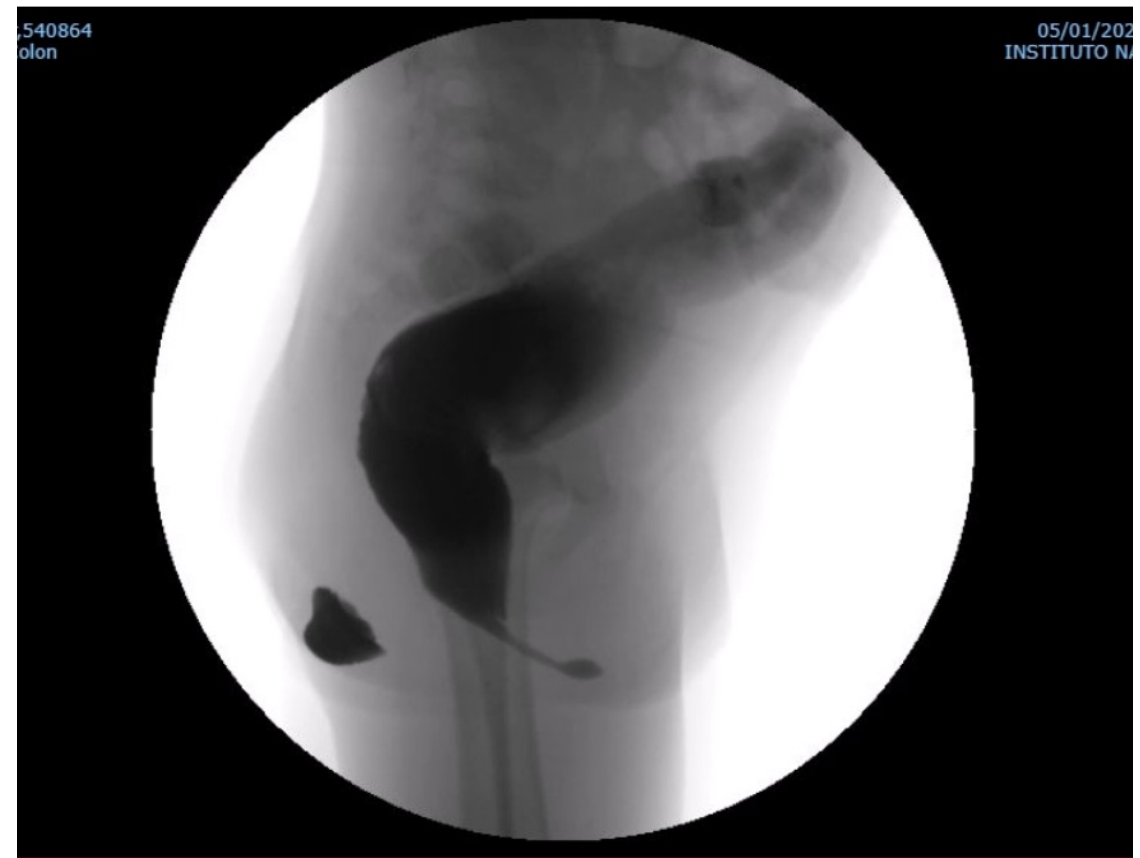
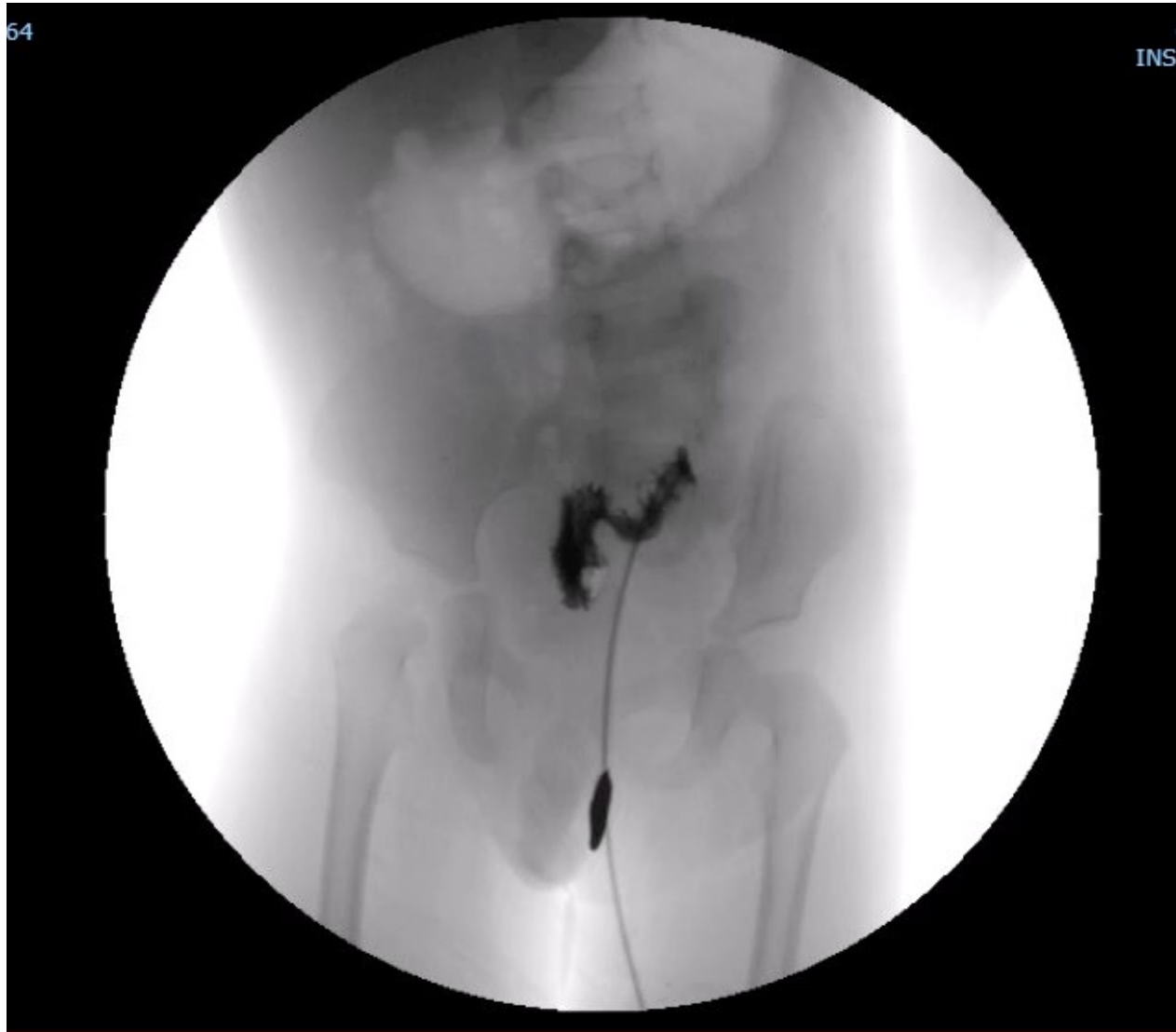- **V- Hemivertebra L5 and fusion of L5-S**
- **A- Anorectal malformation with fistula to the urinary tract**
- **C- No**
- **TE- No**
- **R- Left UV stenosis (double collecting system)**
- **L- Agnesis of thumb, left preaxial ectrodactyly and polydactyly**

# RENAL & VESICAL ULTRASOUND



Dilation of the left urinary tract (UTDP 3)

# DISTAL COLOGRAM

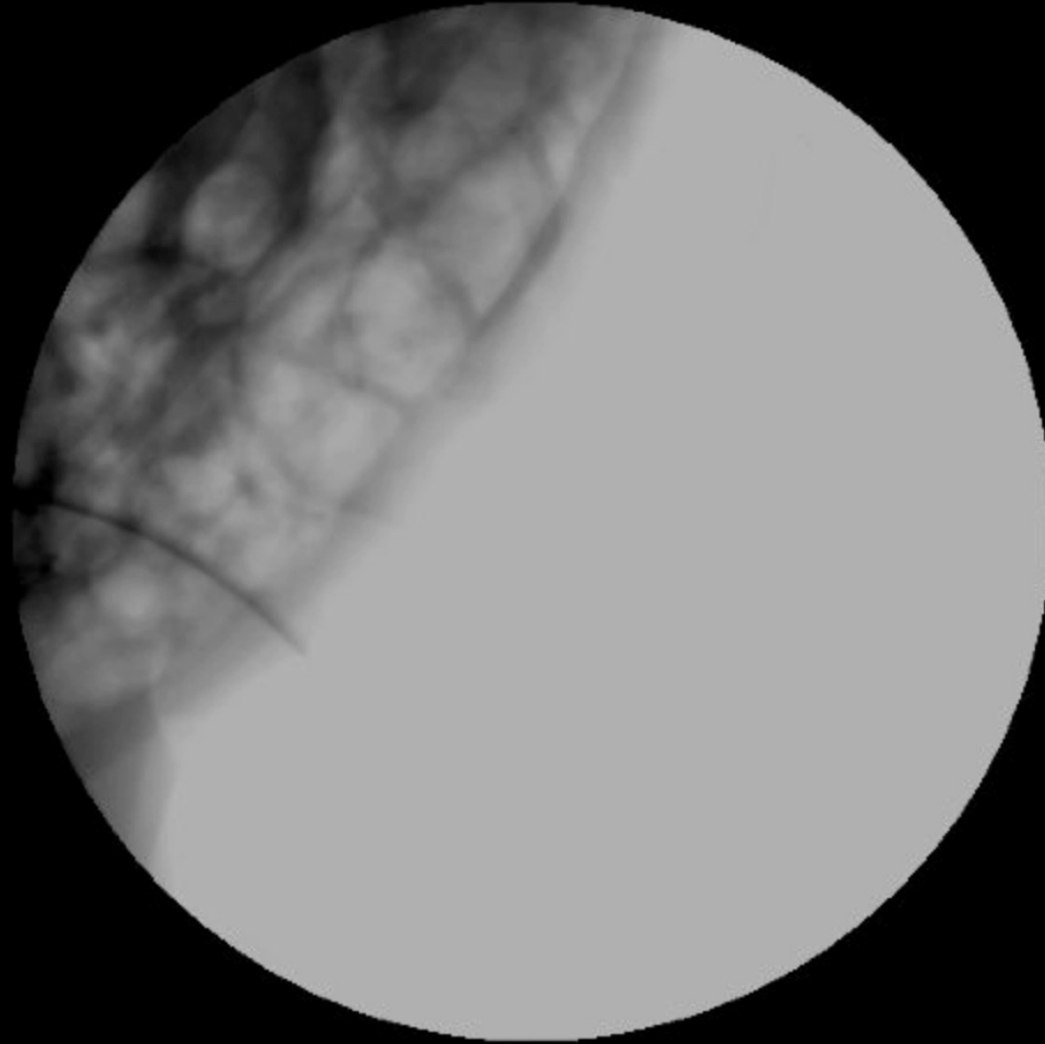


# WHAT WOULD YOU DO?...

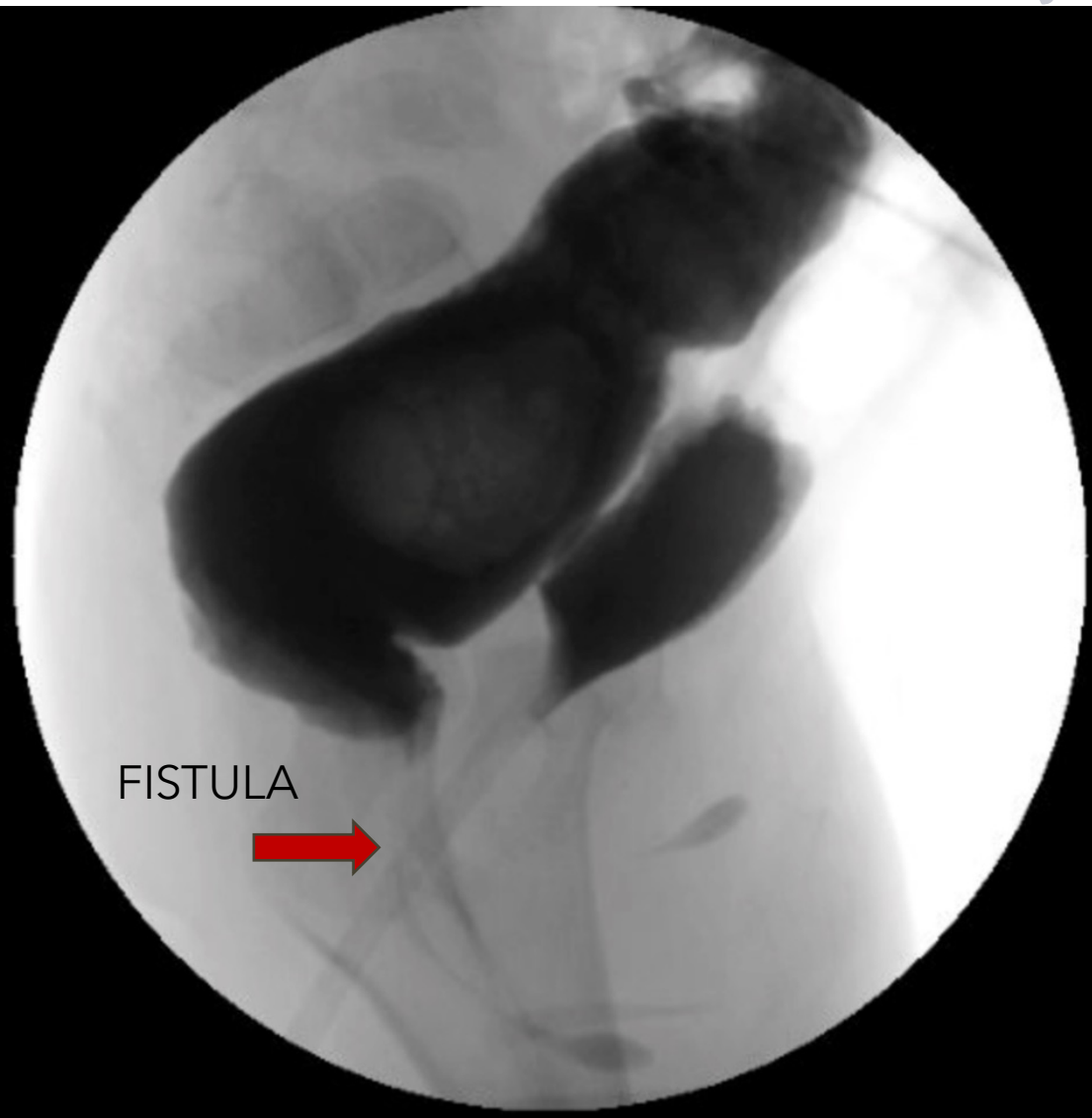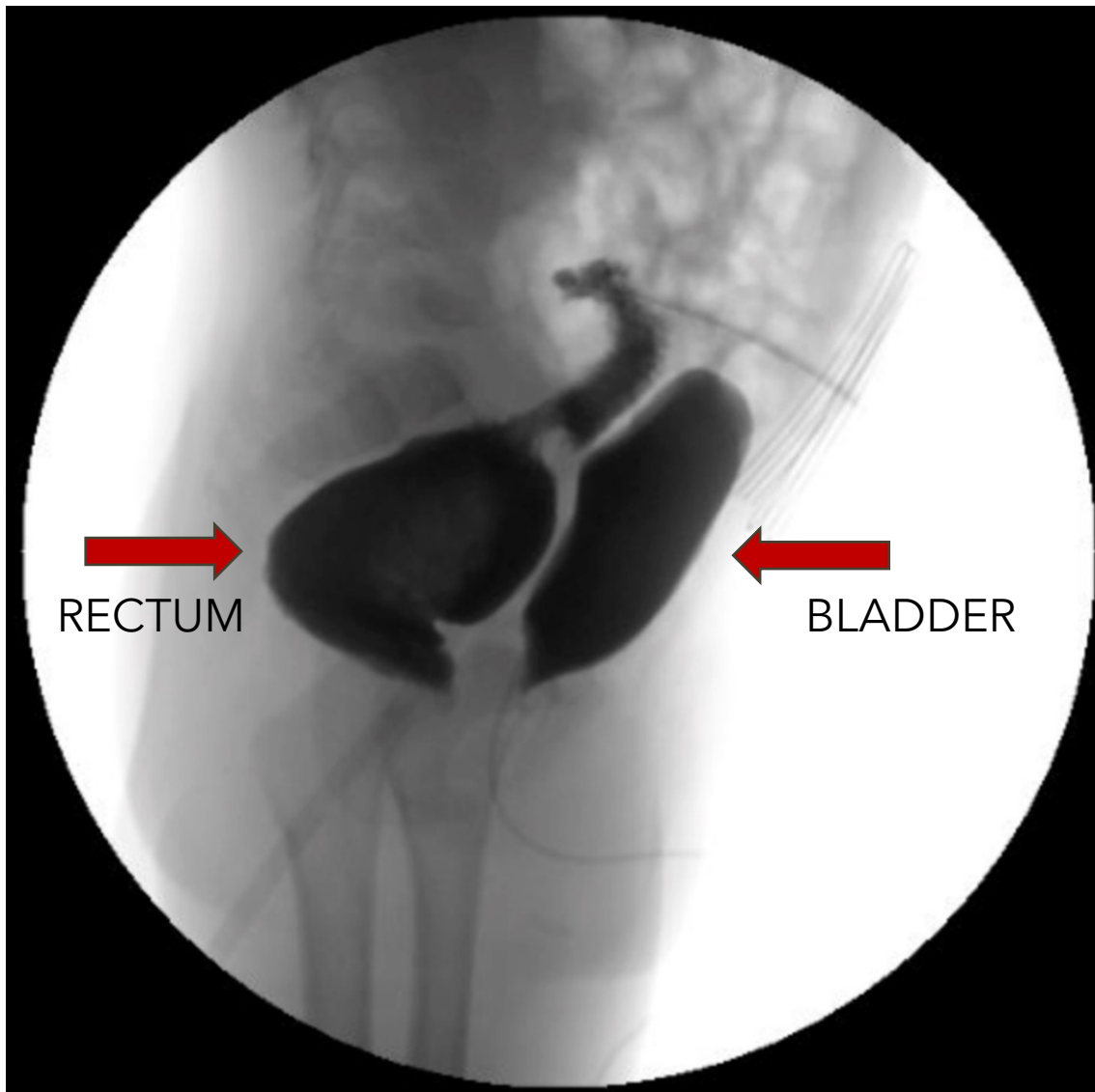
¿Would you perform the surgery?

¿Would you request any further imaging studies?

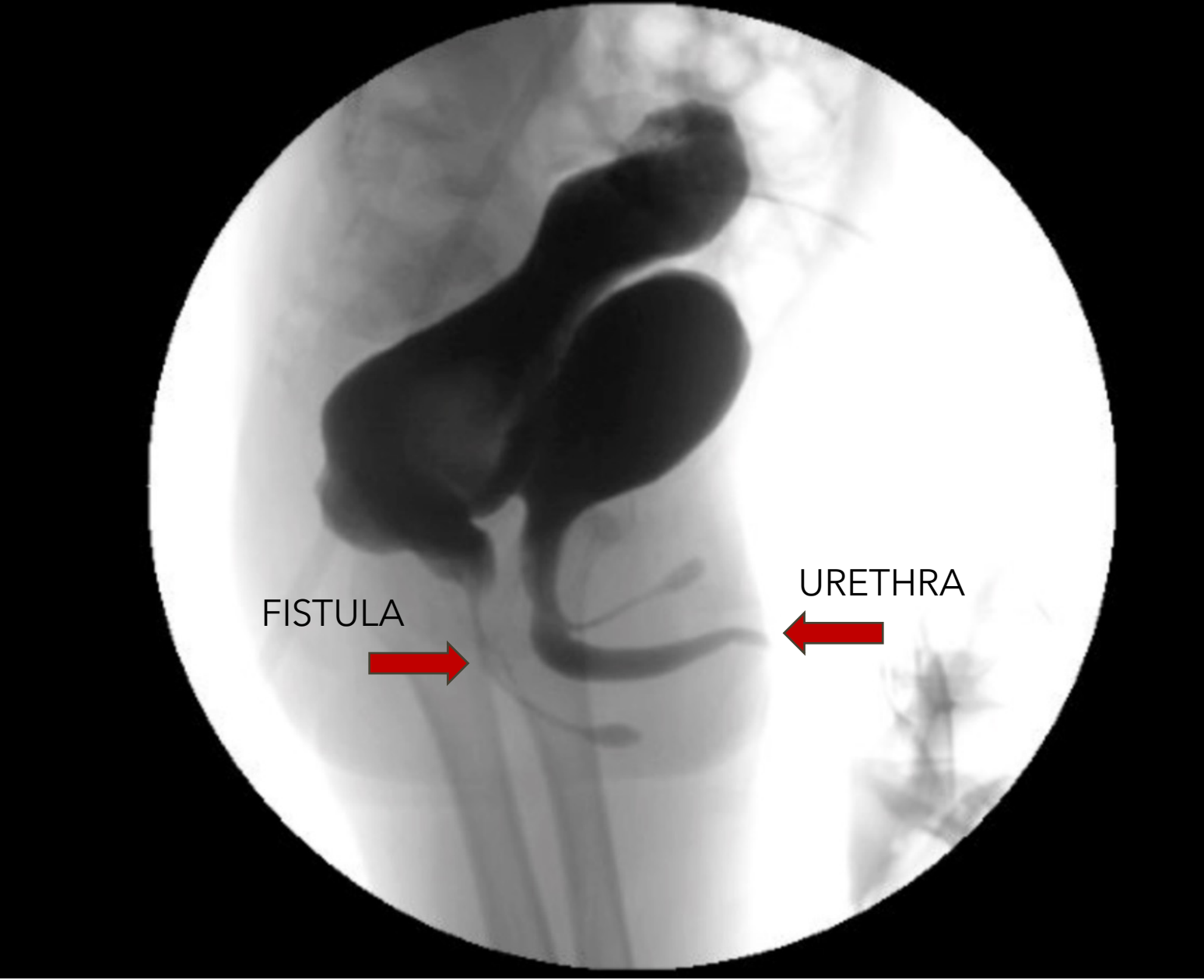




# CONTRAST STUDY







FISTULA



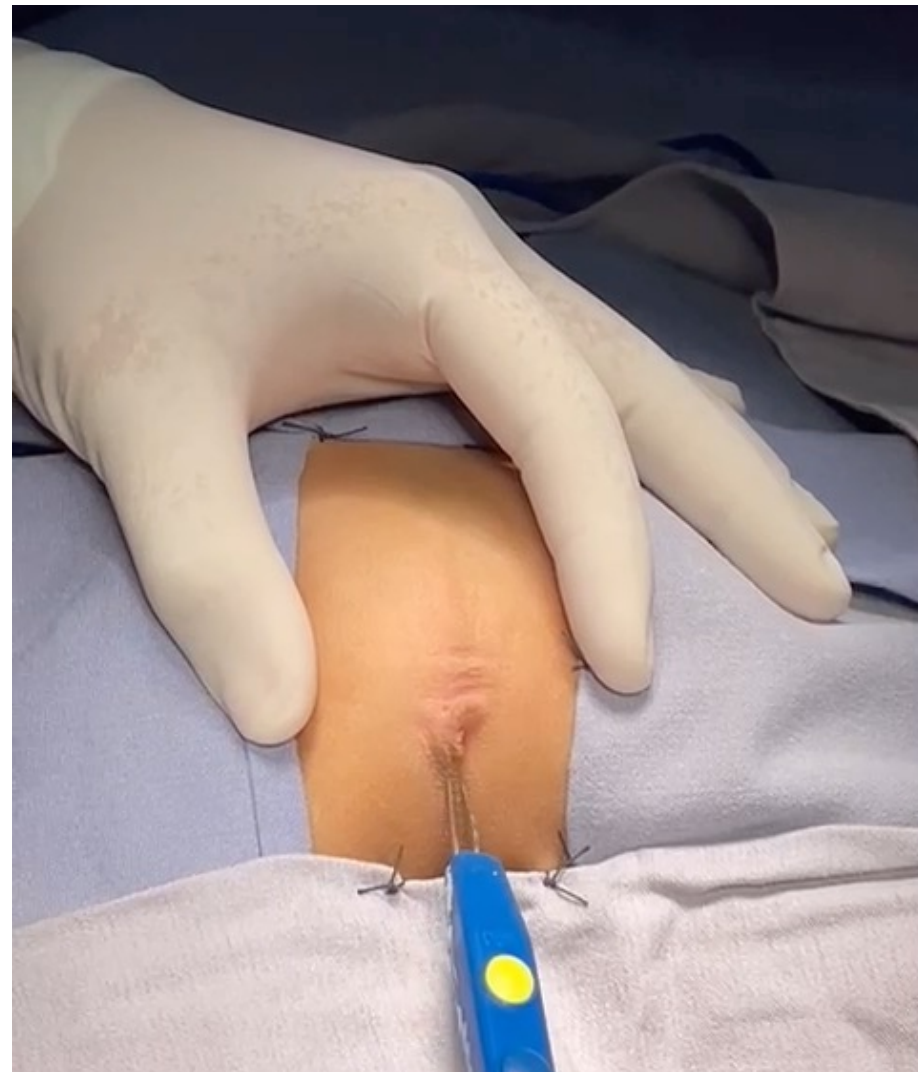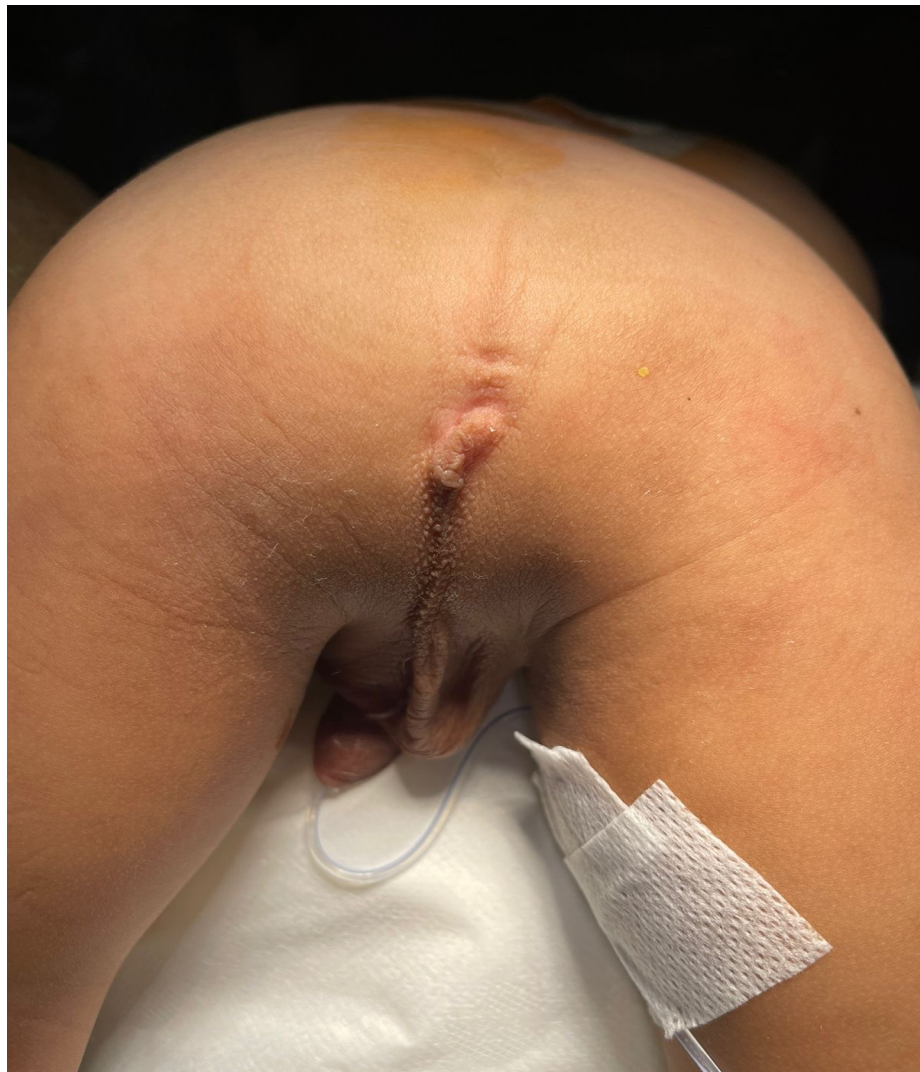URETHRA

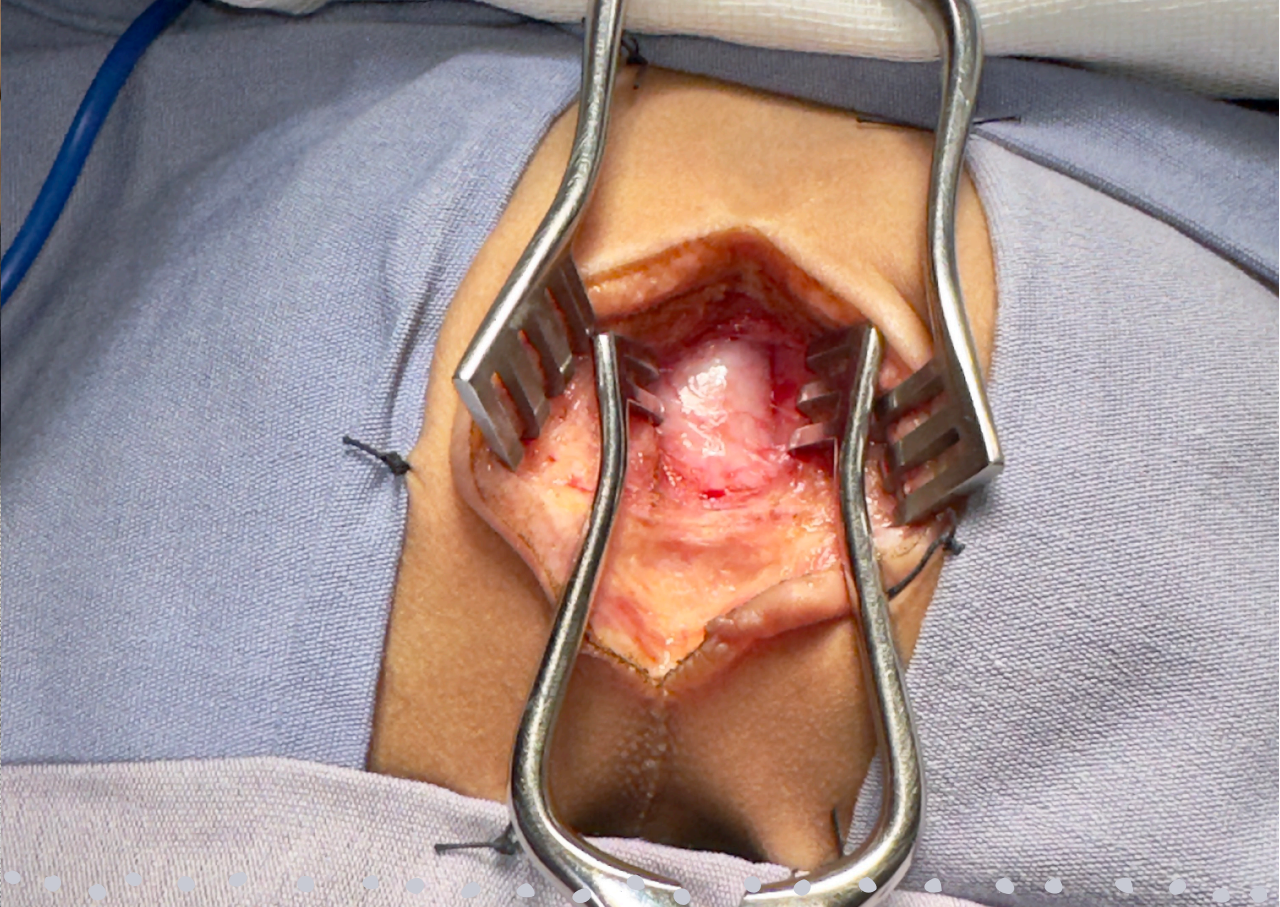
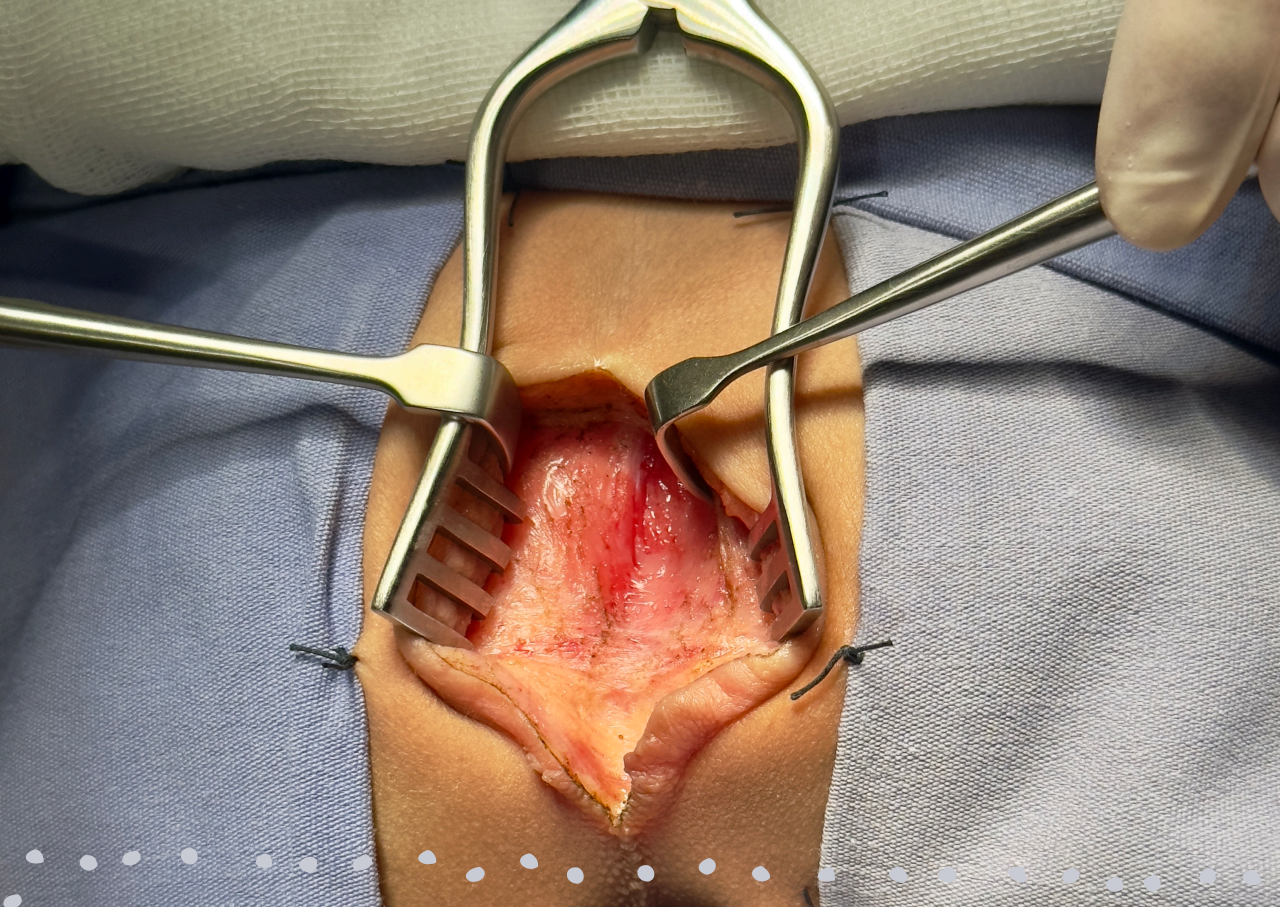


# SURGICAL PLAN

- Case discussion with the Urology department
- Operating room preparation 24 hours in advance
- Conventional Posterior Sagittal Anorectoplasty
- Preoperative preparation with transurethral catheterization in the operating room

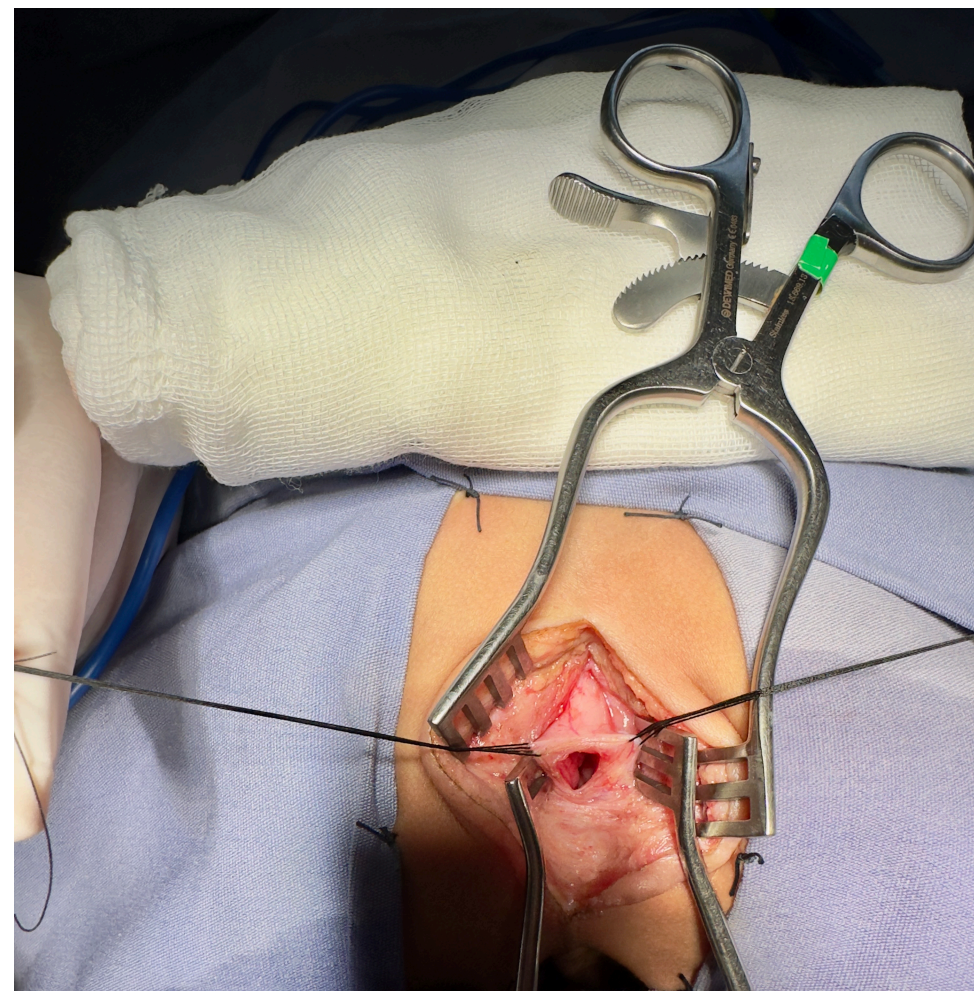
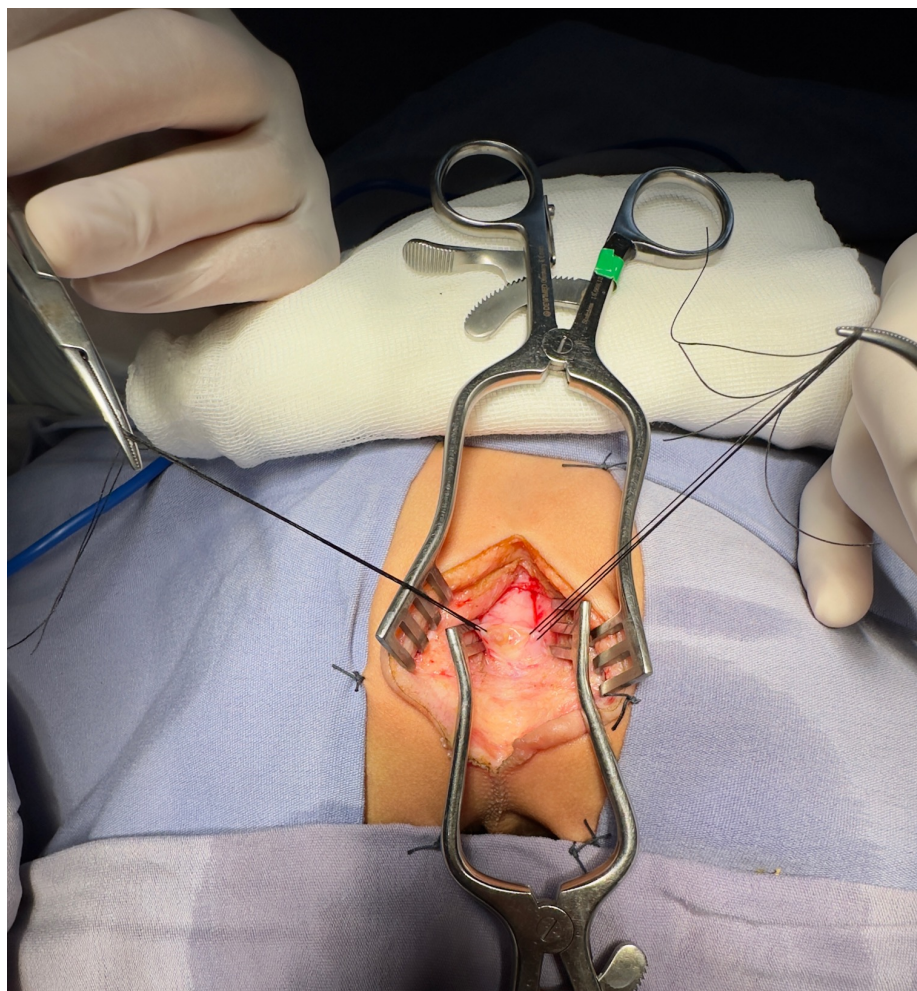
# IDENTIFICATION OF MUSCULAR COMPLEX



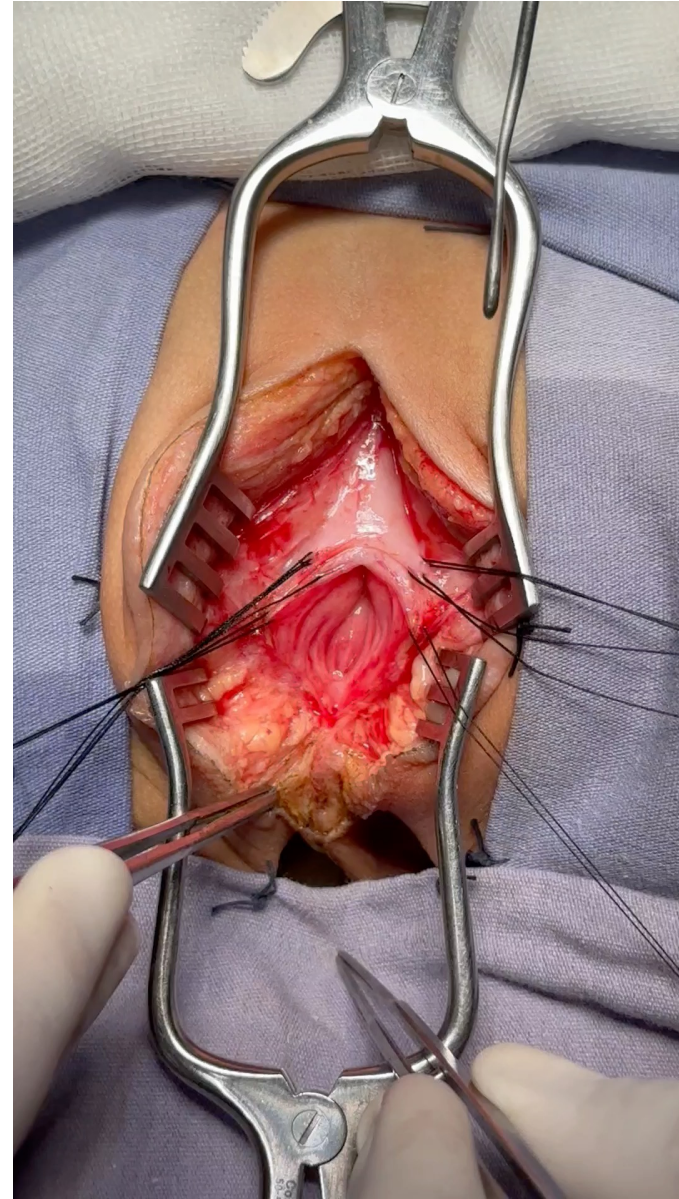
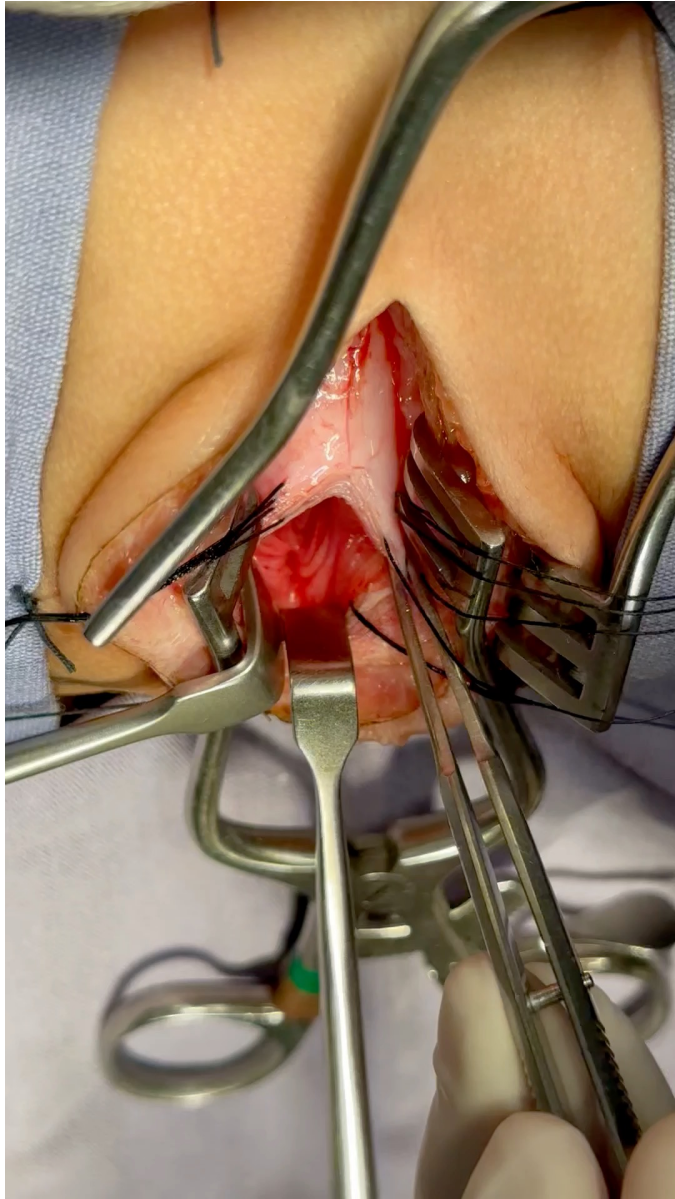


**CONVENTIONAL POSTERIOR SAGITTAL**

# IDENTIFICATION OF THE RECTUM

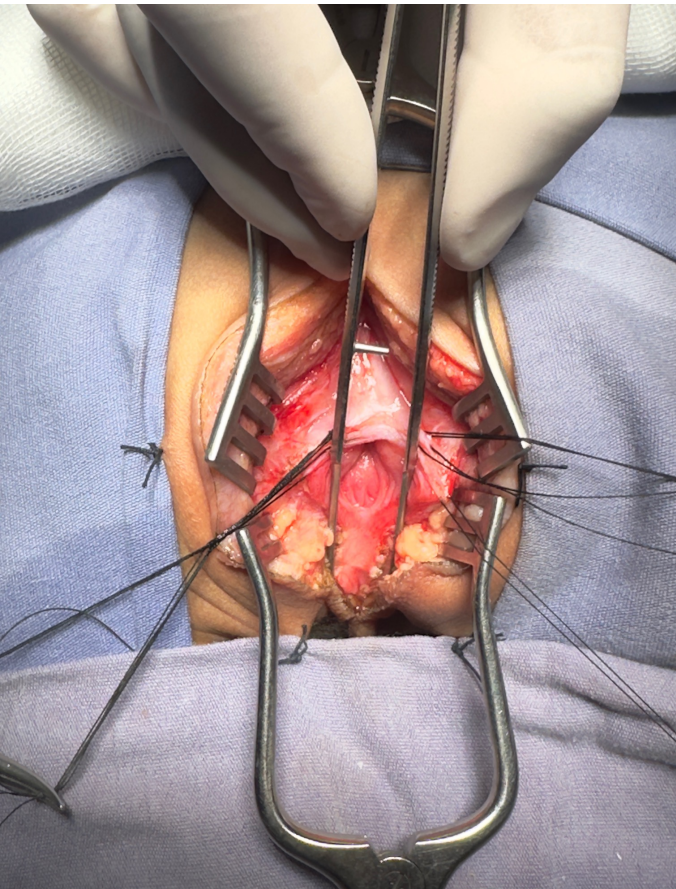


# IDENTIFICATION OF THE FALSE URETHRAL FISTULA

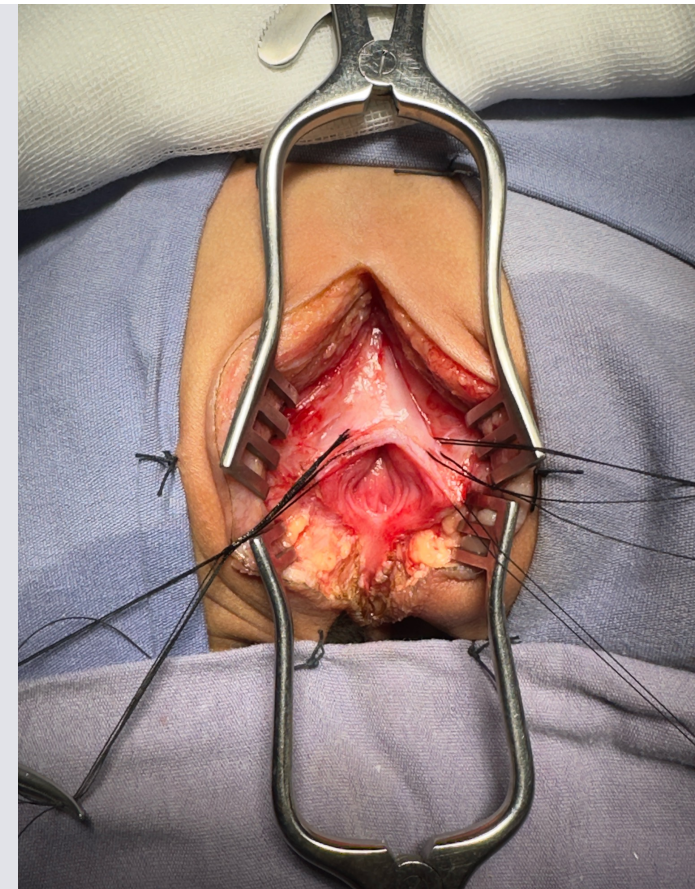


# WHAT WOULD YOU DO?

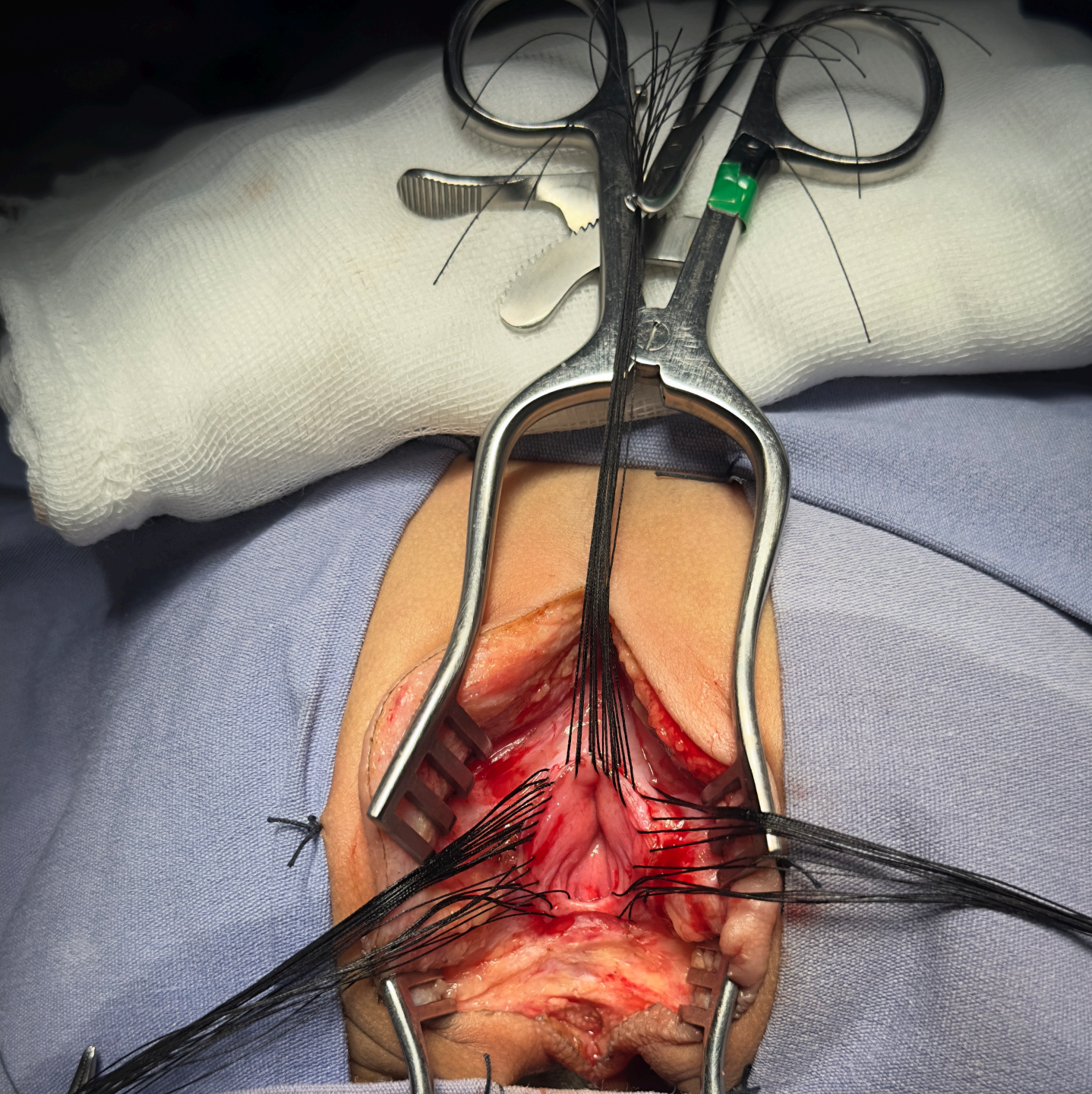
- **A) Dissect the fistula and close with absorbable sutures**
- **B) Dissect the fistula and cut, do not place sutures**
- **C) Dissect the fistula on the posterior wall and perform mucosectomy**
- **D) Seek assistance from the urologist**
- **E) I don't know what I would have done**



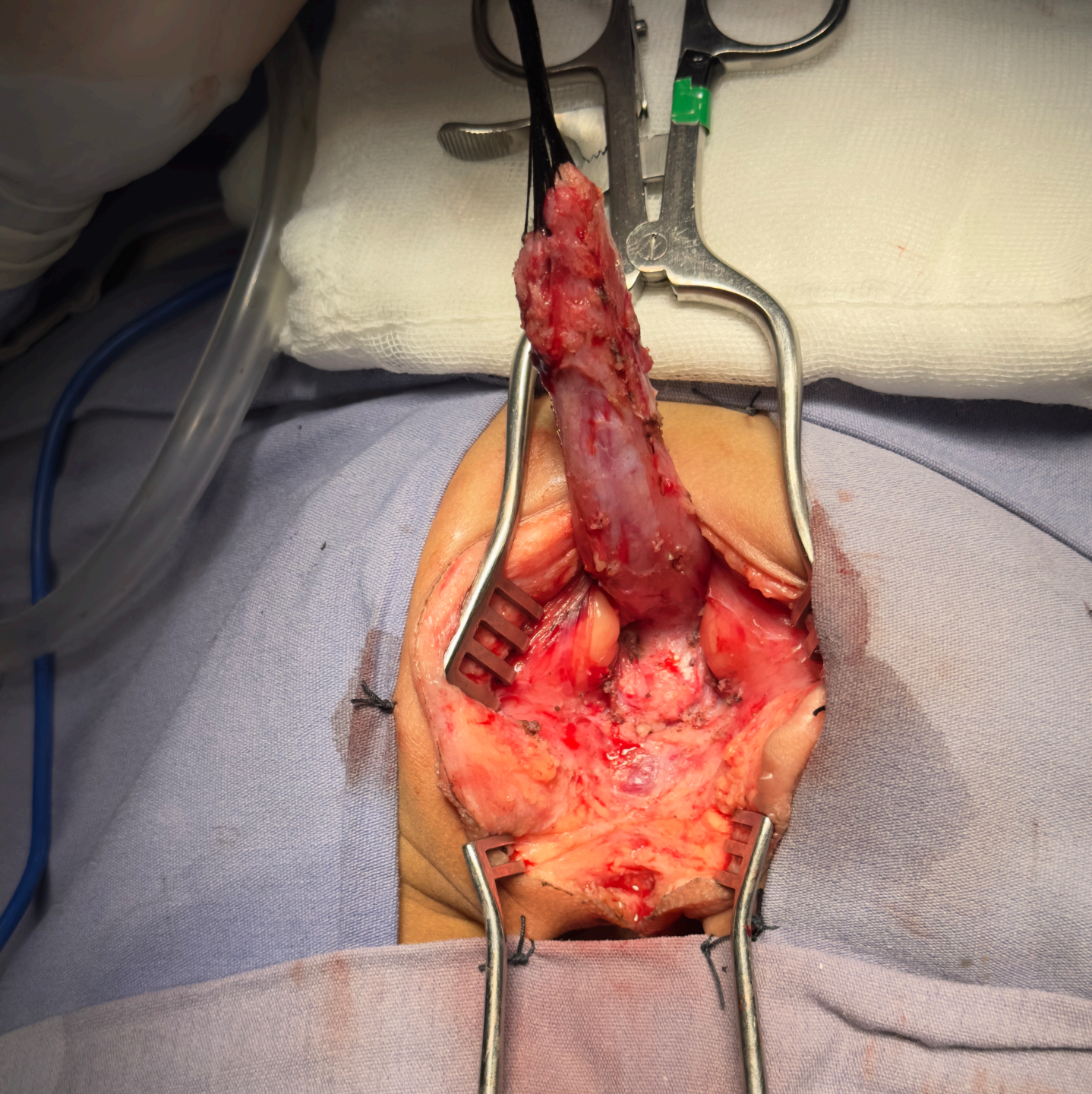
*Dissection of the fistula  
on the posterior wall  
and perform  
mucosectomy*



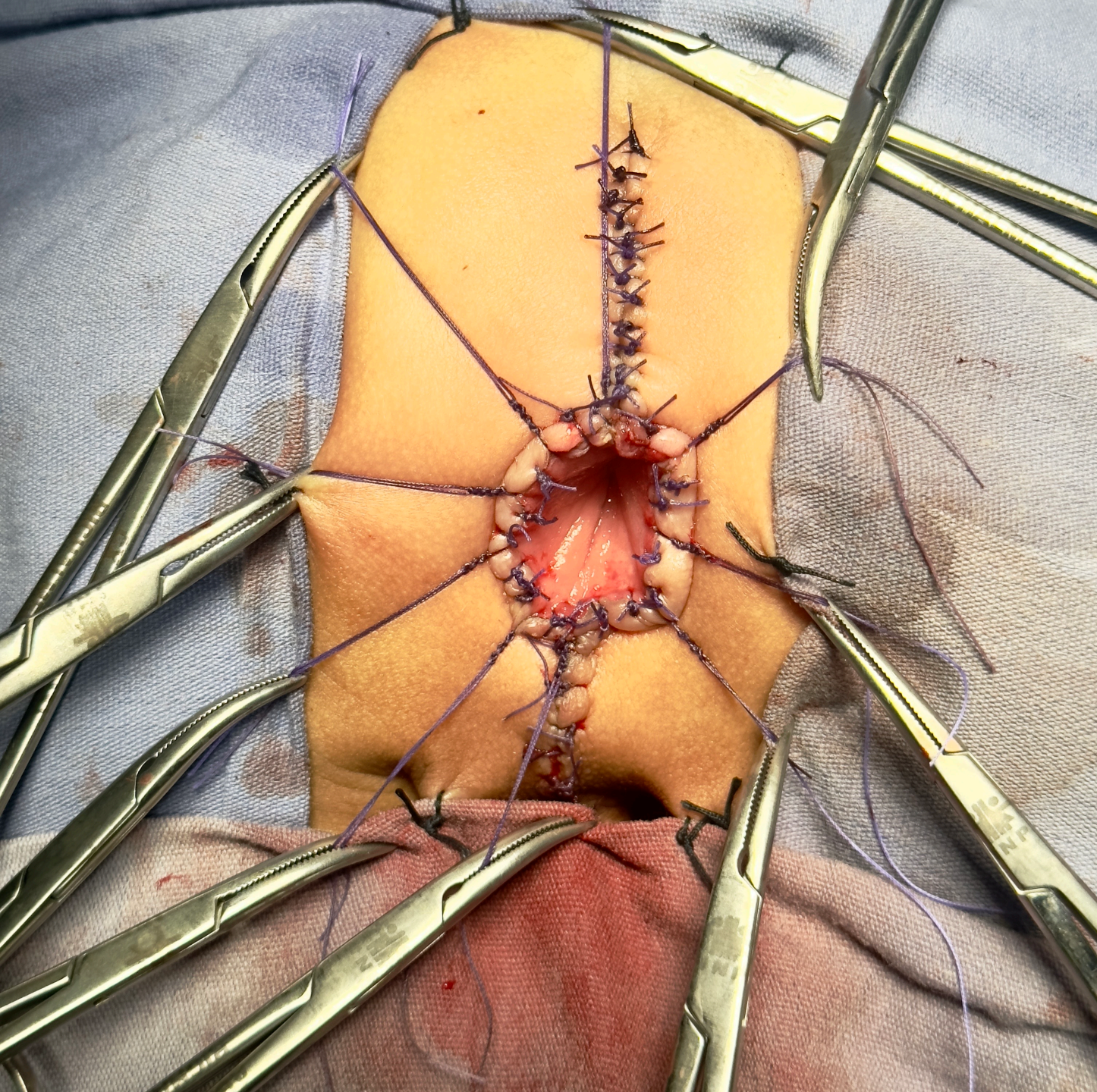




*Mucosectomy of  
the false  
urethral fistula*



# DISSECTION OF THE RECTUM



**PERINEAL  
RECONSTRUCTION,  
POSTERIOR  
SAGITTAL AND  
ANOPLASTY**

**THANK YOU!!!** 😊

