

# Surgical Case

Hospital Infantil de México “Federico Gómez”

Mexico City

Dra. Brenda Domínguez Zúñiga

Dr. Emilio Fernández Portilla

Dr. Roberto Dávila Pérez

Dr. Alfredo Domínguez Muñoz





# MEDICAL HISTORY

- Female ♀
- 9 years old
- No history of illness in her family



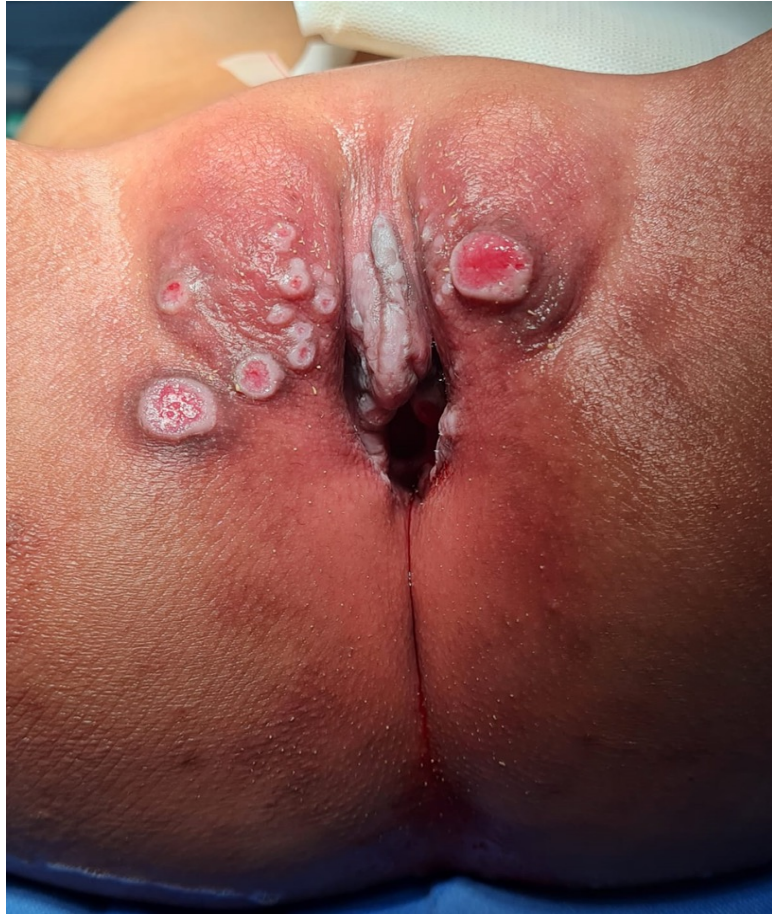# MEDICAL HISTORY

- Late diagnosis of anorectal malformation (8 yo)
  - September 2022 First time at colorrectal center

## Physical examination:

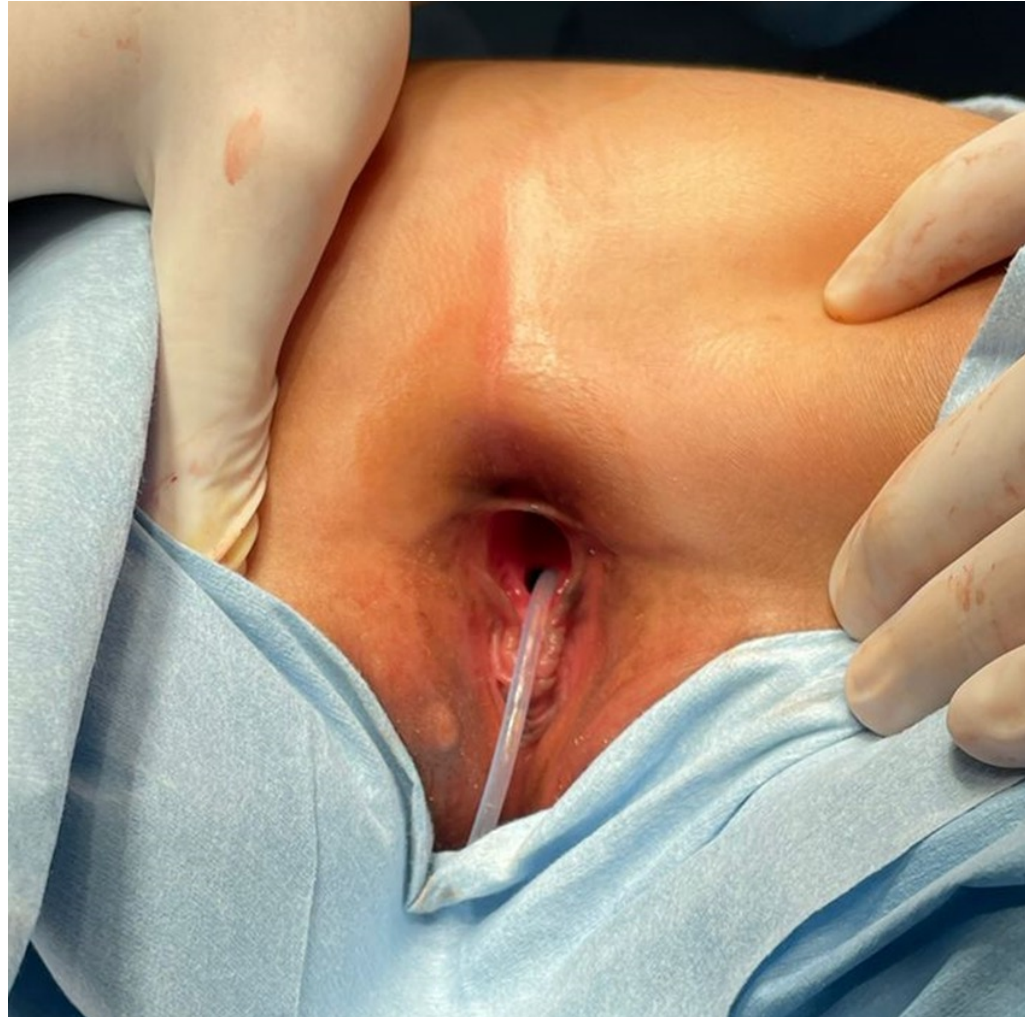
- Lumbar scoliosis
- Anorectal malformation: vestibular fistula
- Vaginal agenesis

# Physical exam



- Urinary incontinence
  - Incontinence-associated dermatitis
- Vaginal agenesis
- Anorectal malformation: vestibular fistula

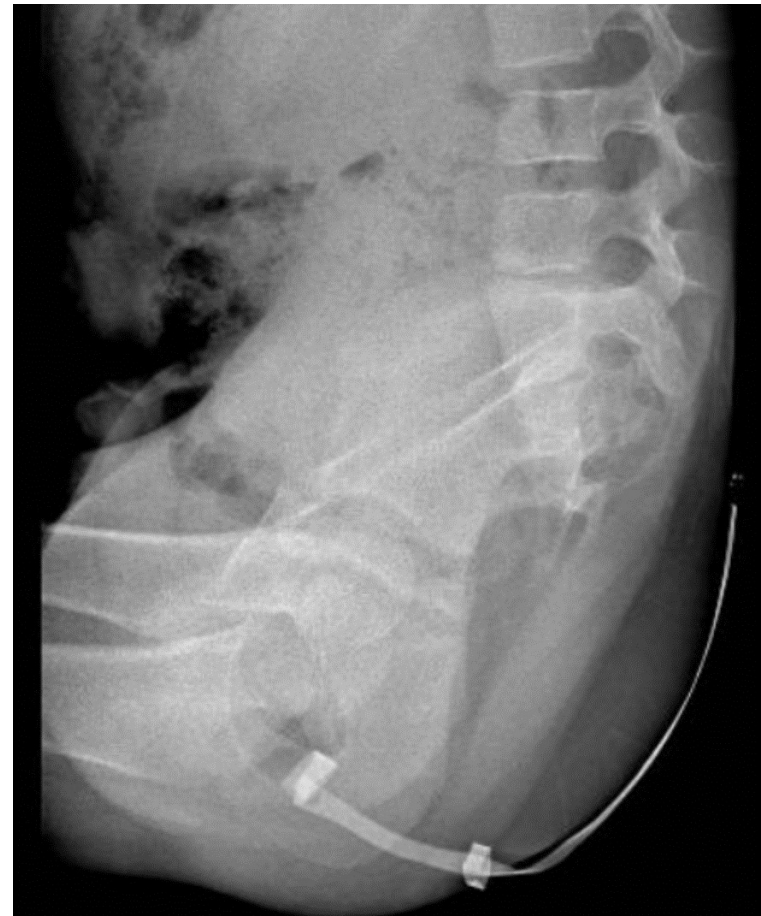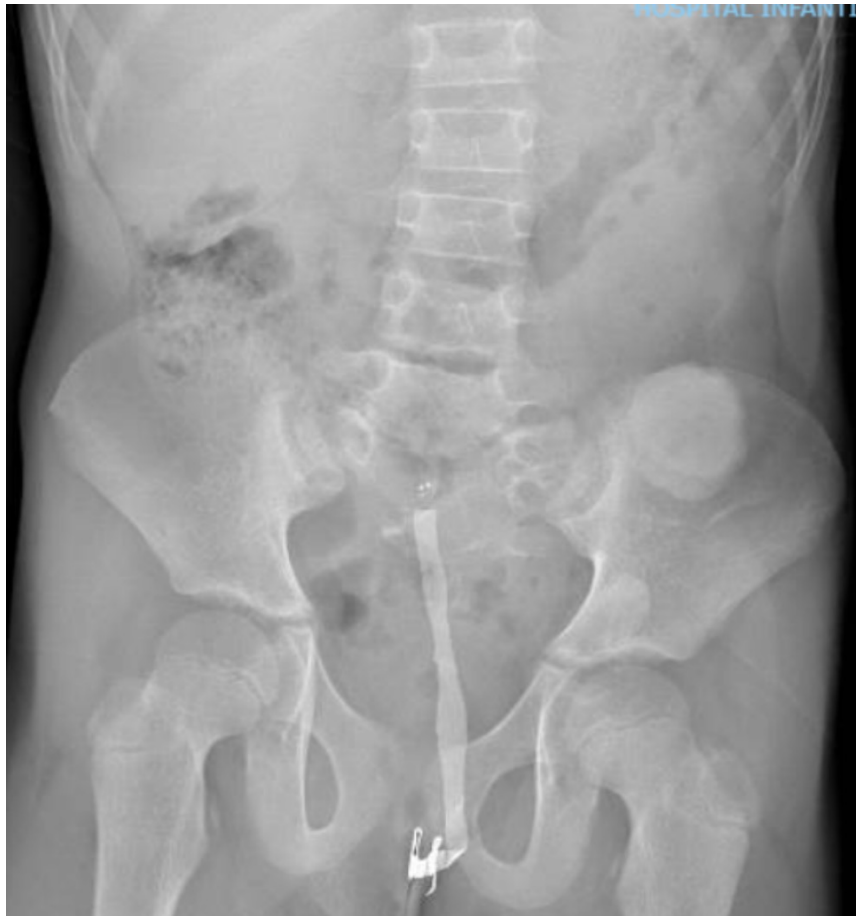# Physical exam

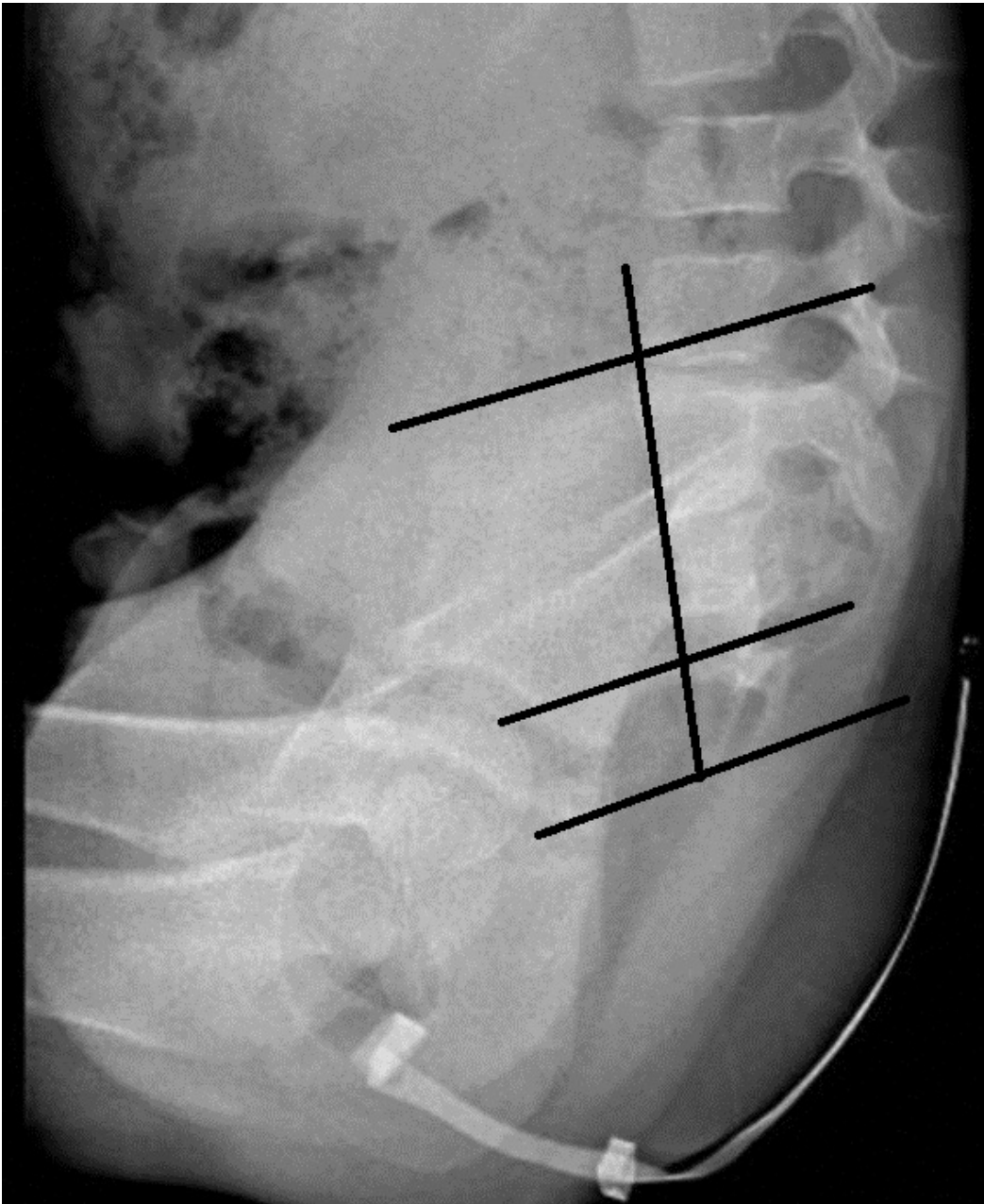


# SURGICAL TREATMENT

- Colostomy
  - Meckel's diverticulum
  - Absent uterus

# X-RAY FILMS: abnormal sacrum

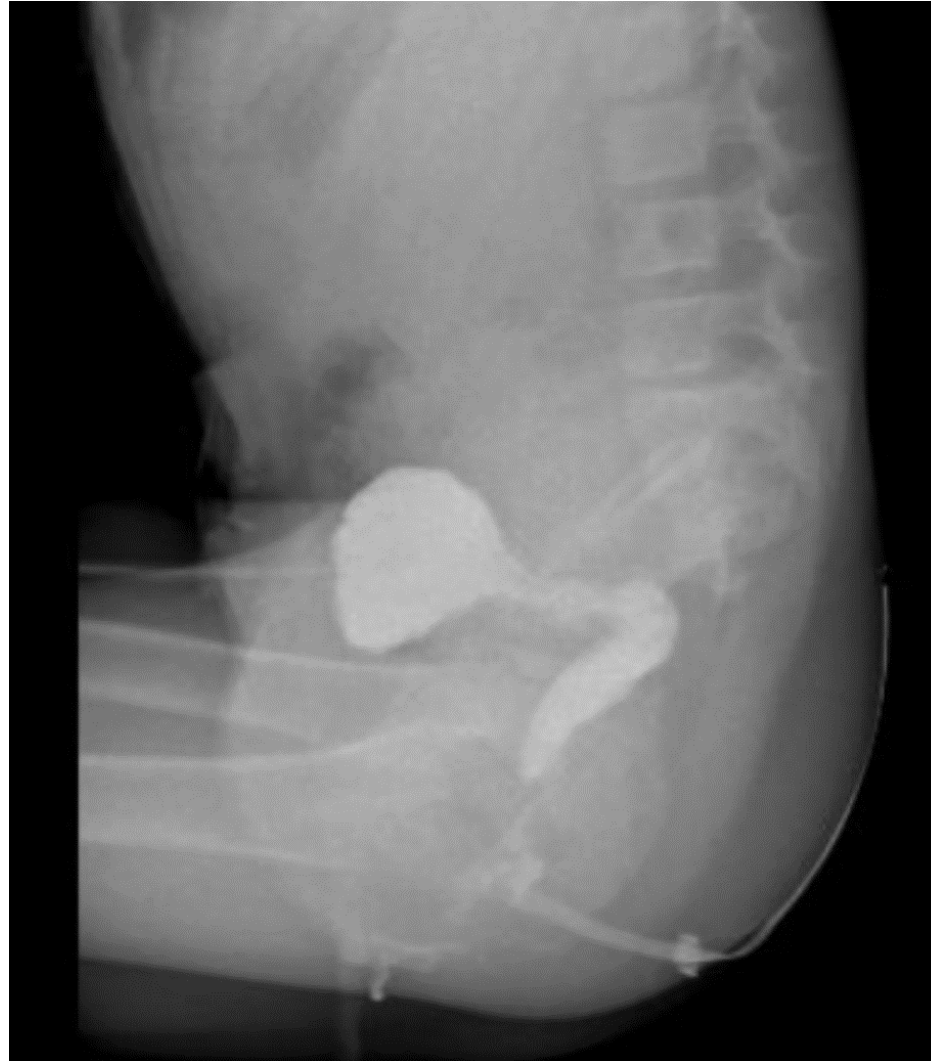

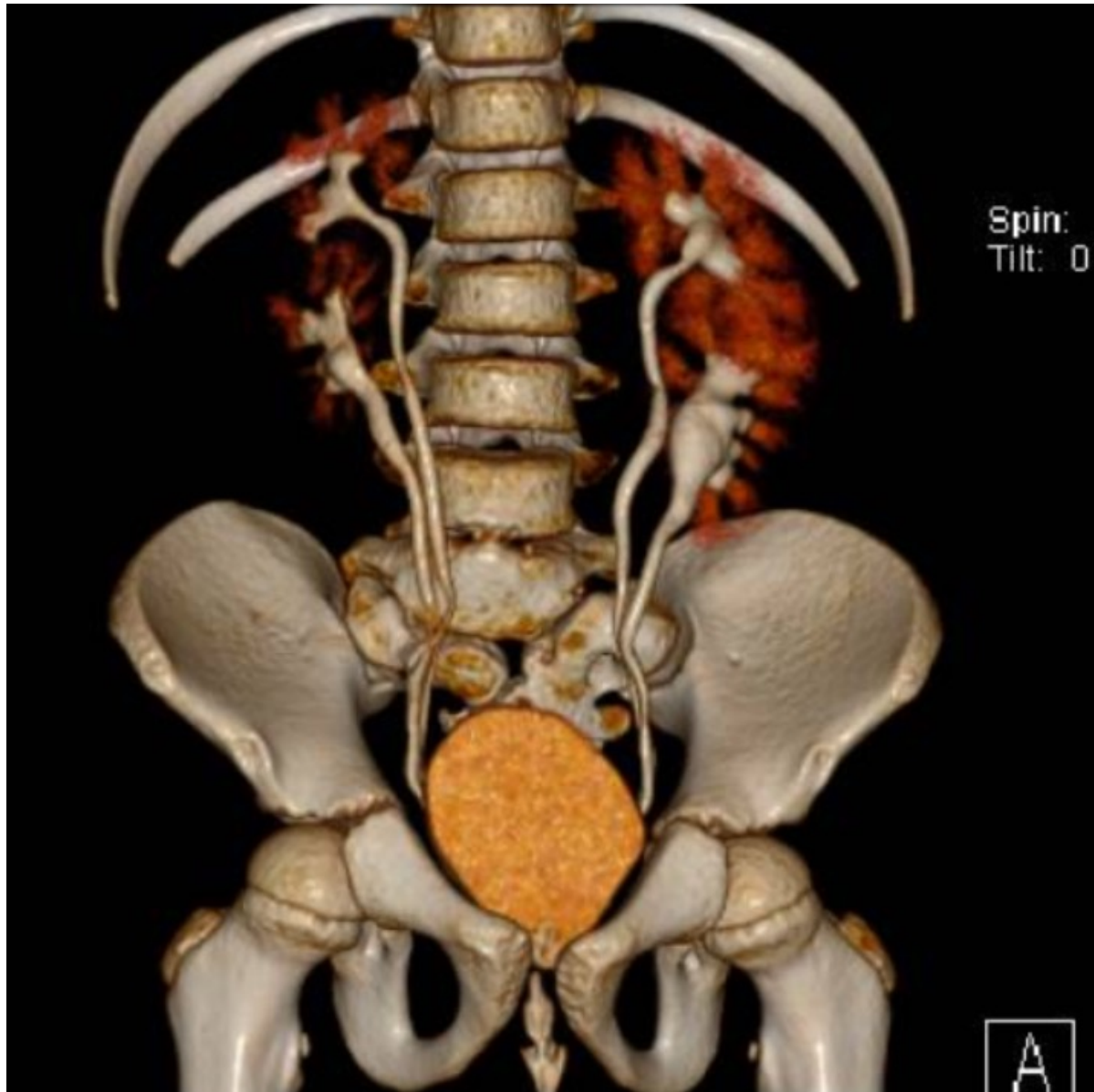


Sacrum ratio: 0.3



# Distal colostogram





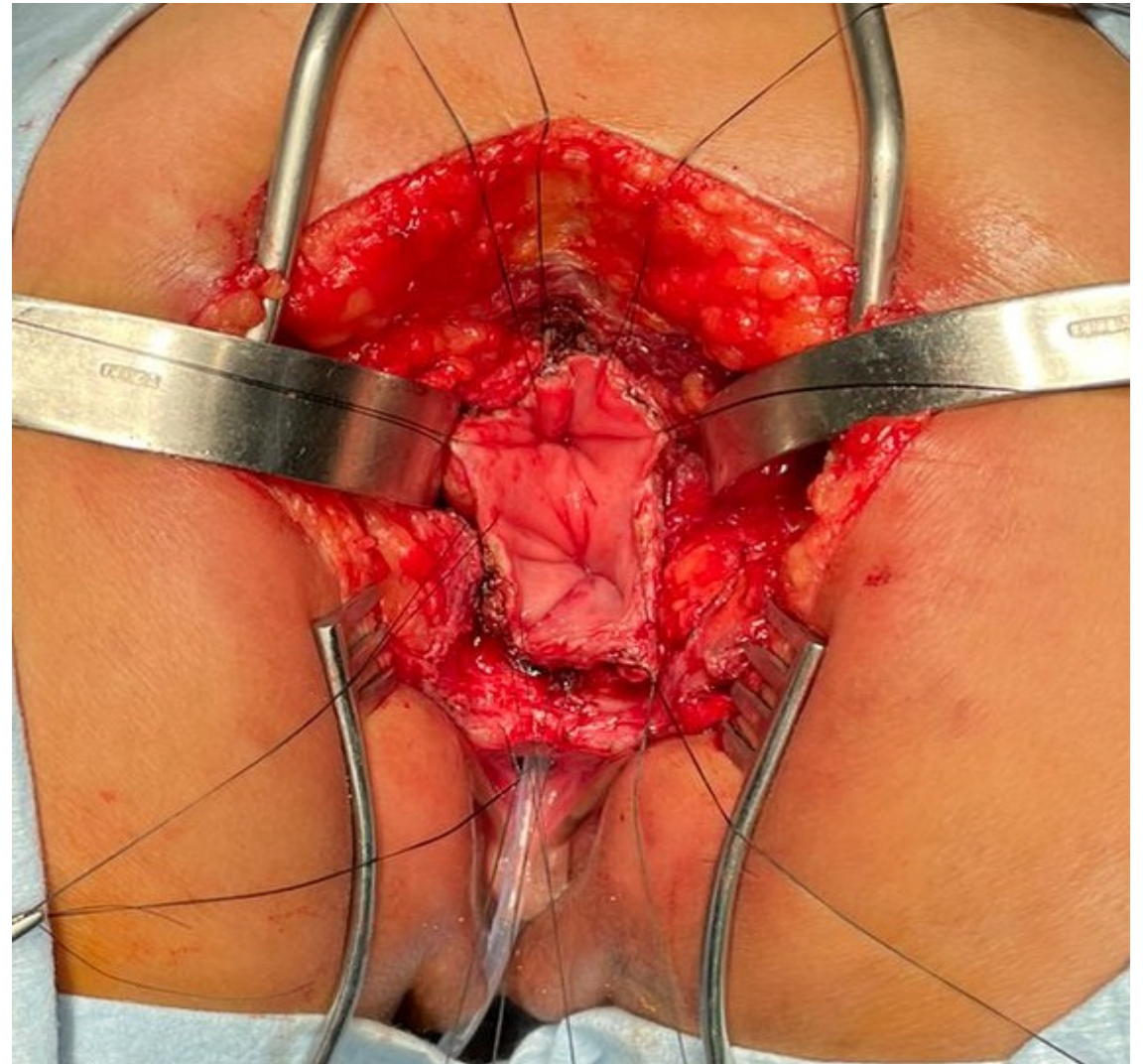
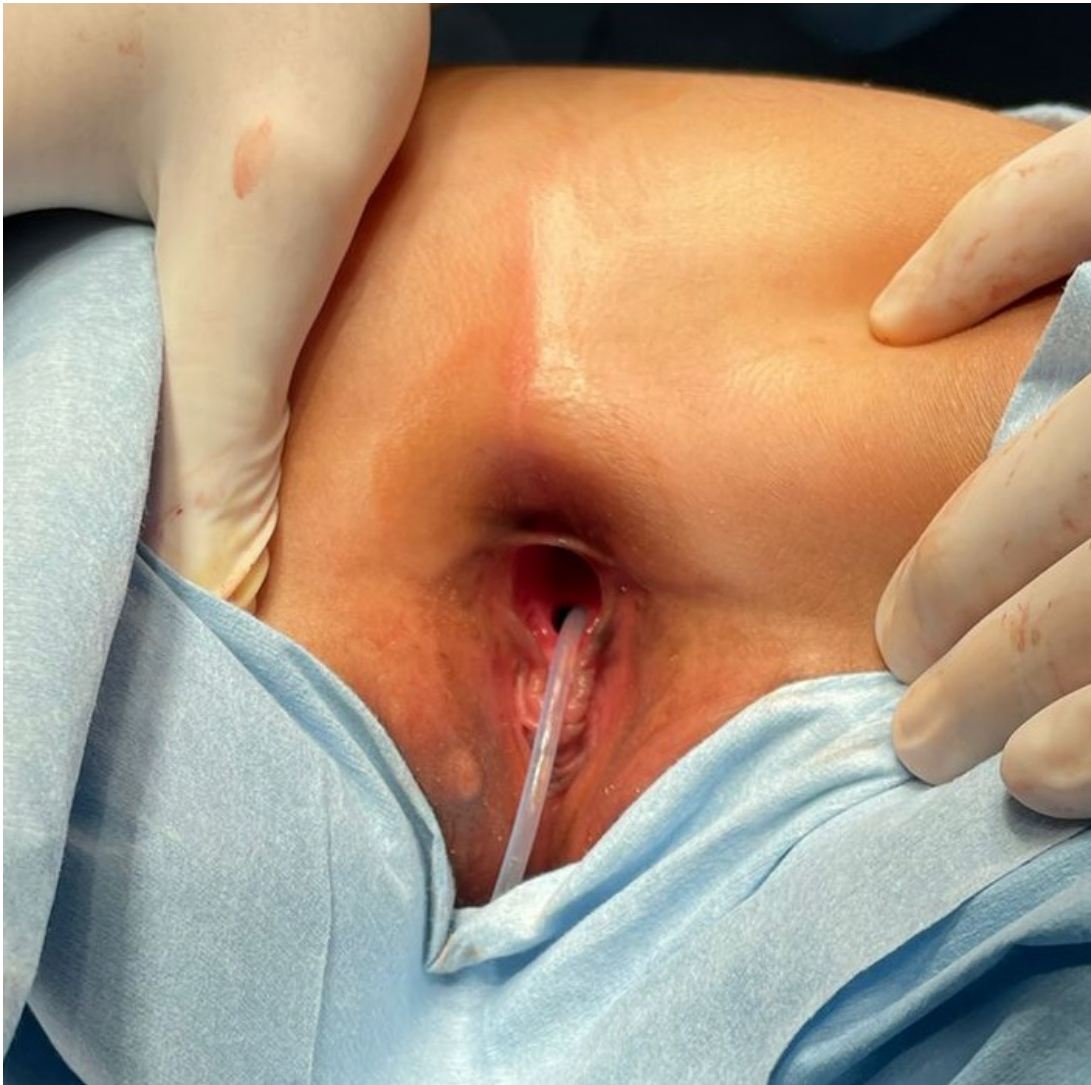
Double excretory system (bilateral)

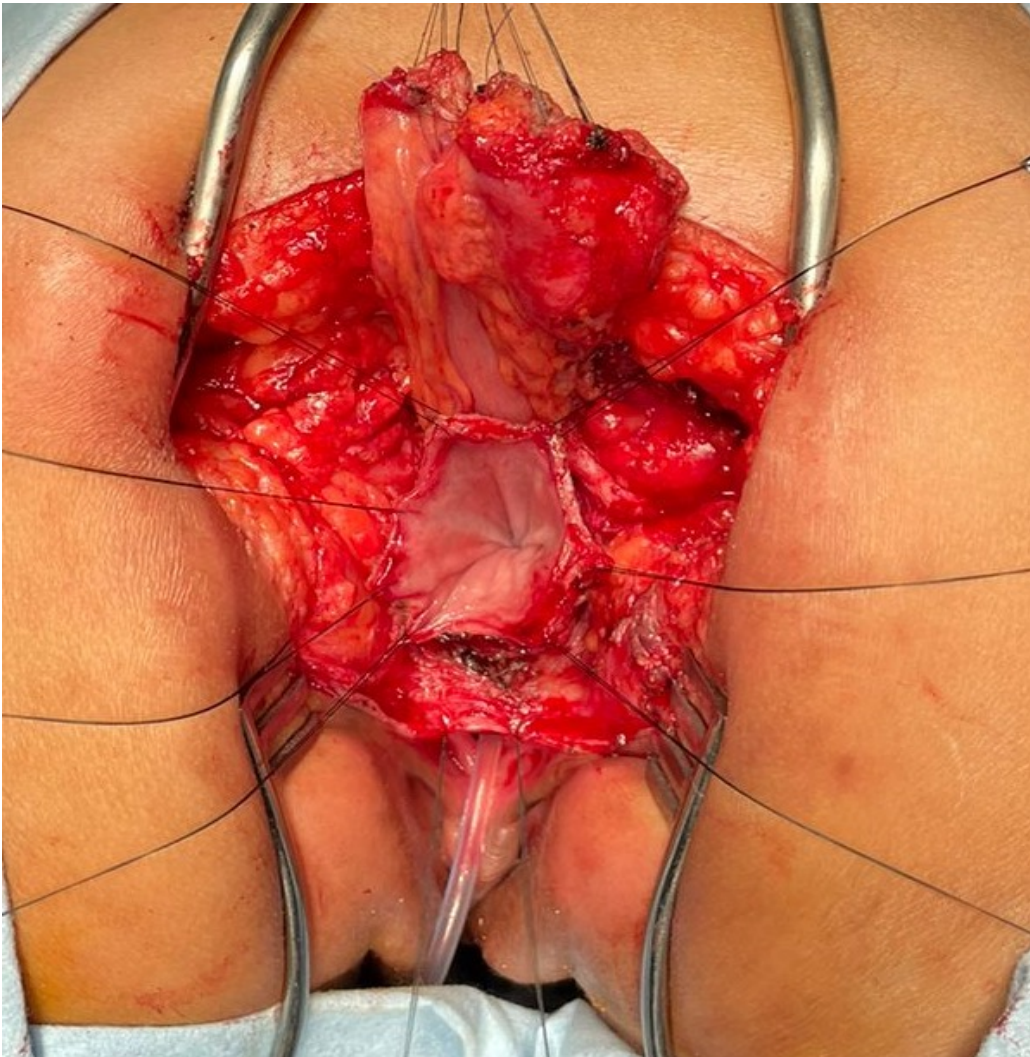
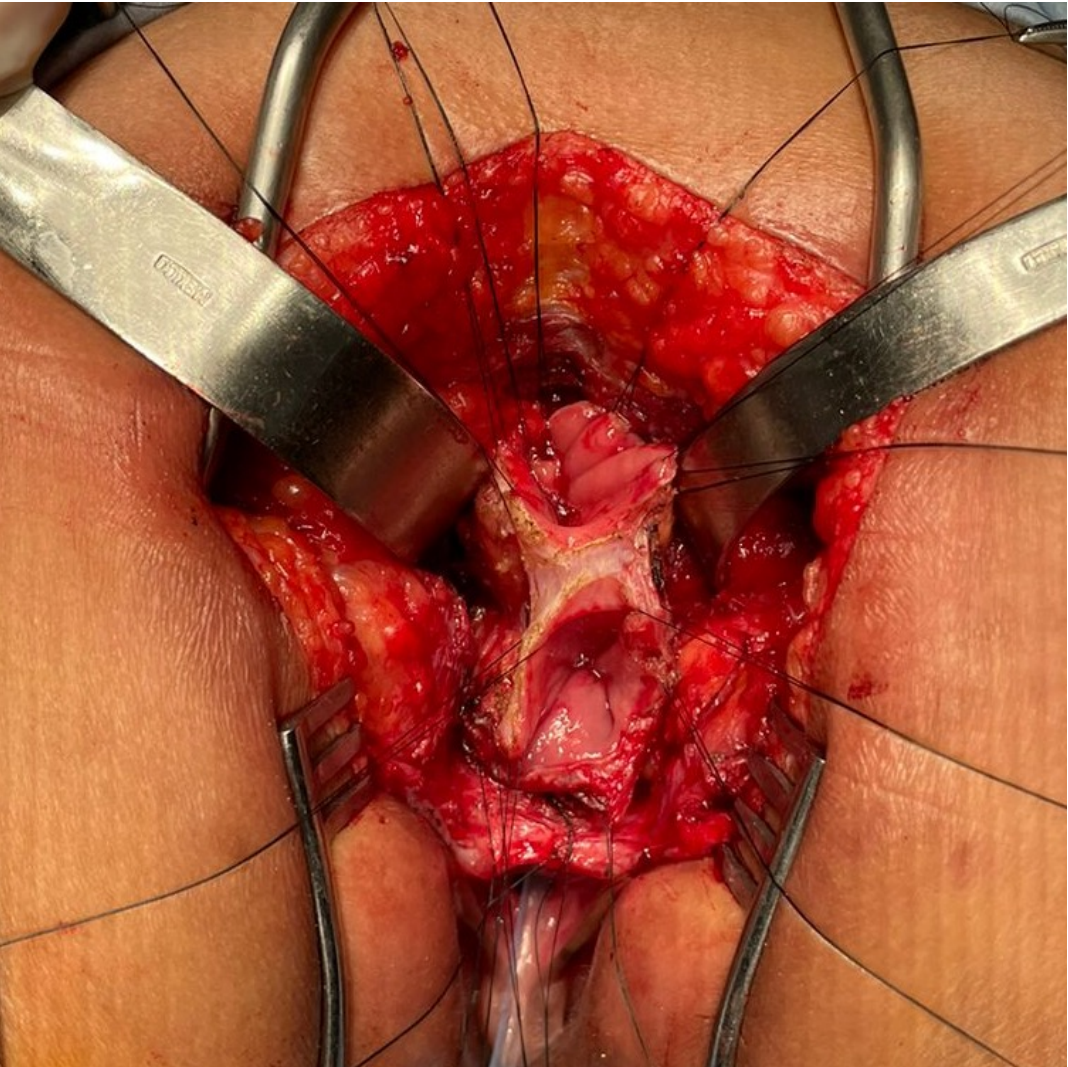
# QUESTION 1

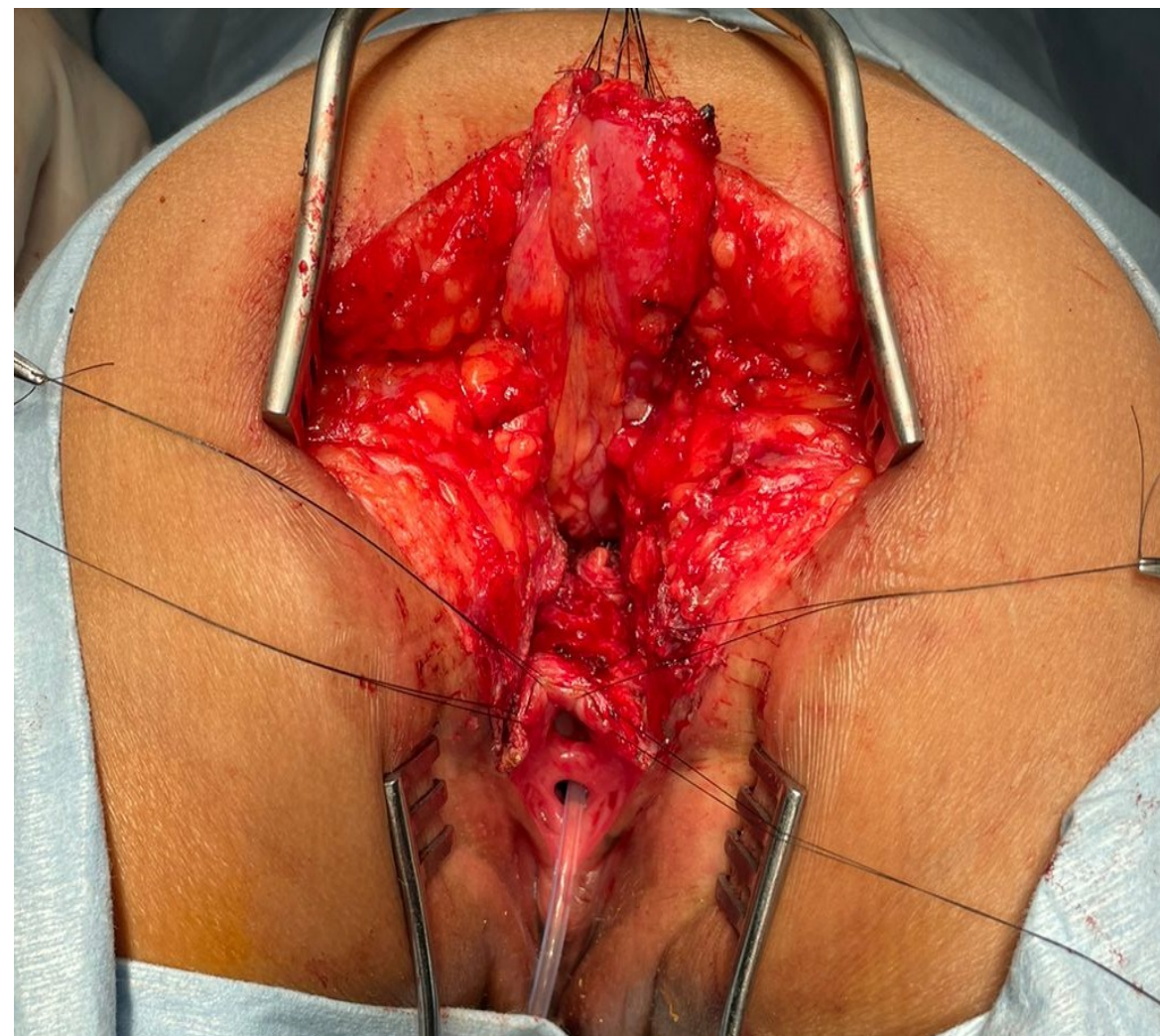
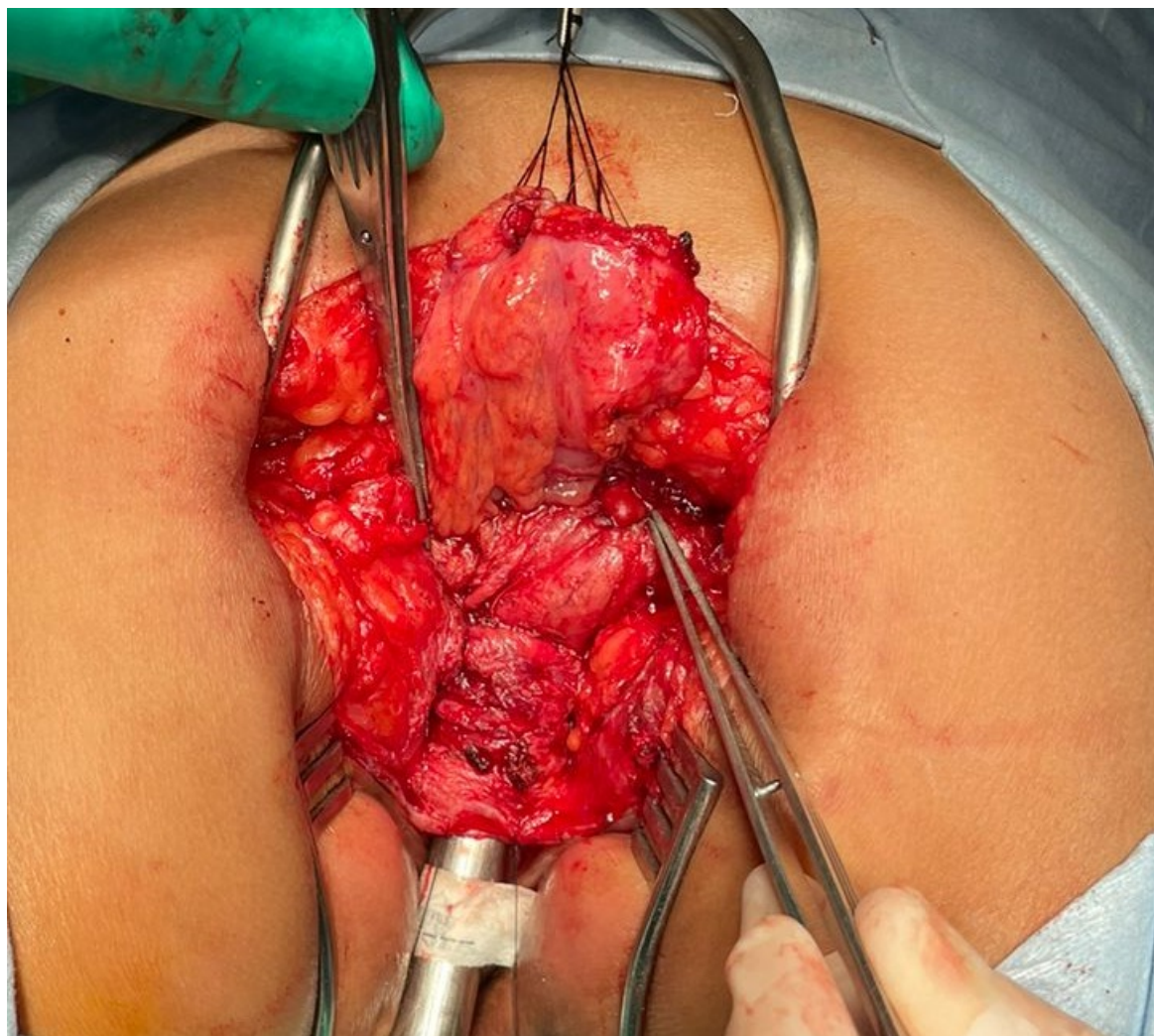
- What are the chances for bowel control?
  - A) Excellent
  - B) Poor
  - C) I am not sure

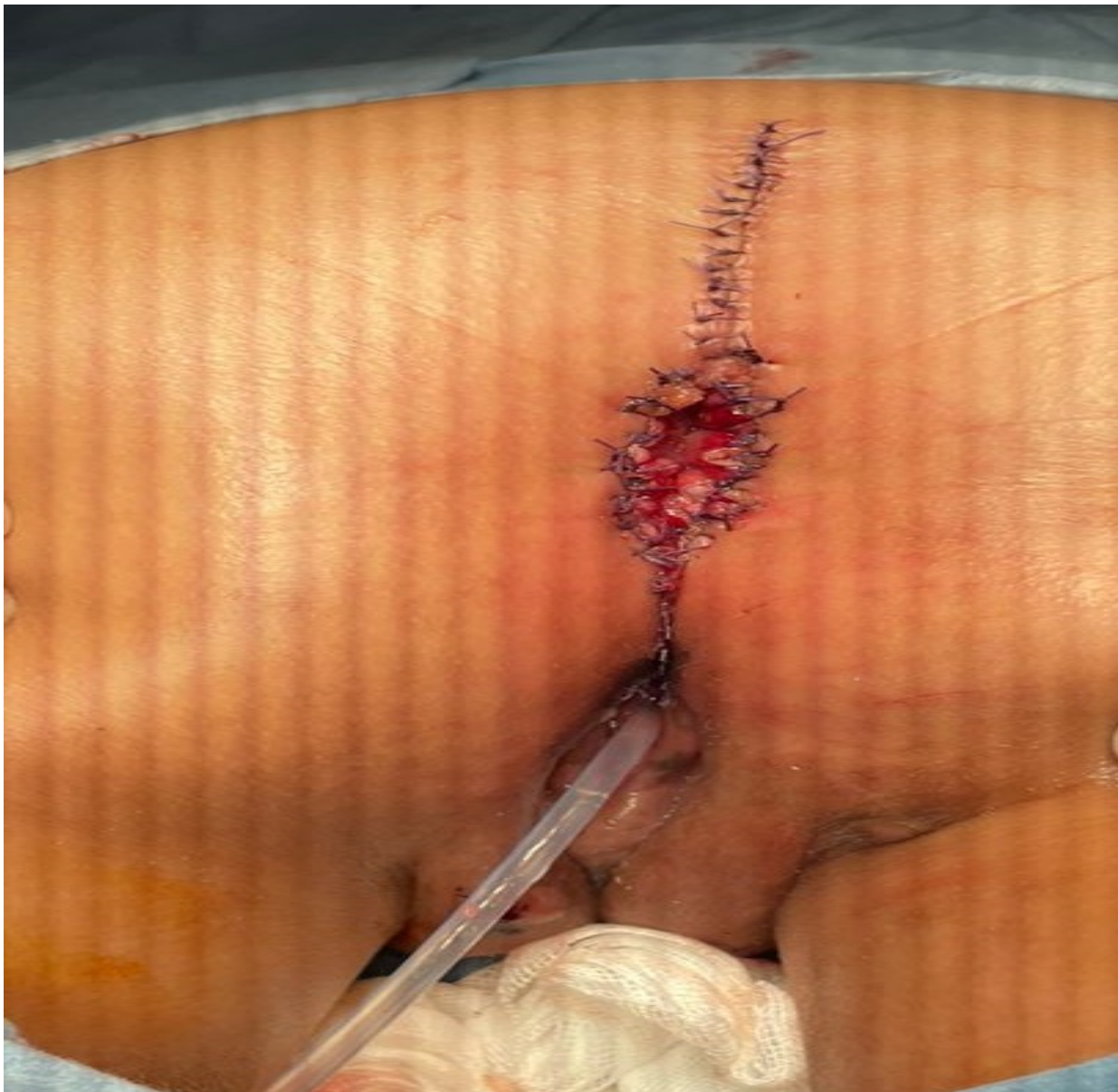## QUESTION 2

- What is the goal for the vaginal replacement?
  - A) Sexual function
  - B) Capacity to procreate
  - C) I don't know



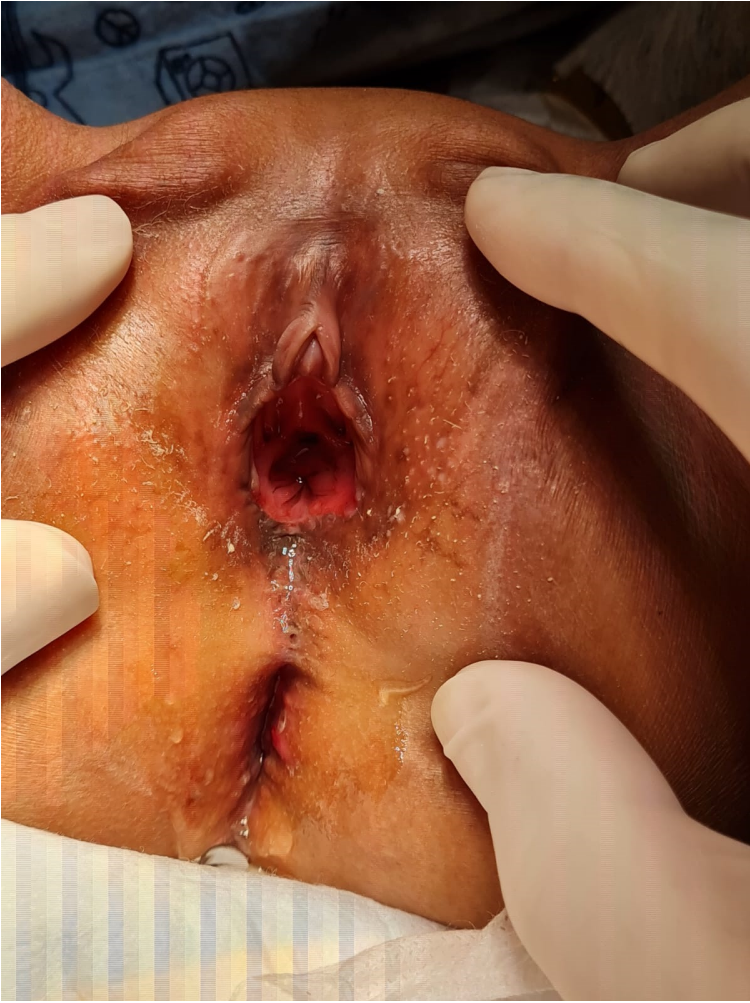







TWO MONTHS LATER



# THANK YOU

MR

