



COLORECTAL MEETING

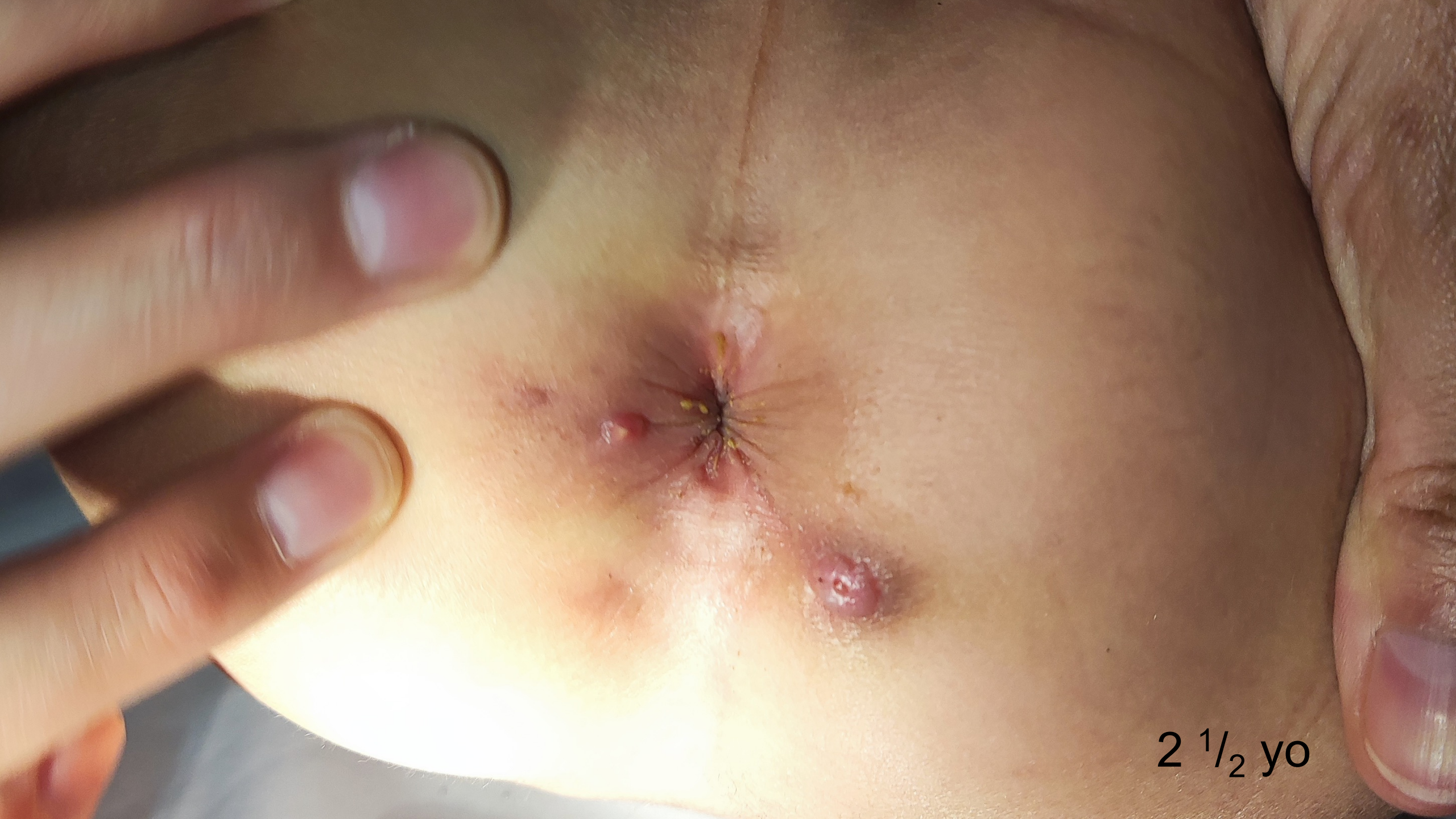PATIENT CASE

- **Gender:** male.
- **Age:** 3 years old
- **Original:** Puebla, México.

- Since 6 months old: repeated perianal abscess
- First consultation: 1 years and 4 month old

- Since 6 months old: repeated perianal abscess
- First consultation: 1 years and 4 month old
 - Expectant management

- Since 6 months old: repeated perianal abscess
- First consultation: 1 years and 4 month old
 - Expectant management
- 2 years and 6 month old: repeated perianal abscess



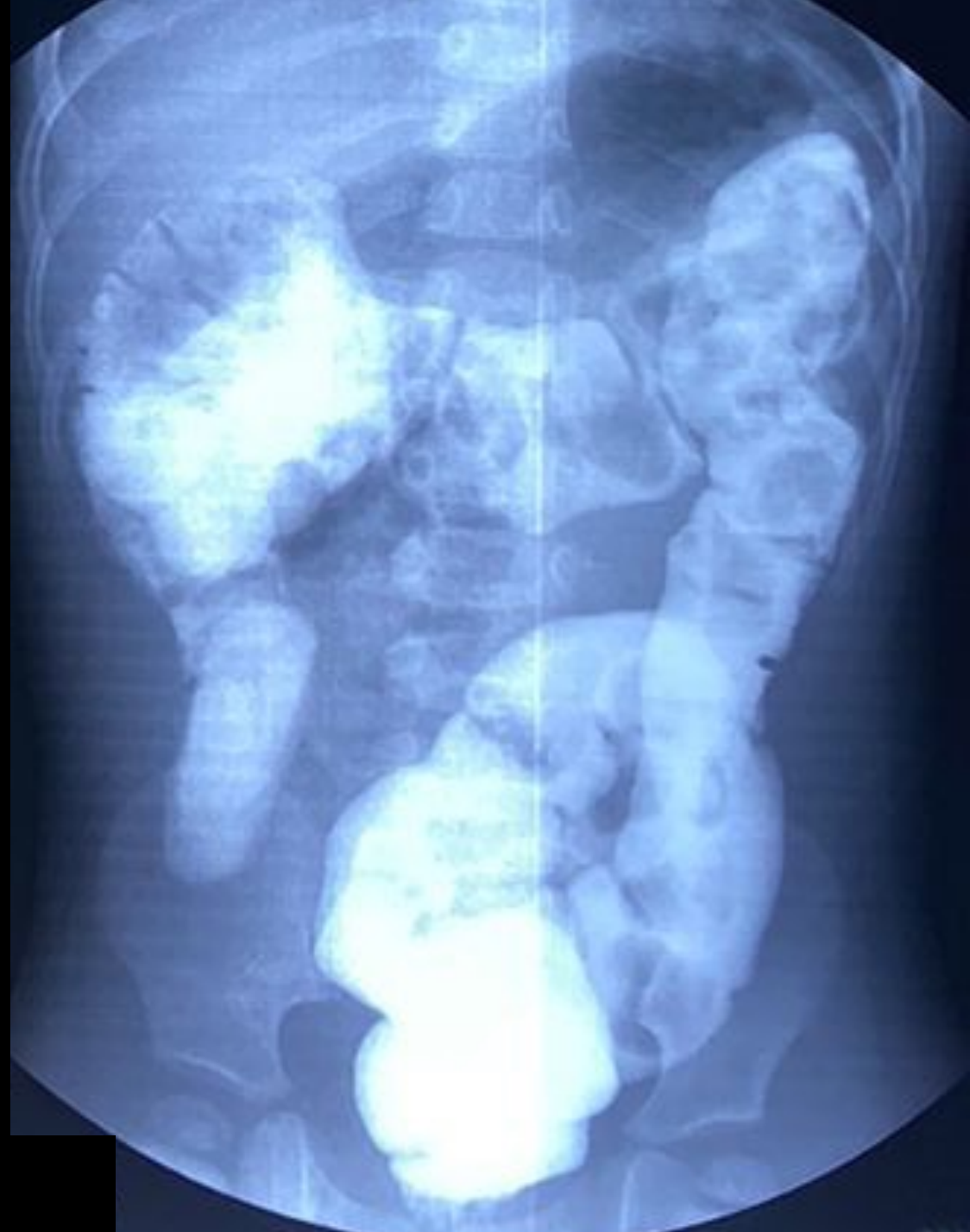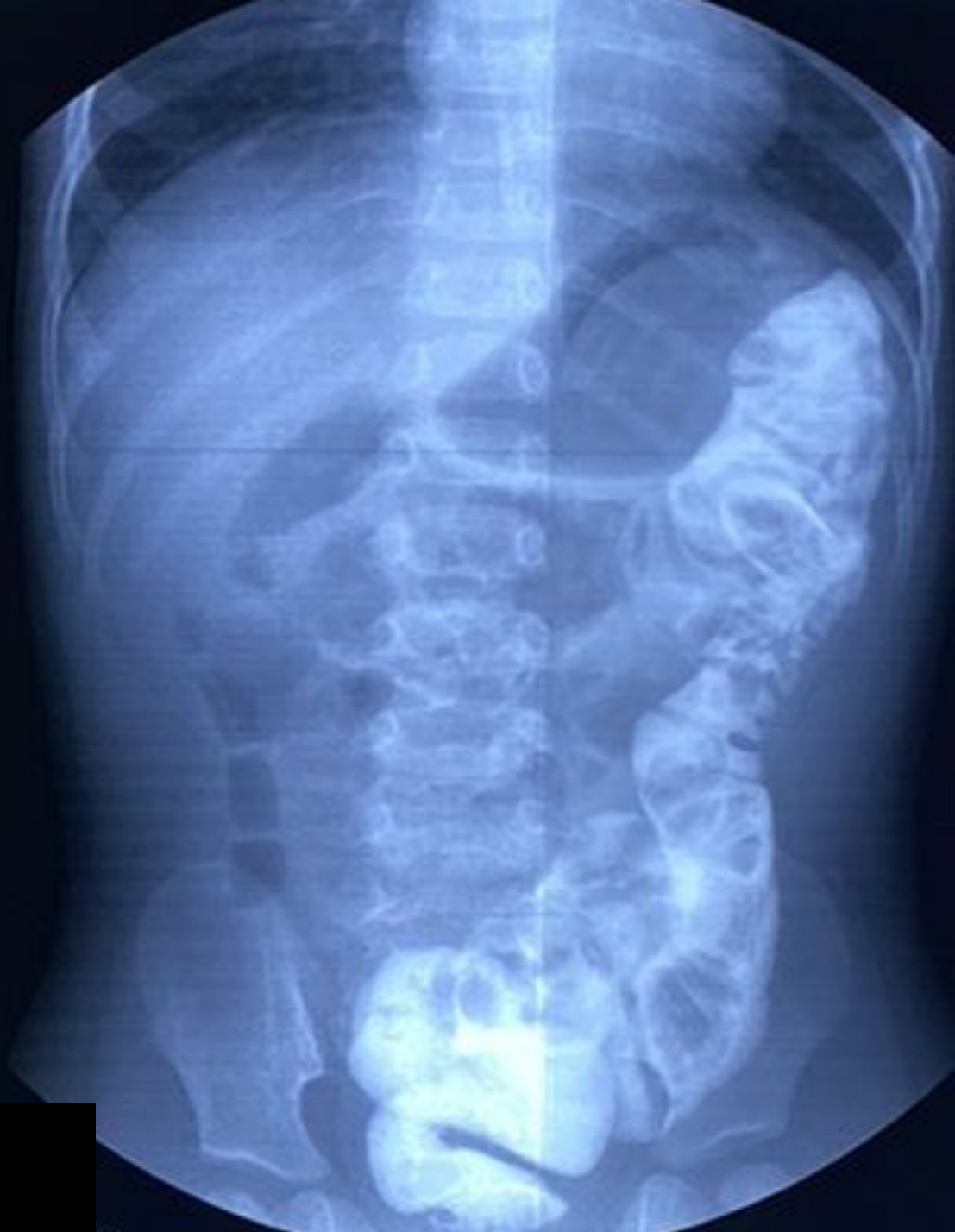2 1/2 yo

Laboratory testing

- **CBC**

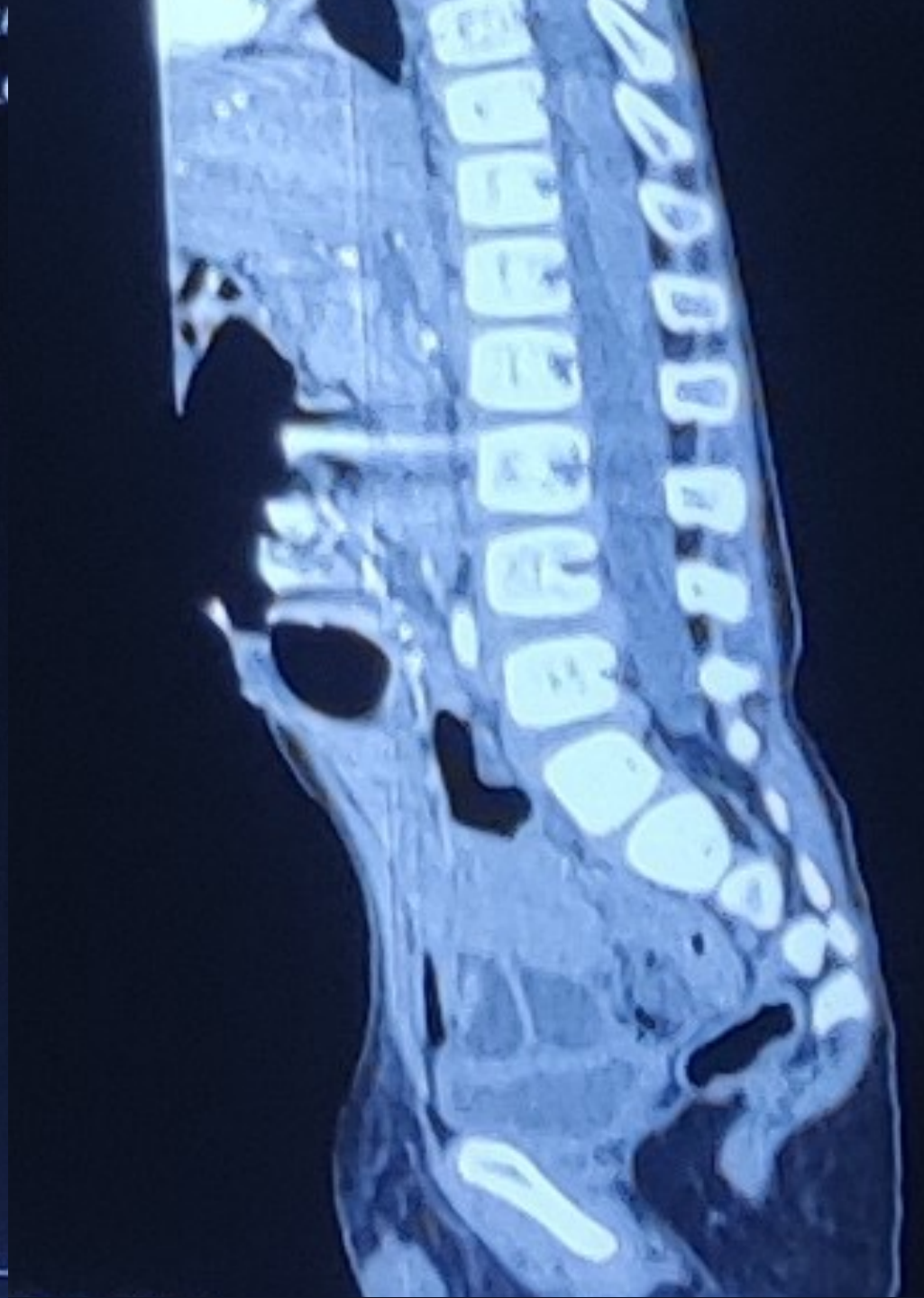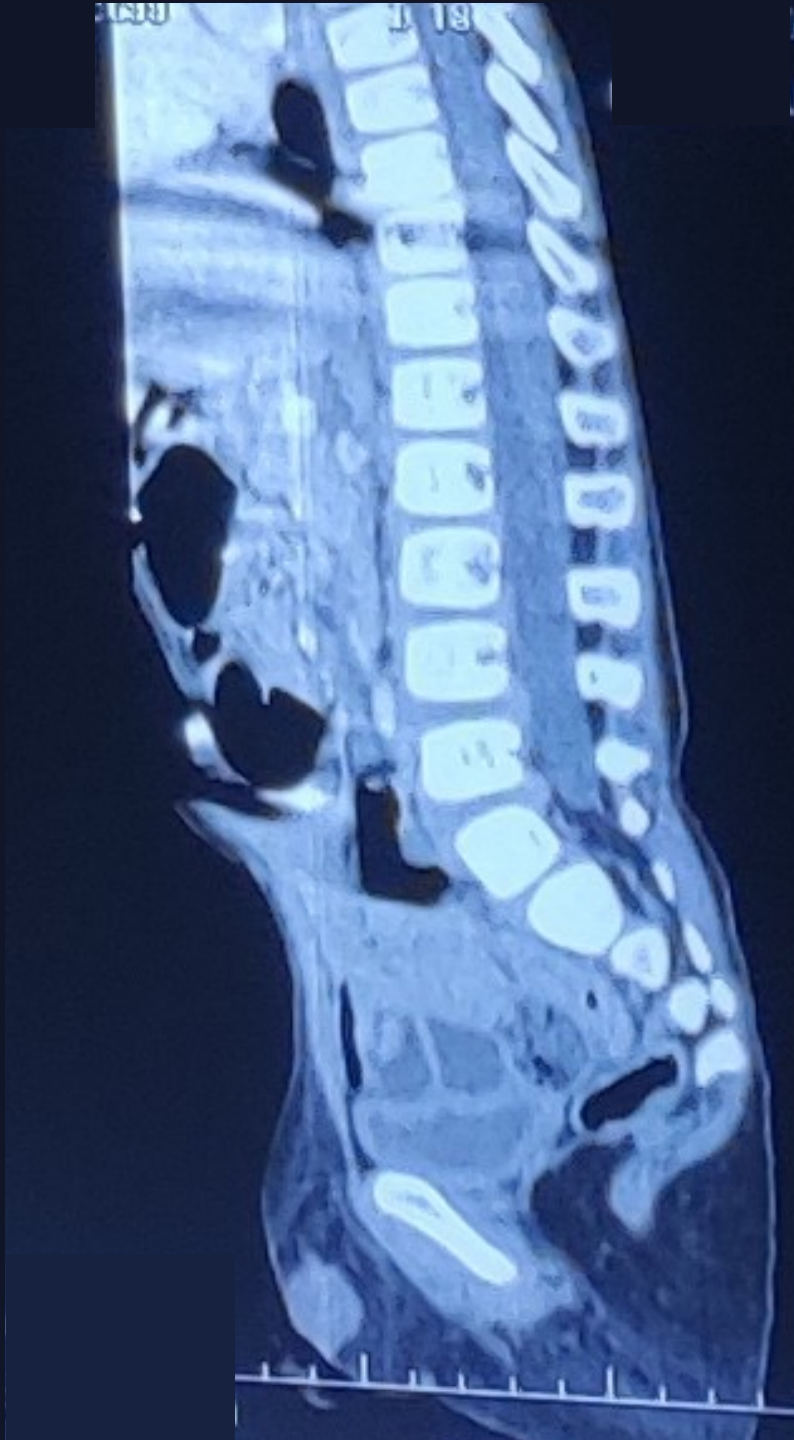- Hematocrit 40%
- Hemoglobin 13.2
- Leukocytes: 8500
- Neutrophils: 2400
- Immature blood cells (-)
- Platelets 226,000

- **C-reactive protein (-)**



CT scan

Ruled out presacral
mass



Gastroenterology evaluation

- Oral ulcers
- CBC y CRP normal
- Calprotectin

Gastroenterology evaluation

- Oral ulcers
- CBC y CRP normal
- Calprotectin (+)

Gastroenterology evaluation

- Oral ulcers
 - CBC y CRP normal
 - Calprotectin (+)
 - Upper and lower endoscopy
-
- Antibodies:

Gastroenterology evaluation

- Oral ulcers
- CBC y CRP normal
- Calprotectin (+)
- Upper and lower endoscopy
 - Upper: normal
 - Colonoscopy: right colitis, not suggestive of IBD.
- Antibodies:

Gastroenterology evaluation

- Oral ulcers
- CBC y CRP normal
- Calprotectin (+)
- Upper and lower endoscopy
 - Upper: normal
 - Colonoscopy: right colitis, not suggestive of IBD. Histopathology IBD (-)
- Antibodies:

Gastroenterology evaluation

- Oral ulcers
- CBC y CRP normal
- Calprotectin (+)
- Upper and lower endoscopy
 - Upper: normal
 - Colonoscopy: right colitis, not suggestive of IBD. Histopathology IBD (-)
- Antibodies: ANCA y ASCA (-)

Gastroenterology evaluation

- Oral ulcers
- CBC y CRP normal
- Calprotectin (+)
- Upper and lower endoscopy
 - Upper: normal
 - Colonoscopy: right colitis, not suggestive of IBD. Histopathology IBD (-)
- Antibodies: ANCA y ASCA (-)

**gastroenterology
discharge**

Immunology evaluation

- Family history of immunodeficiency
- CBC

Immunology evaluation

- Family history of immunodeficiency (-)
- CBC Normal

Immunology evaluation

- Family history of immunodeficiency (-)
- CBC Normal
- Subpopulation of B and T lymphocytes
- Complement C3 and C4
- Immunoglobulins IgA, IgM, IgE
- Antibodies against S pneumoniae 14 serotypes
- HIV

Immunology evaluation

- Family history of immunodeficiency (-)
- CBC Normal
- Subpopulation of B and T lymphocytes NORMAL
- Complement C3 and C4 NORMAL
- Immunoglobulins IgA, IgM, IgE NORMAL
- Antibodies against S pneumoniae 14 serotypes
- HIV

Immunology evaluation

- Family history of immunodeficiency (-)
- CBC Normal
- Subpopulation of B and T lymphocytes NORMAL
- Complement C3 and C4 NORMAL
- Immunoglobulins IgA, IgM, IgE NORMAL
- Antibodies against *S pneumoniae* 14 serotypes (-)
- HIV (-)

Immunology evaluation

- Family history of immunodeficiency (-)
- CBC normal
- Subpopulation of B and T lymphocytes NORMAL
- Complement C3 and C4 NORMAL
- Immunoglobulins IgA, IgM, IgE NORMAL
- Antibodies against S pneumoniae 14 serotypes (-)
- HIV (-)

- **Plan: PNEUMOCOCCUS VACCINE 23 SEROTYPES
(PULMOVAX®)**

Immunology evaluation

- Family history of immunodeficiency
- CBC normal
- Subpopulation of B and T lymphocytes NORMAL
- Complement C3 and C4 NORMAL
- Immunoglobulins IgA, IgM, IgE NORMAL
- Antibodies against S pneumoniae 14 serotypes (-)
- HIV (-)

- **Plan: PNEUMOCOCCUS VACCINE 23 SEROTYPES (PULMOVAX®)**

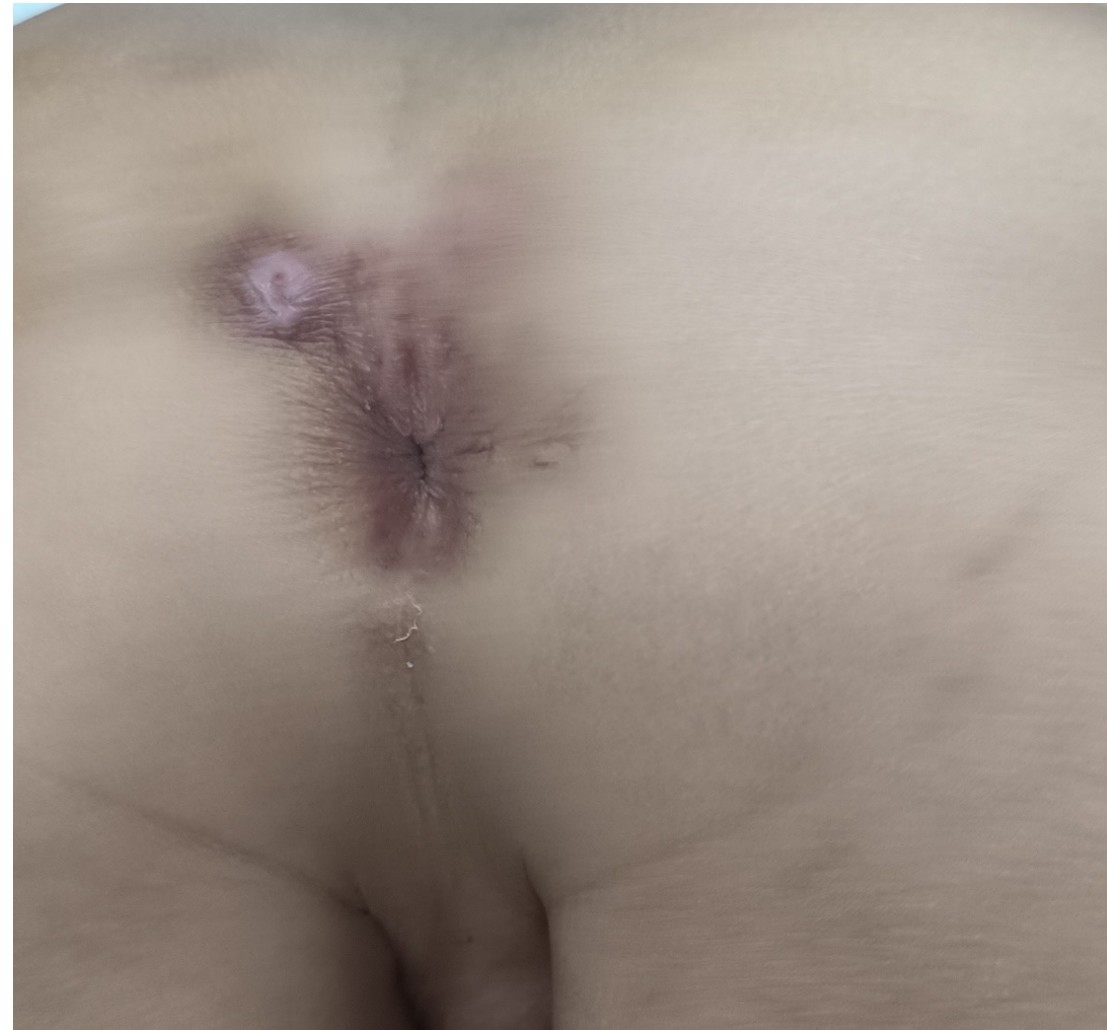**Immunology
discharge**

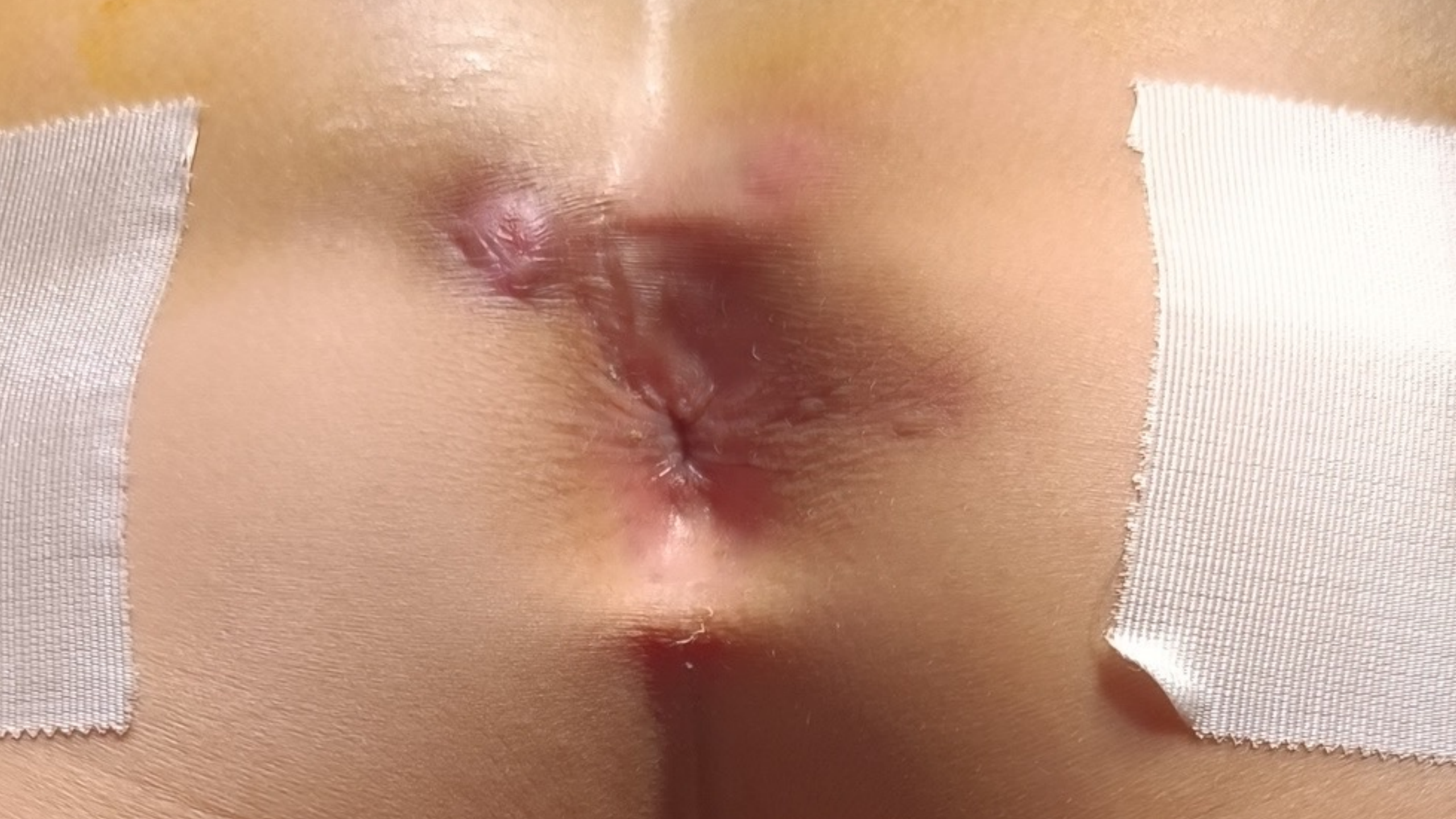- < 2 yo: 8 episodes
- 2 - 3 yo: episodes every 2 weeks.
 - local heat, sitz baths
 - spontaneous drainage
 - repeated courses of antibiotics

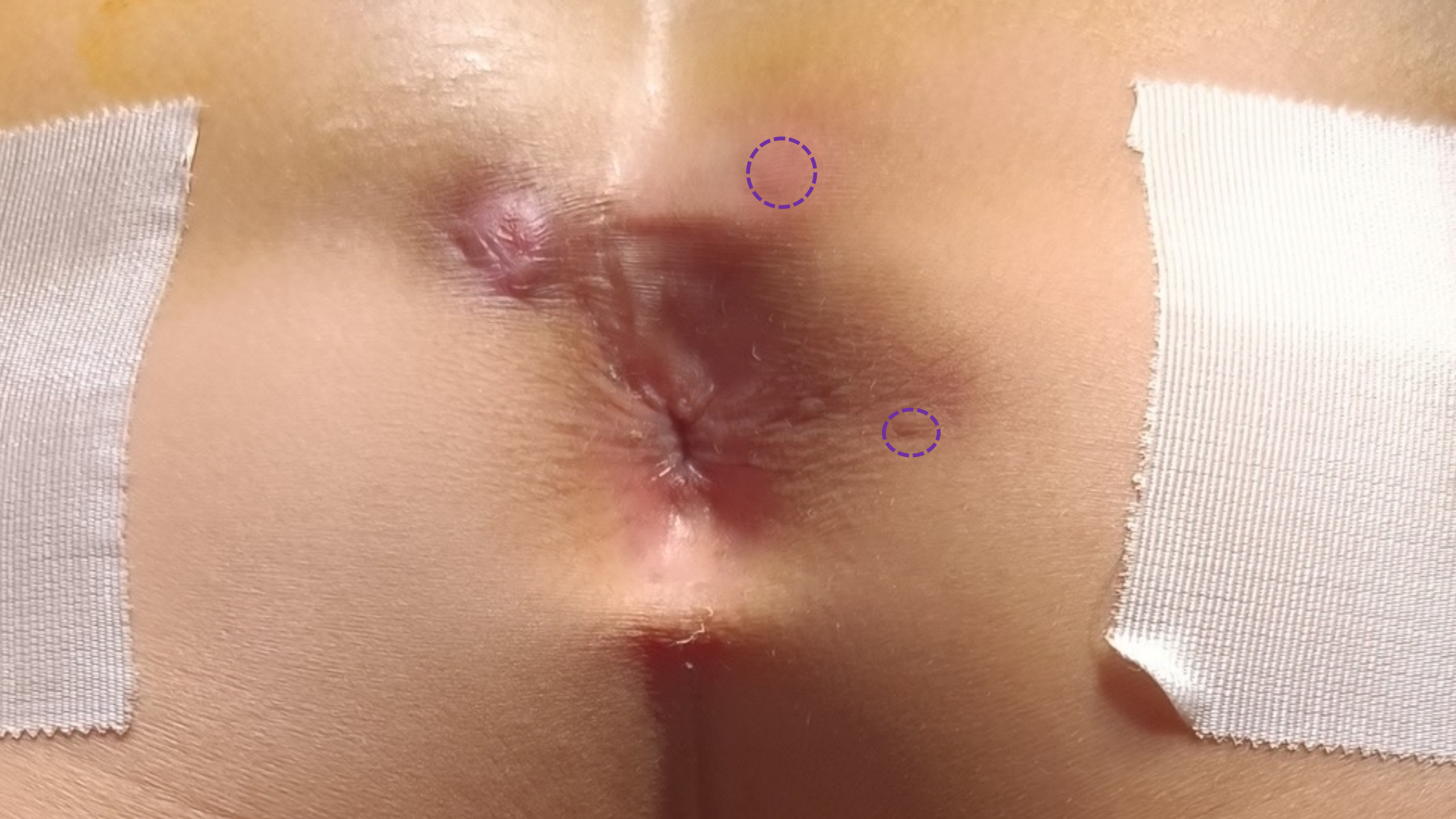
Surgical management

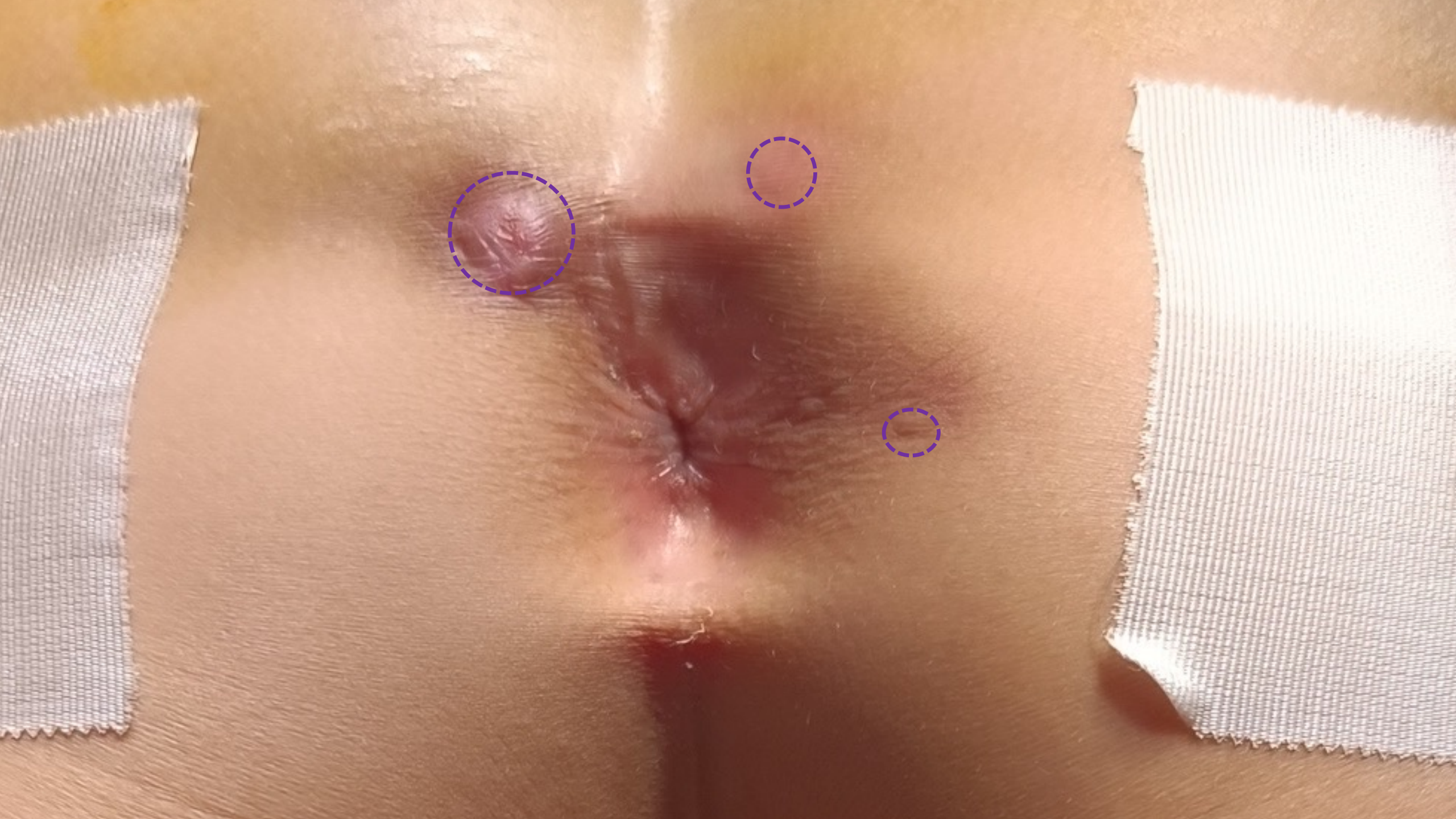
fistulotomy

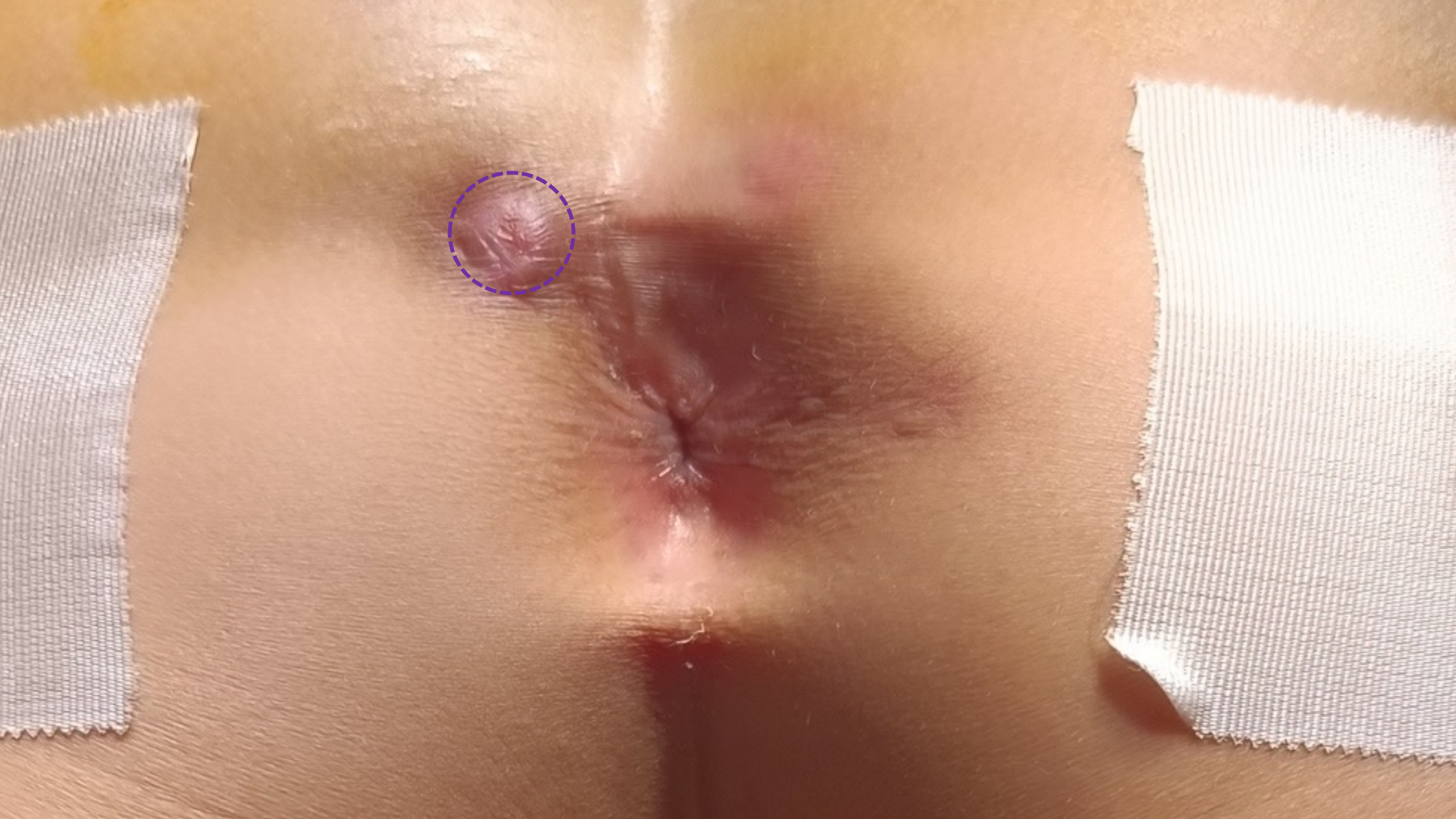
Preoperative

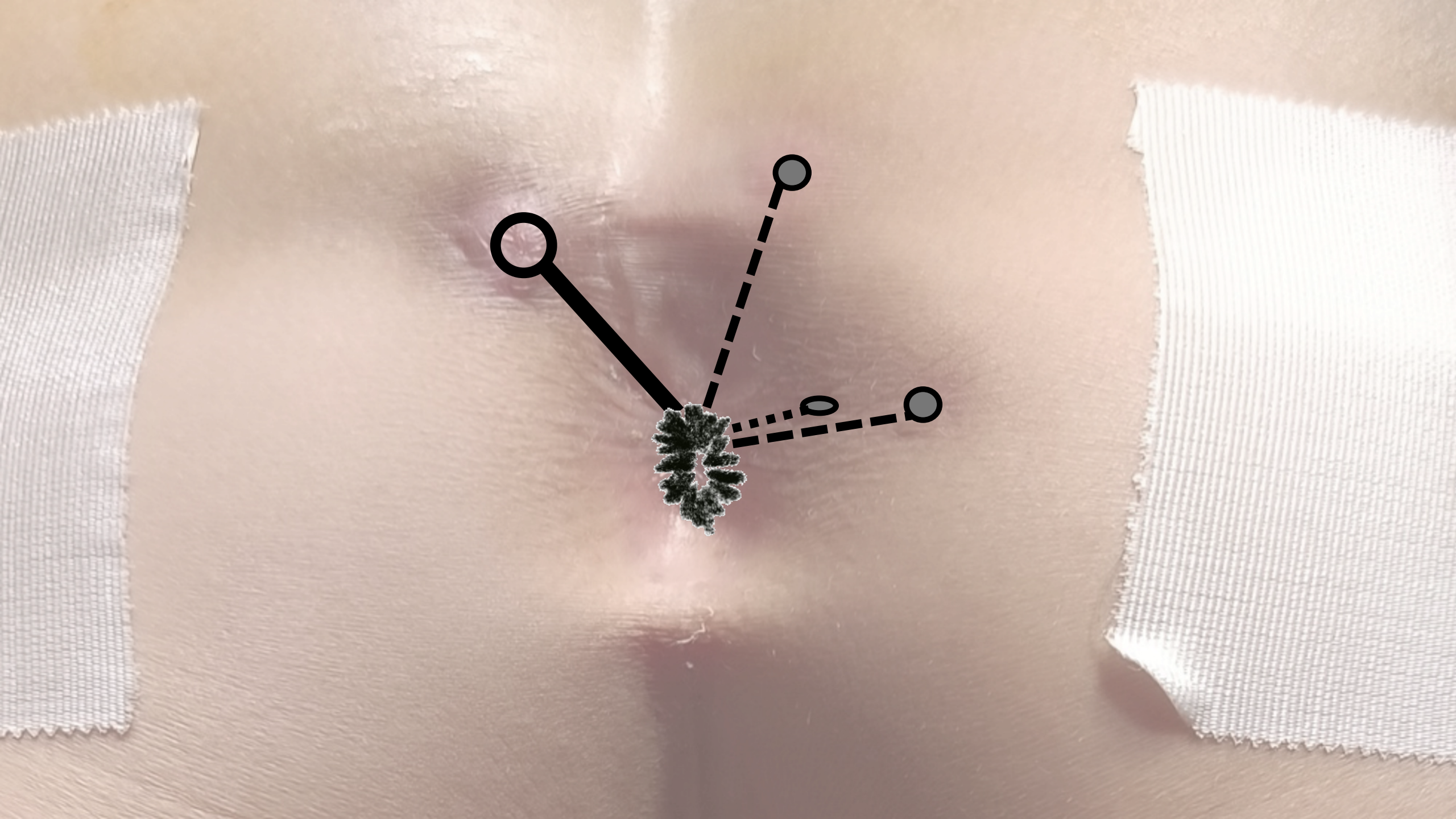


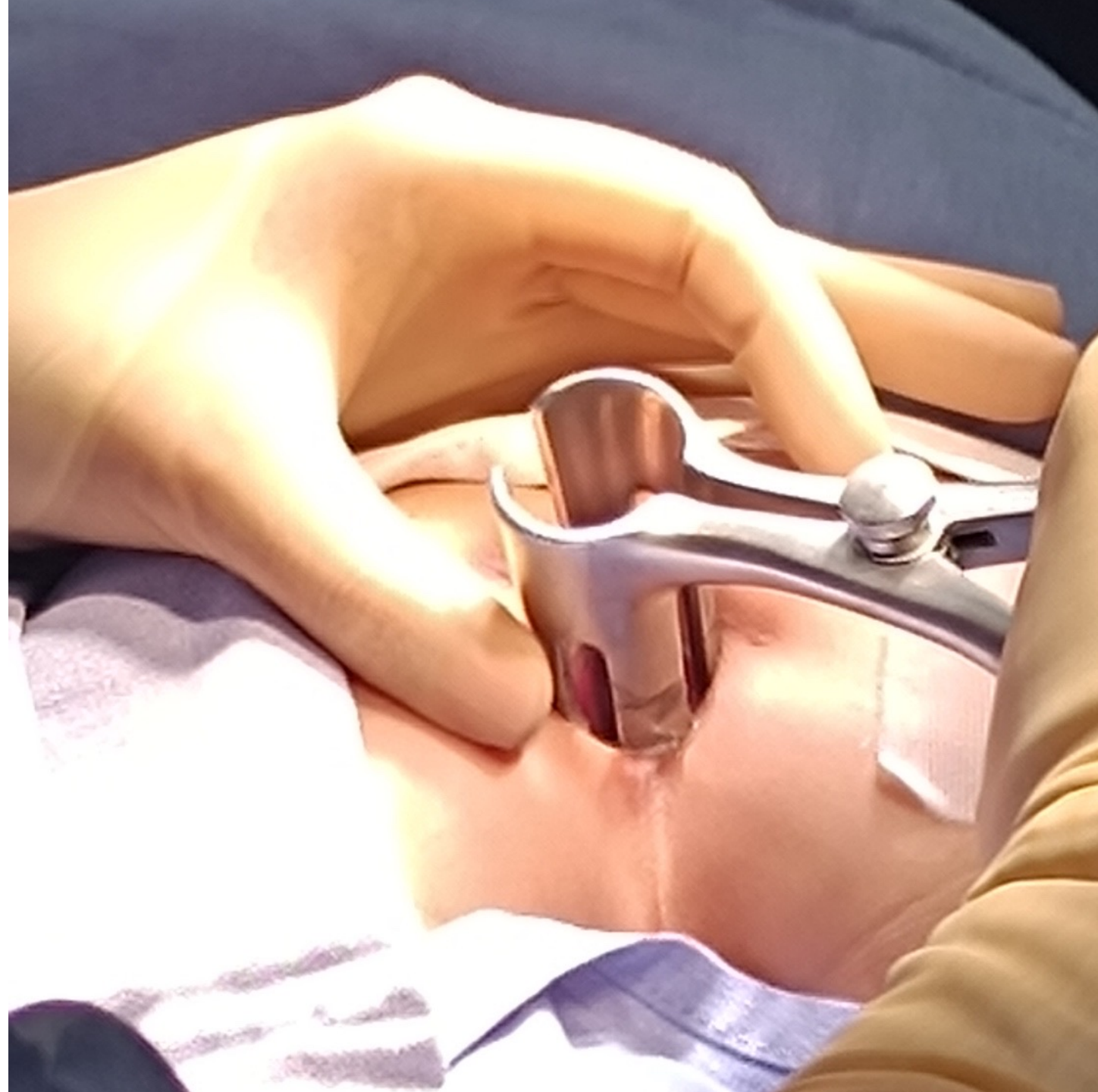


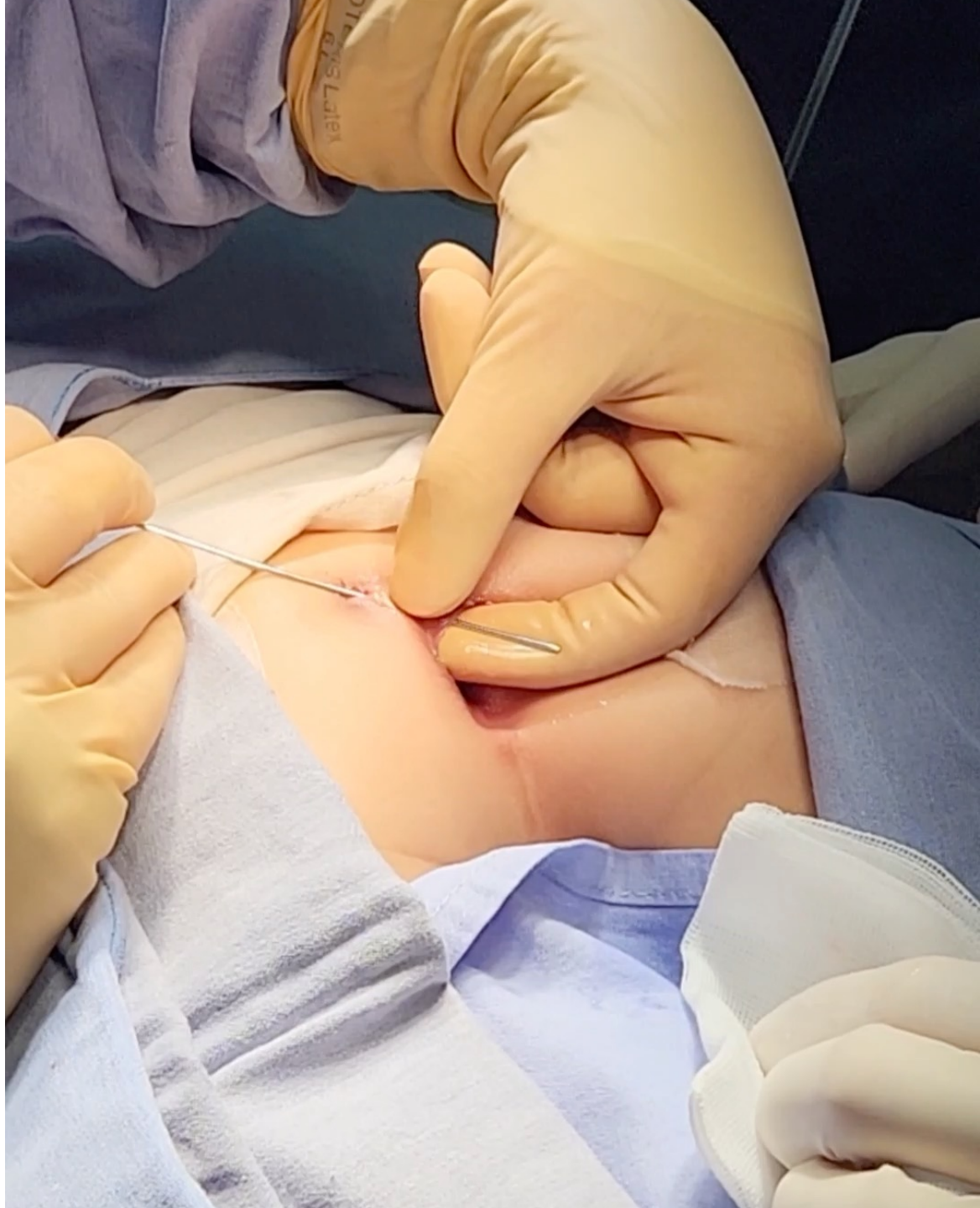
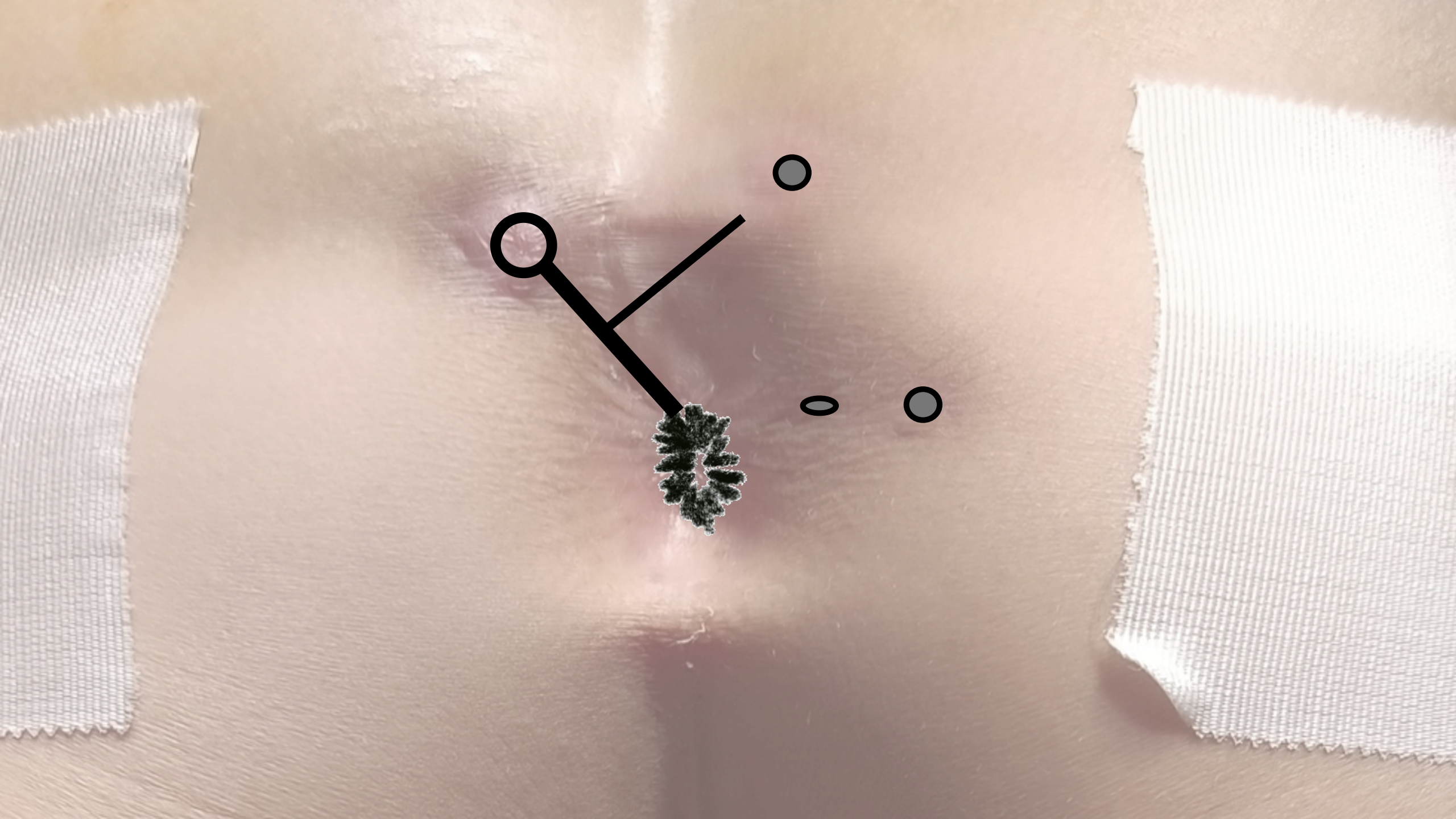


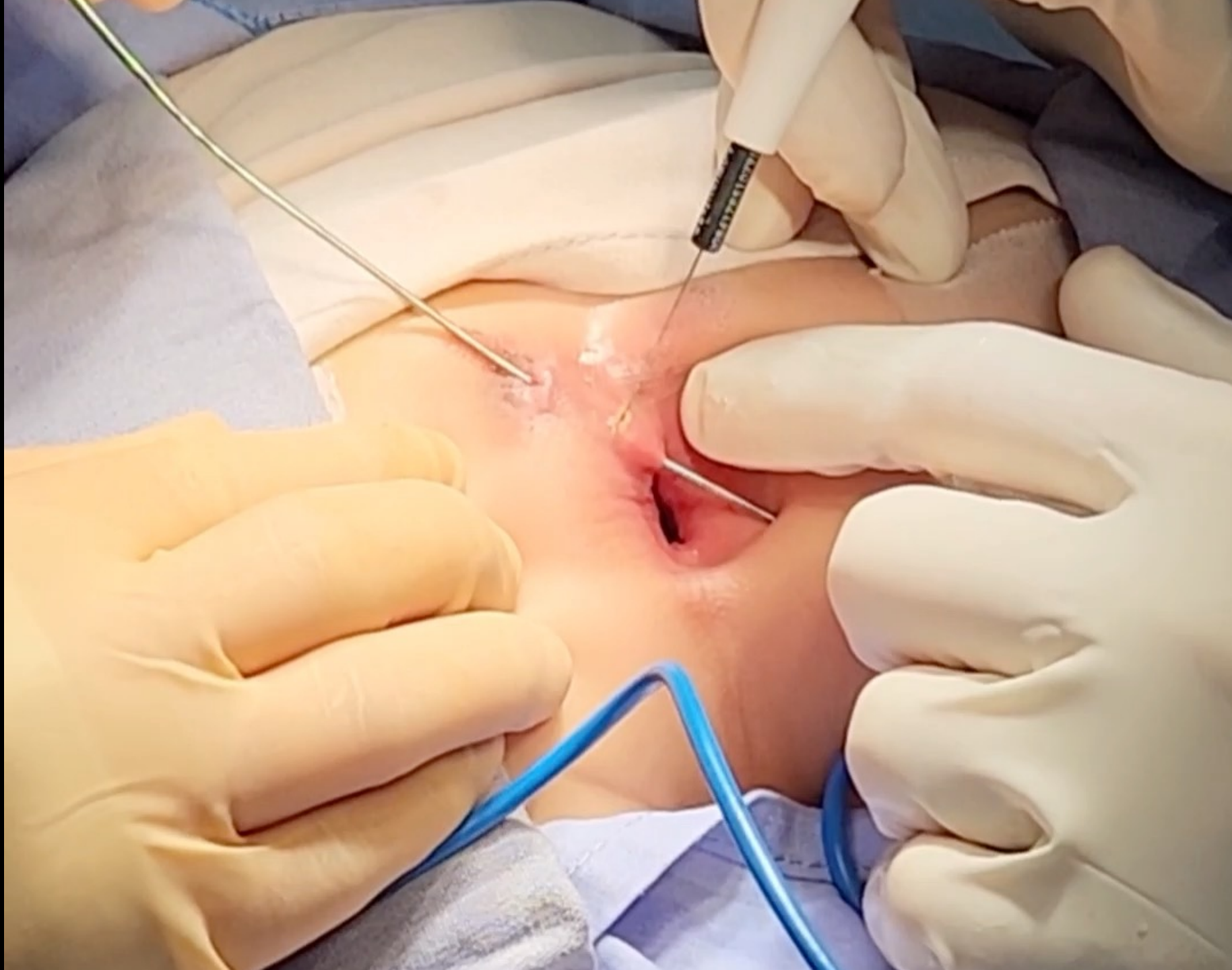




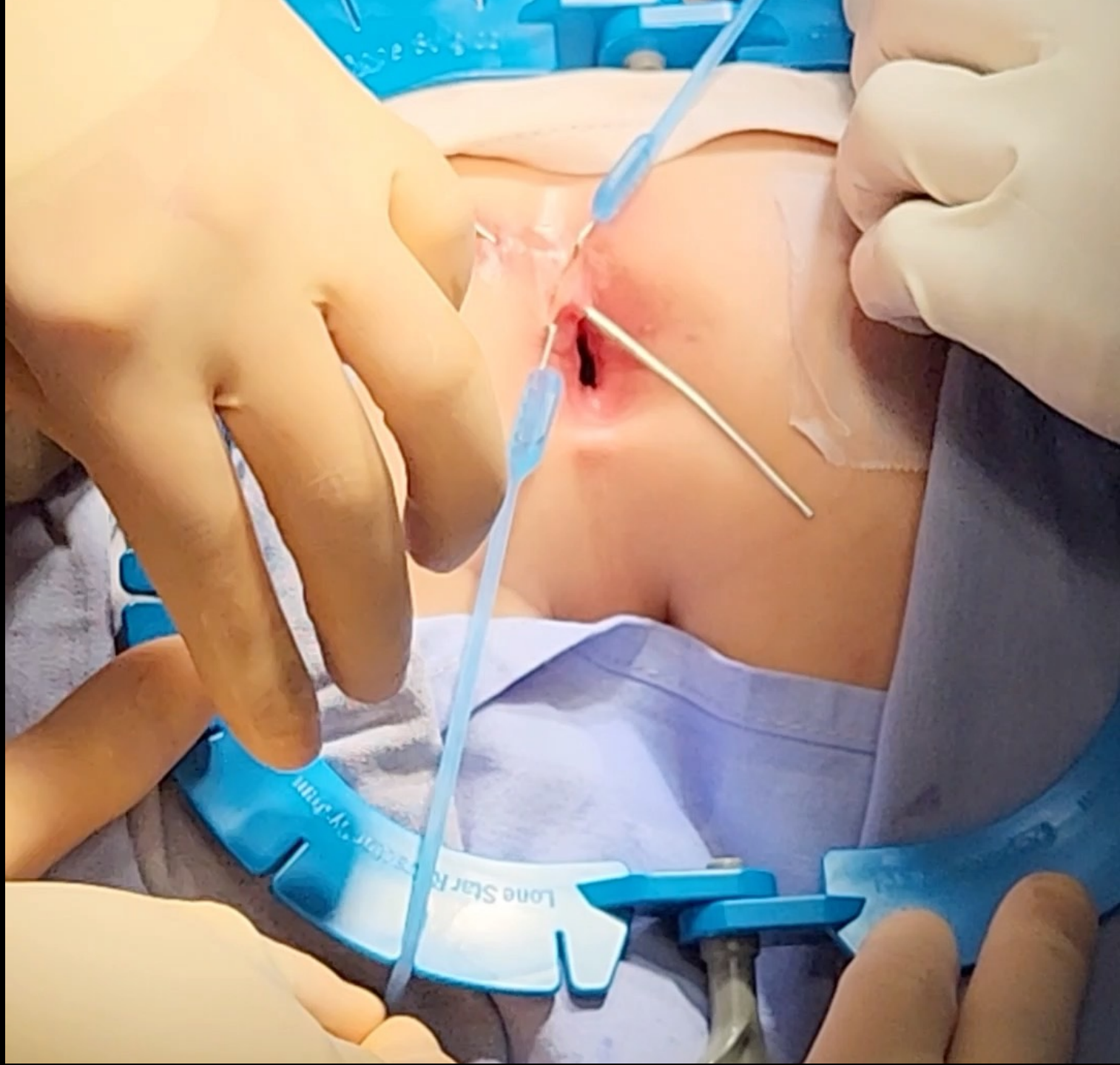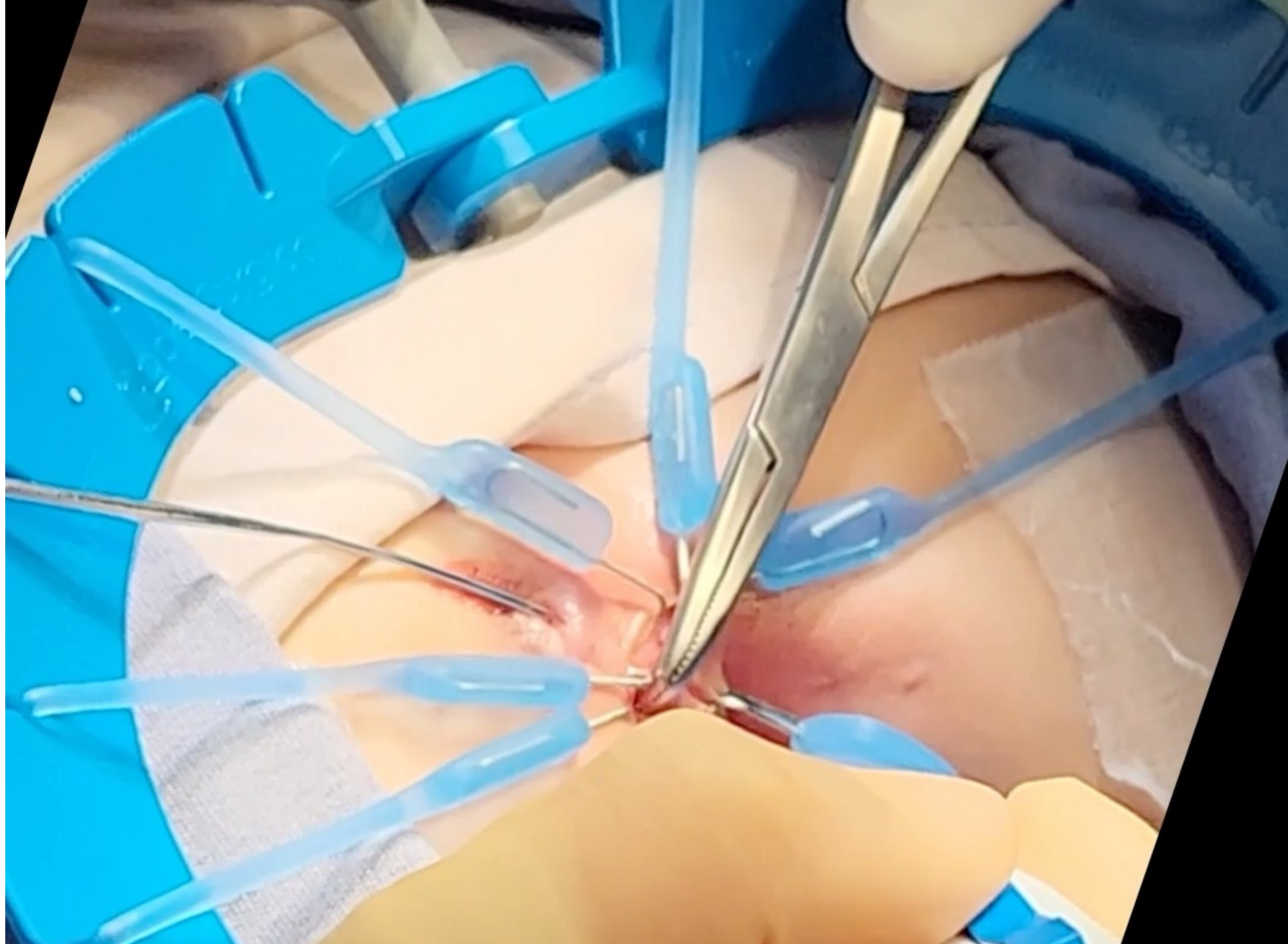


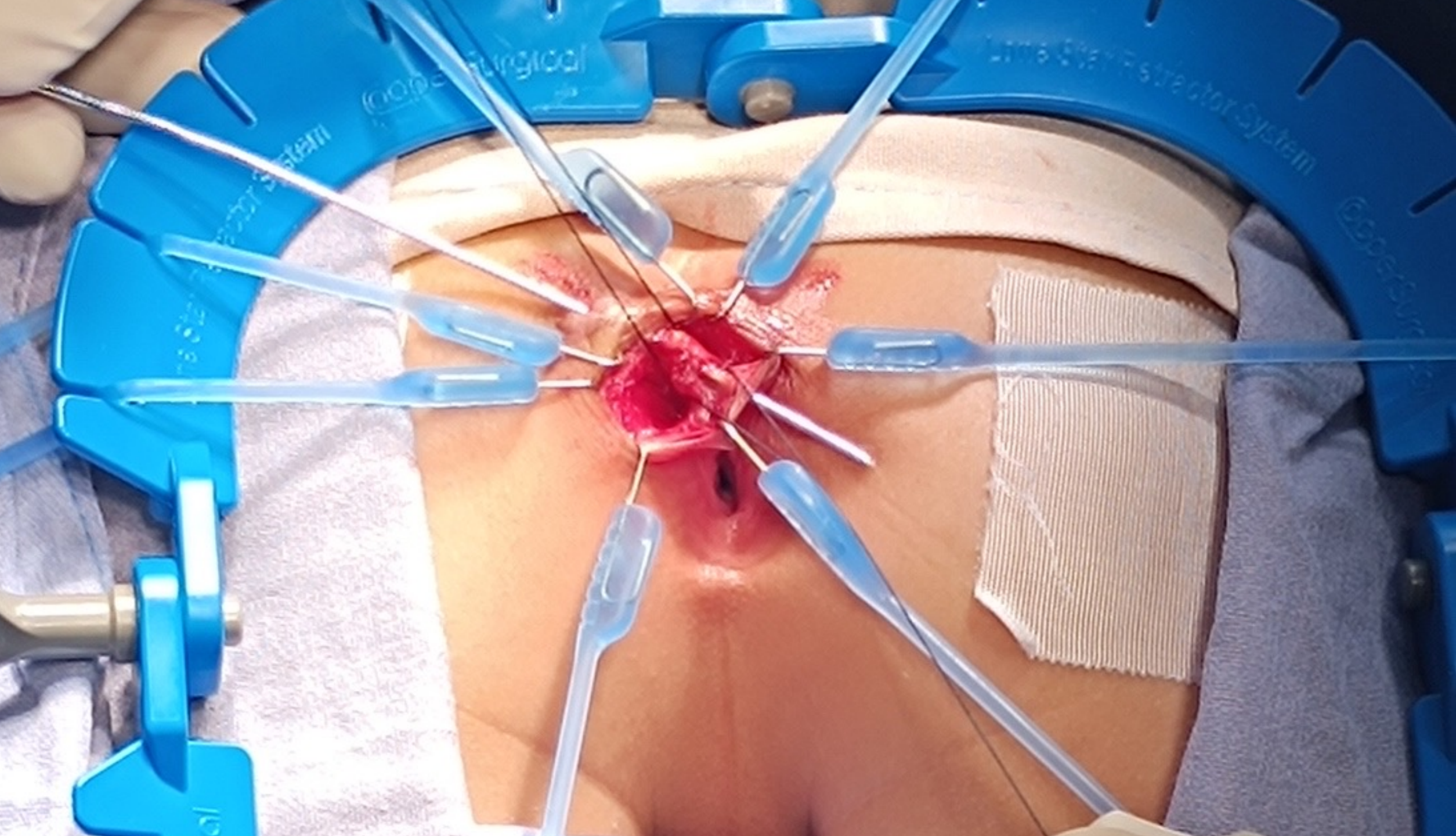


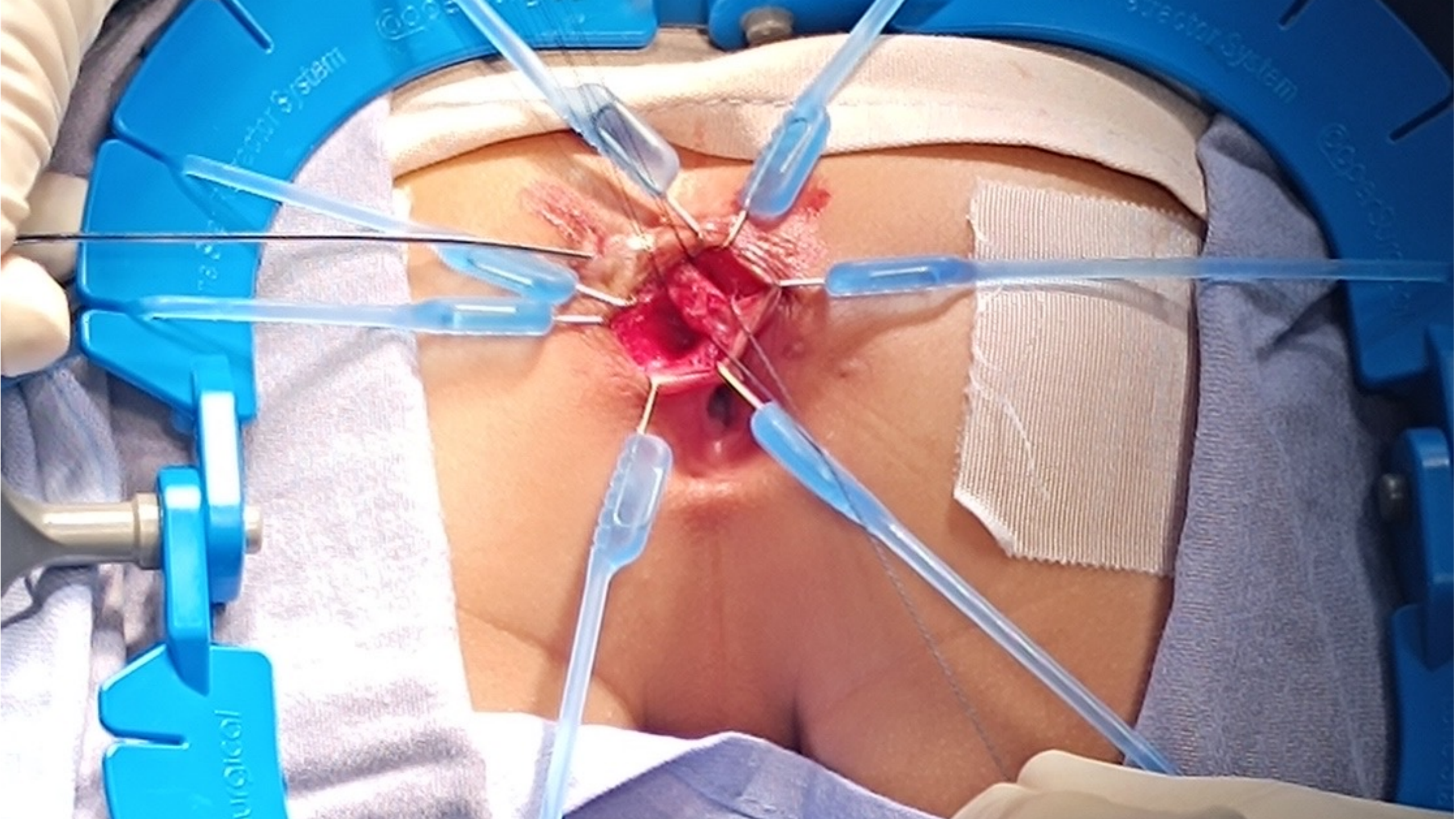


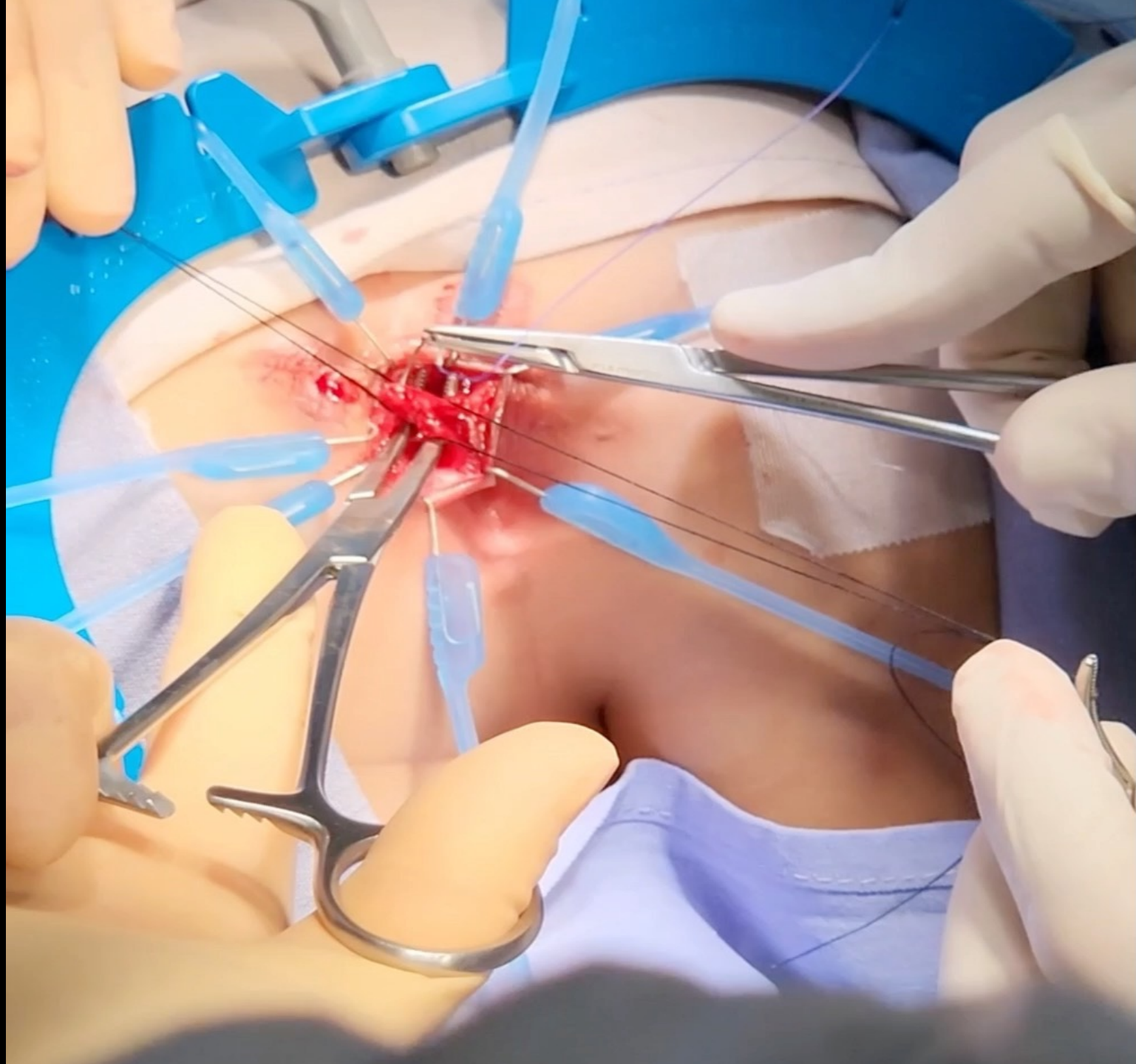


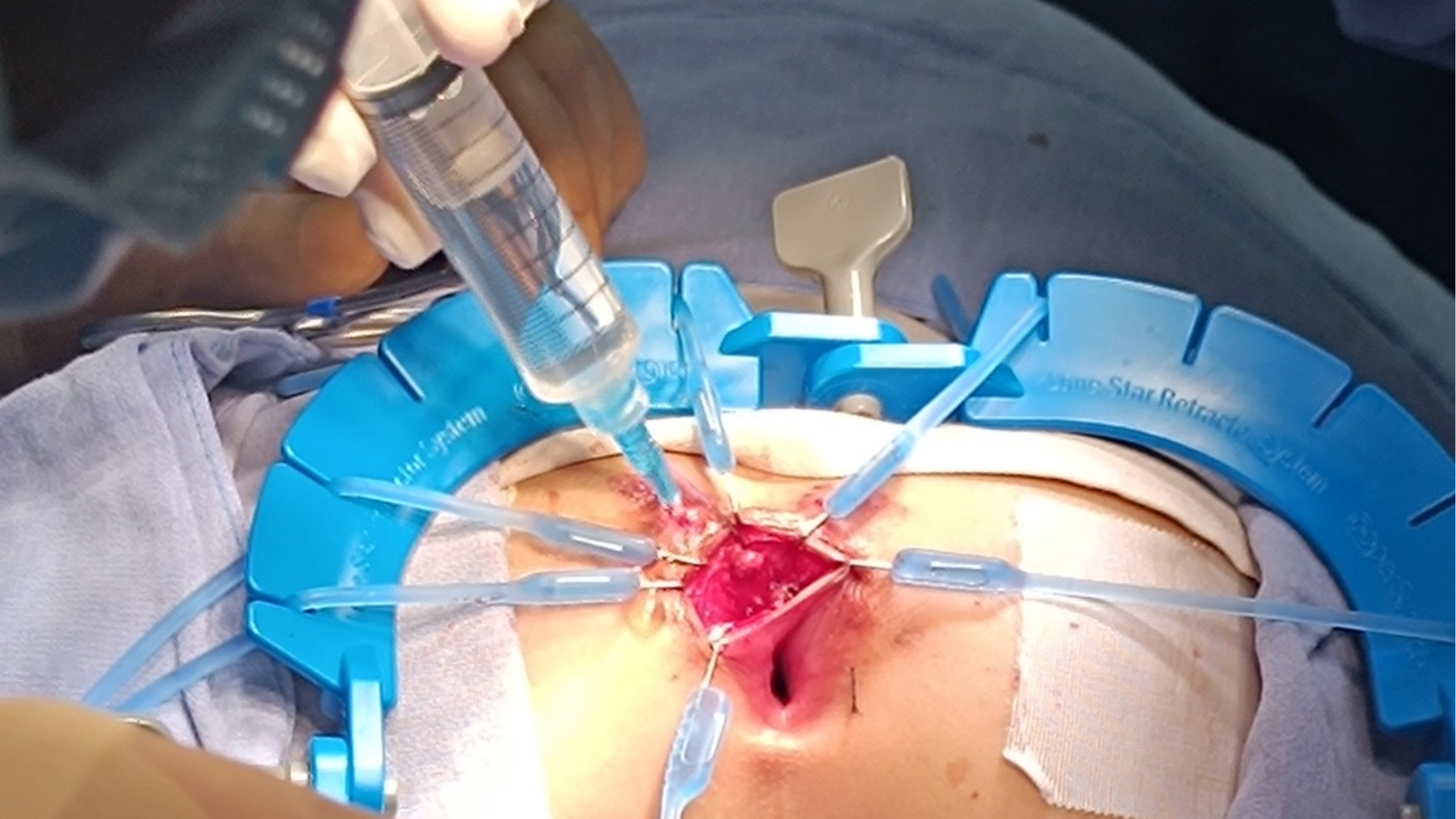


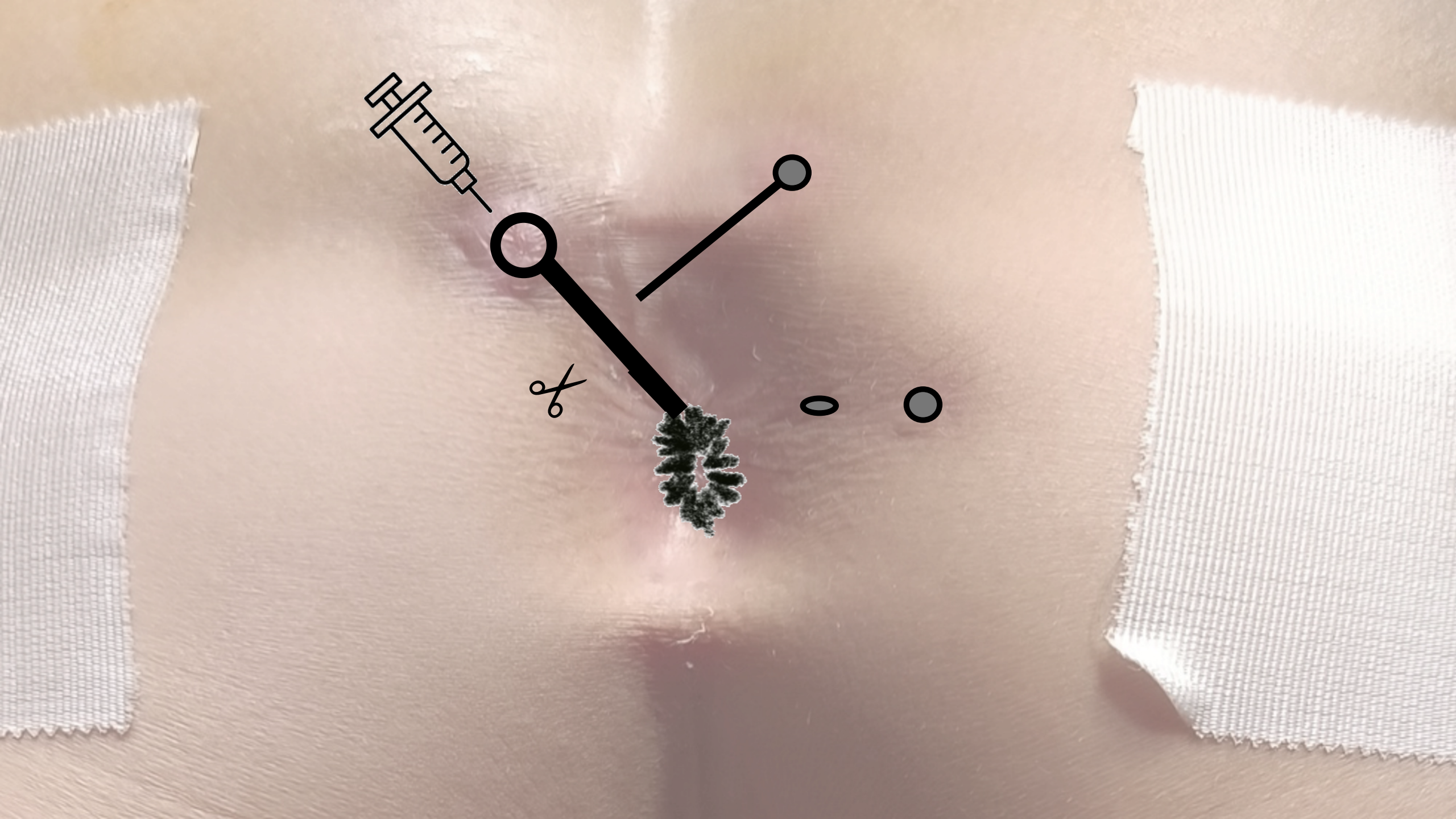


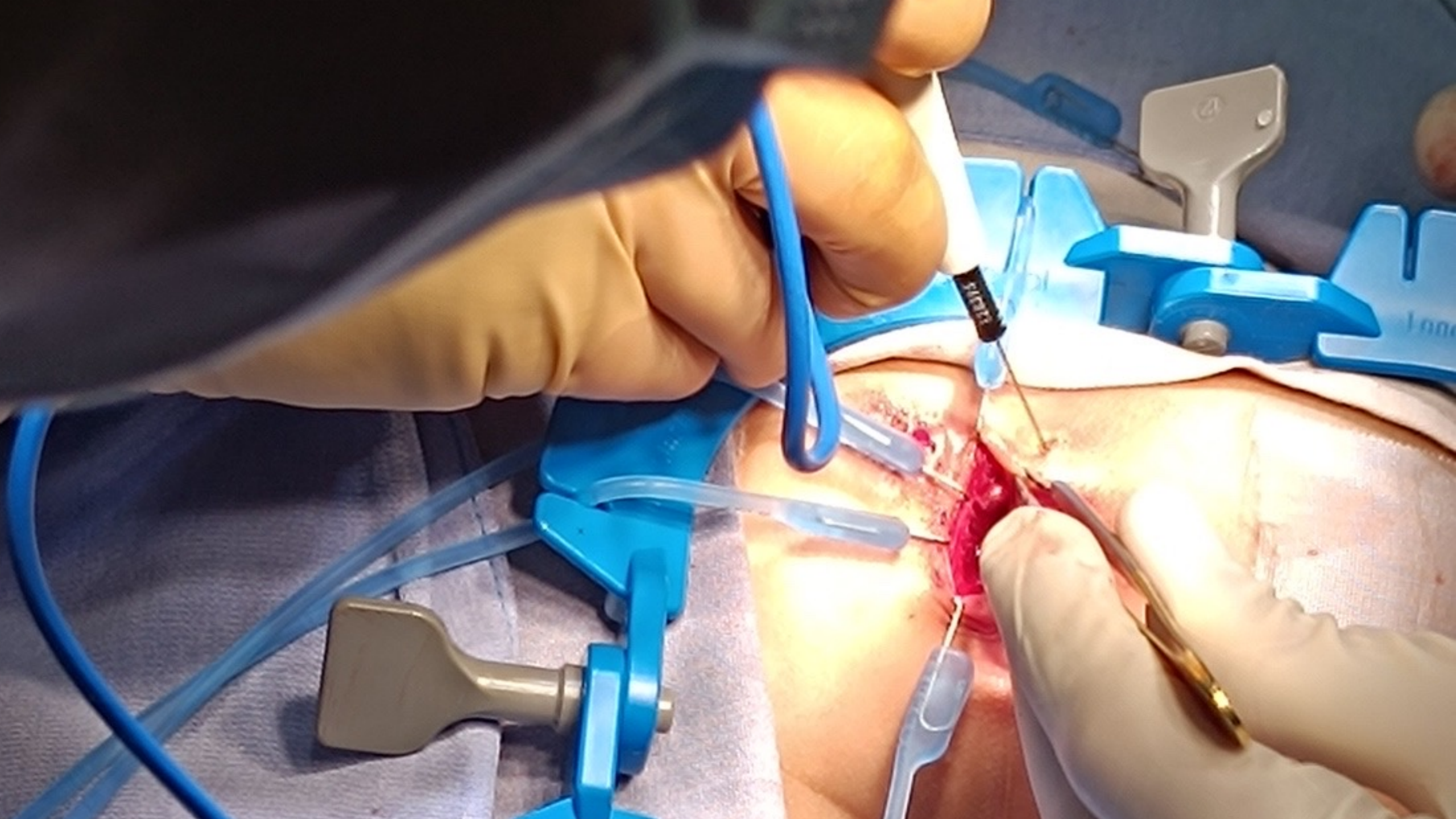




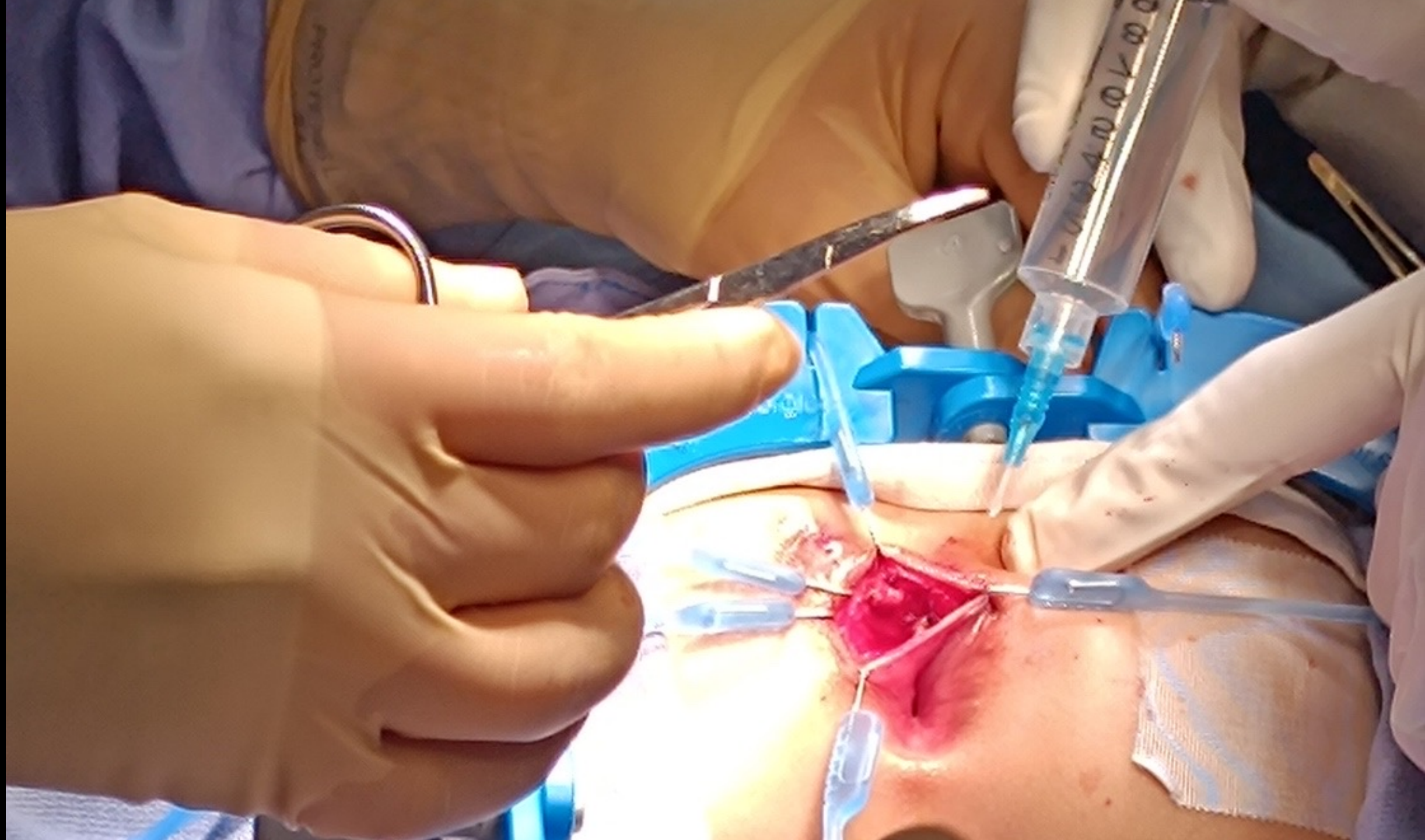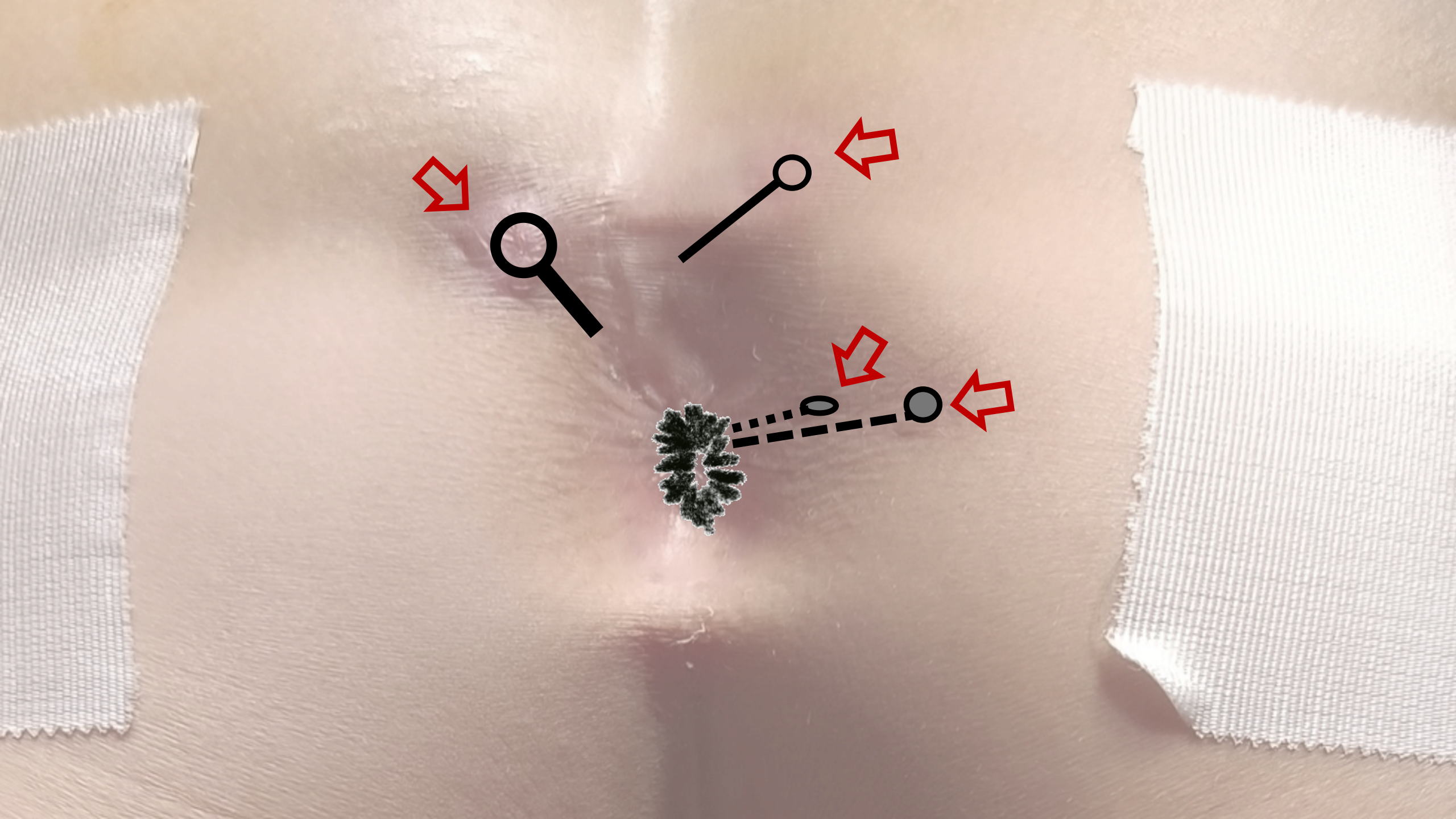


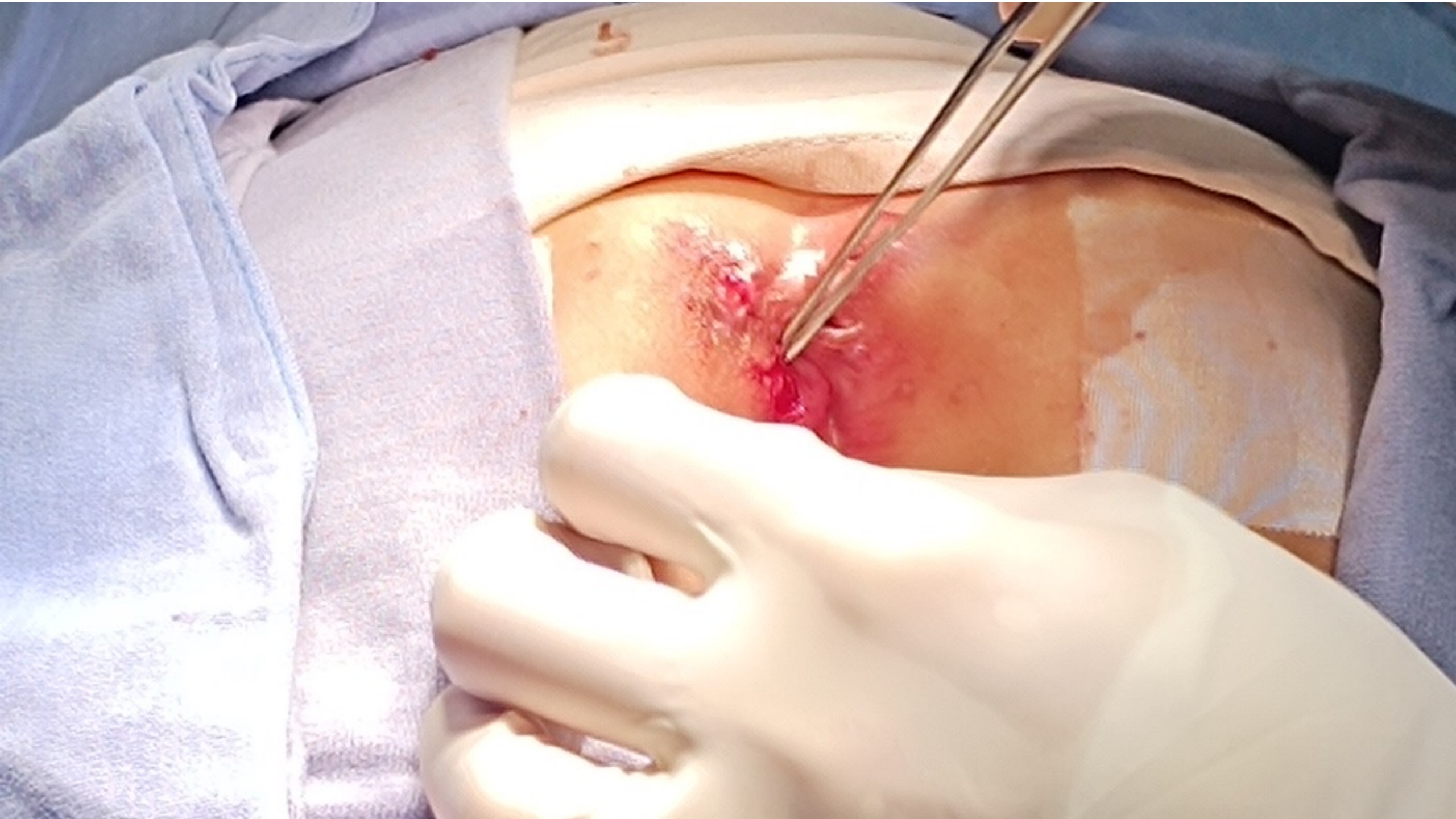


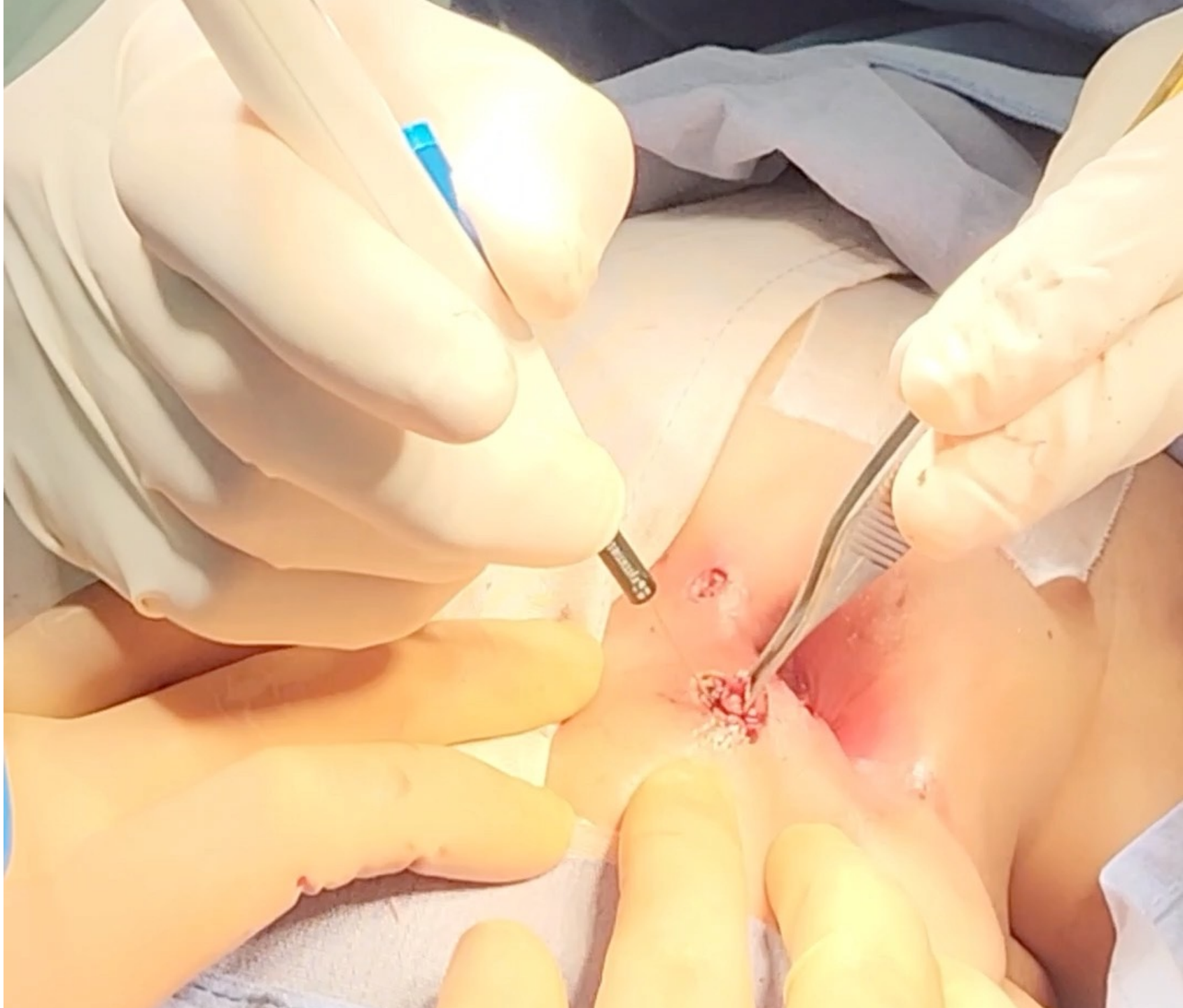




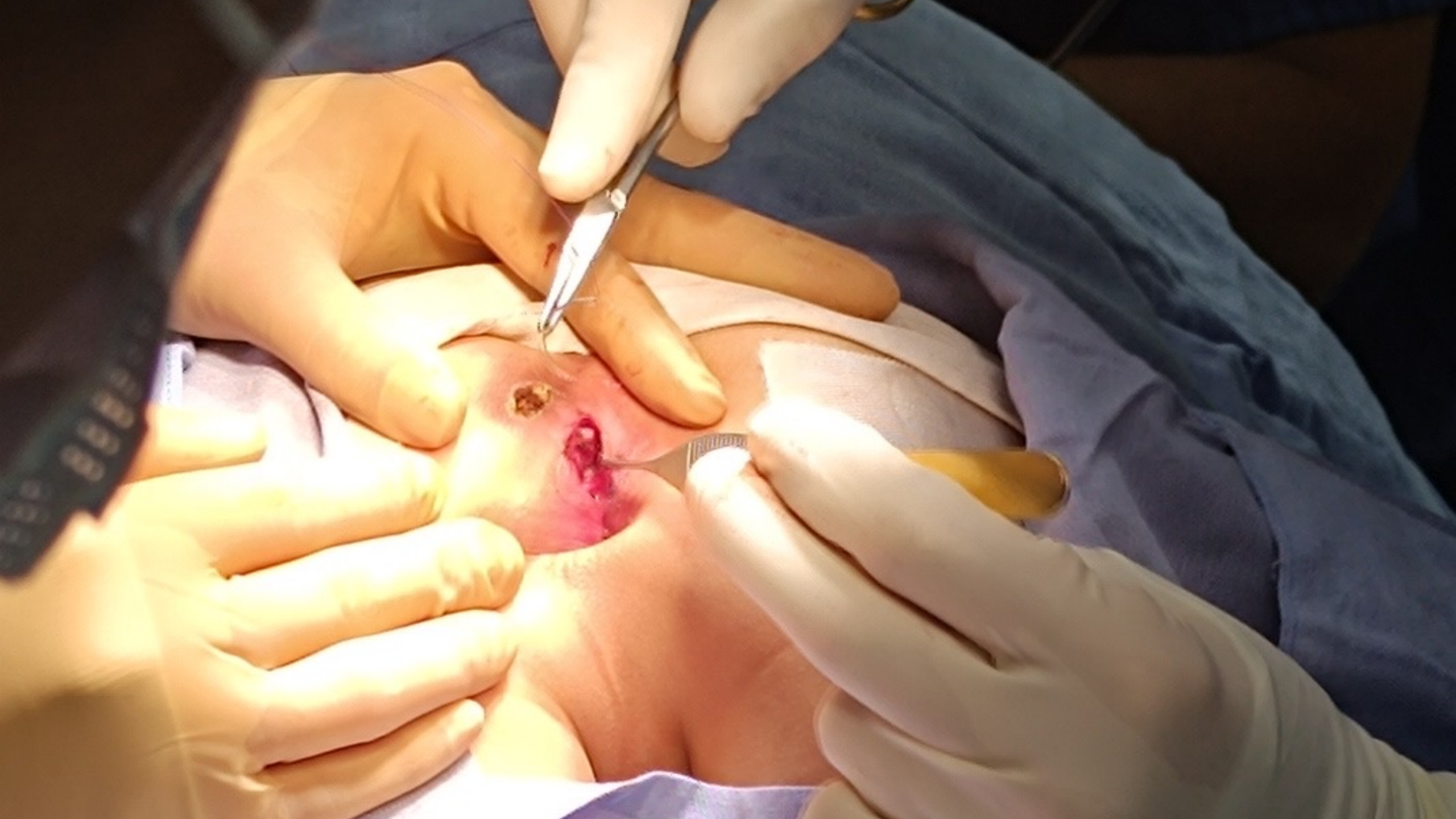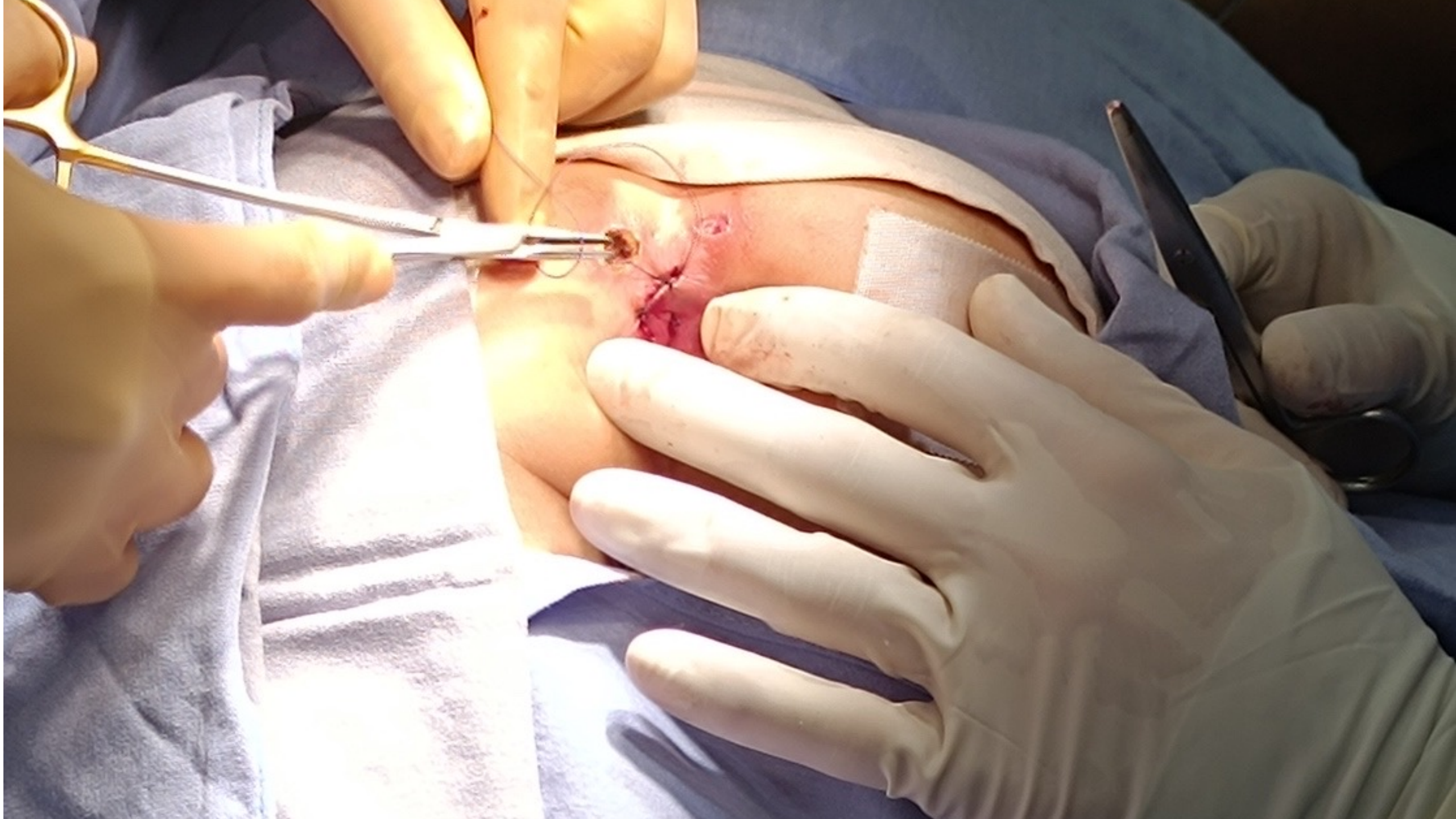







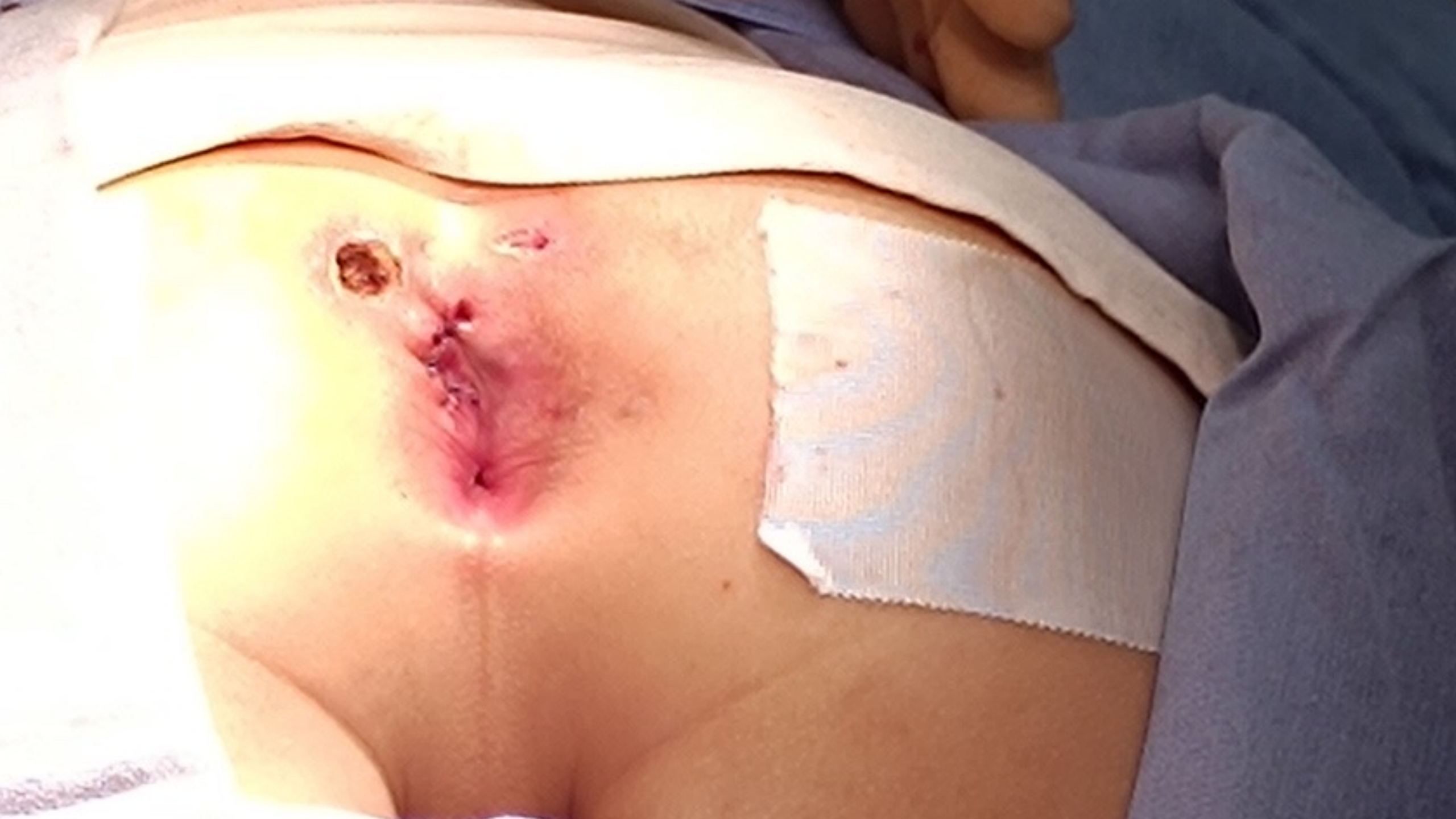






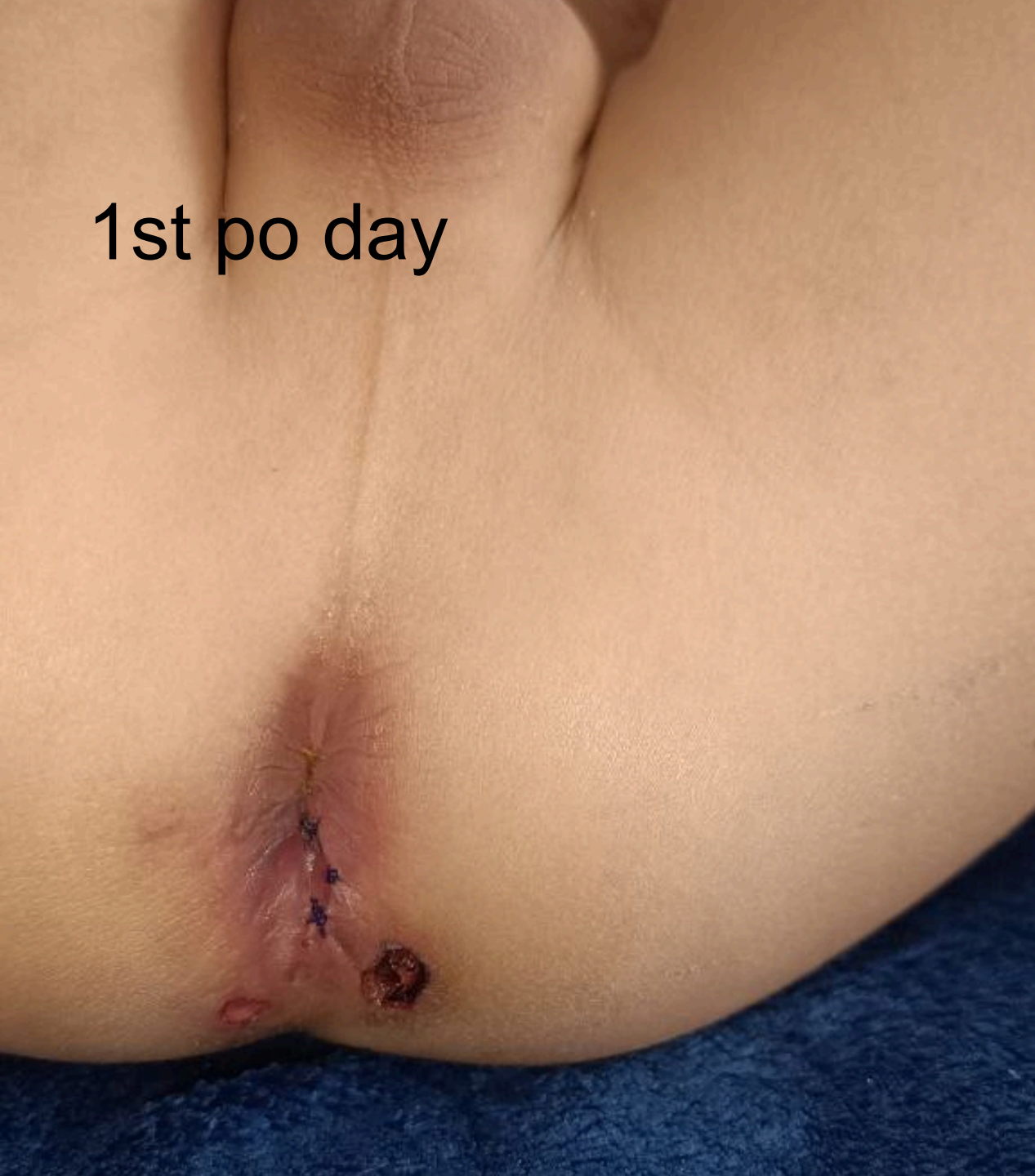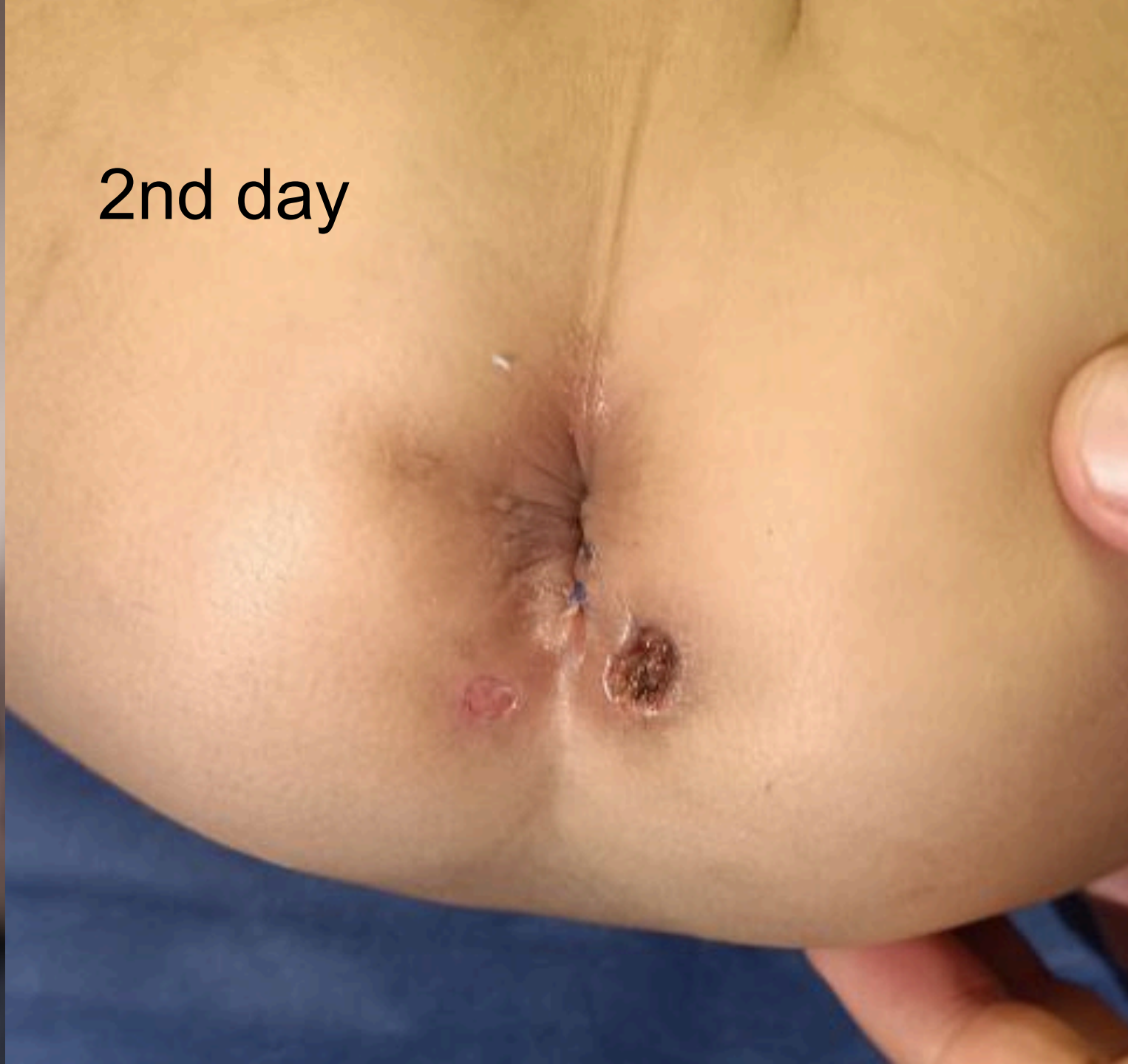Follow up

- The patient was hospitalized 24 hours for pain management.

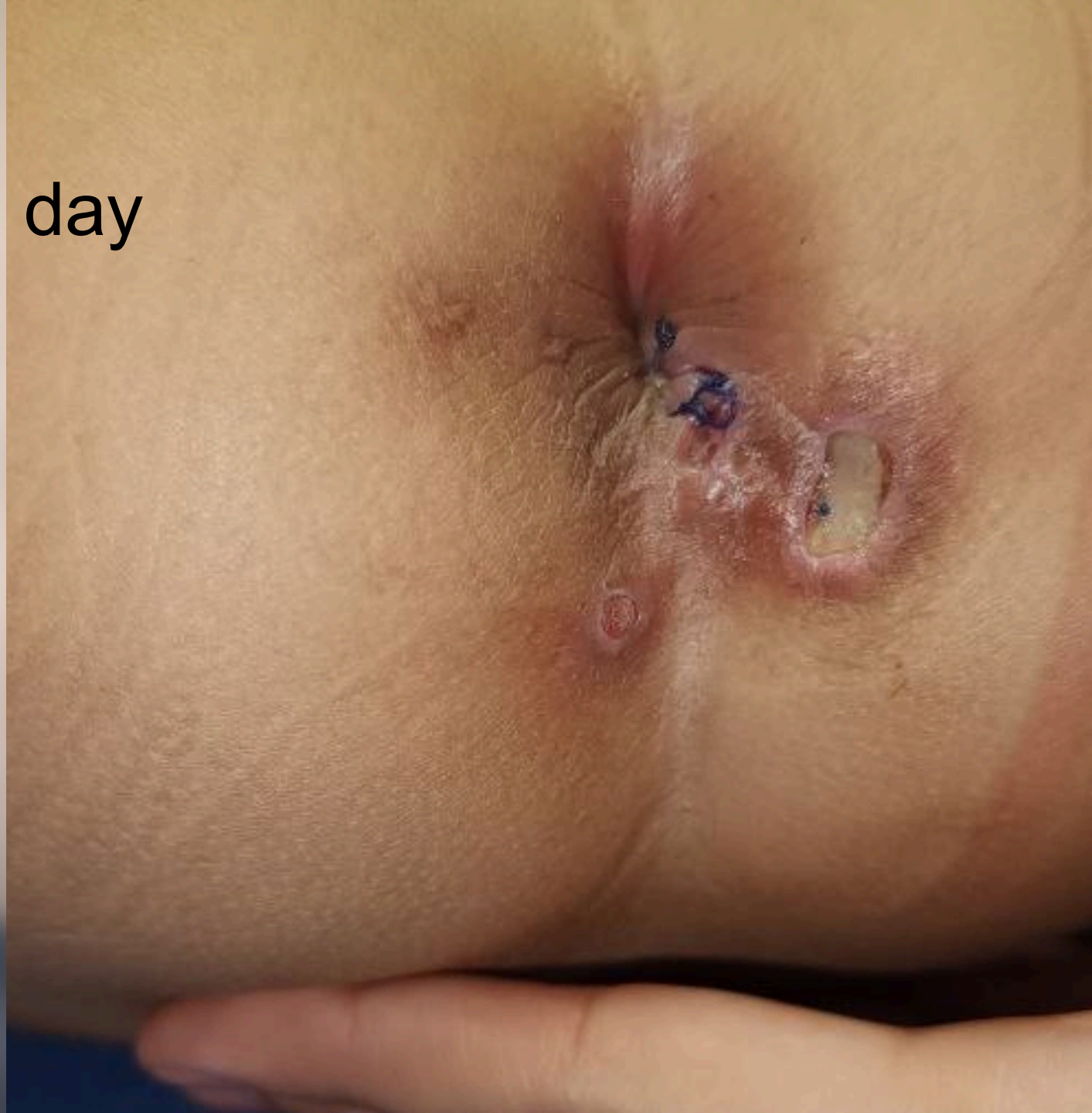1st po day



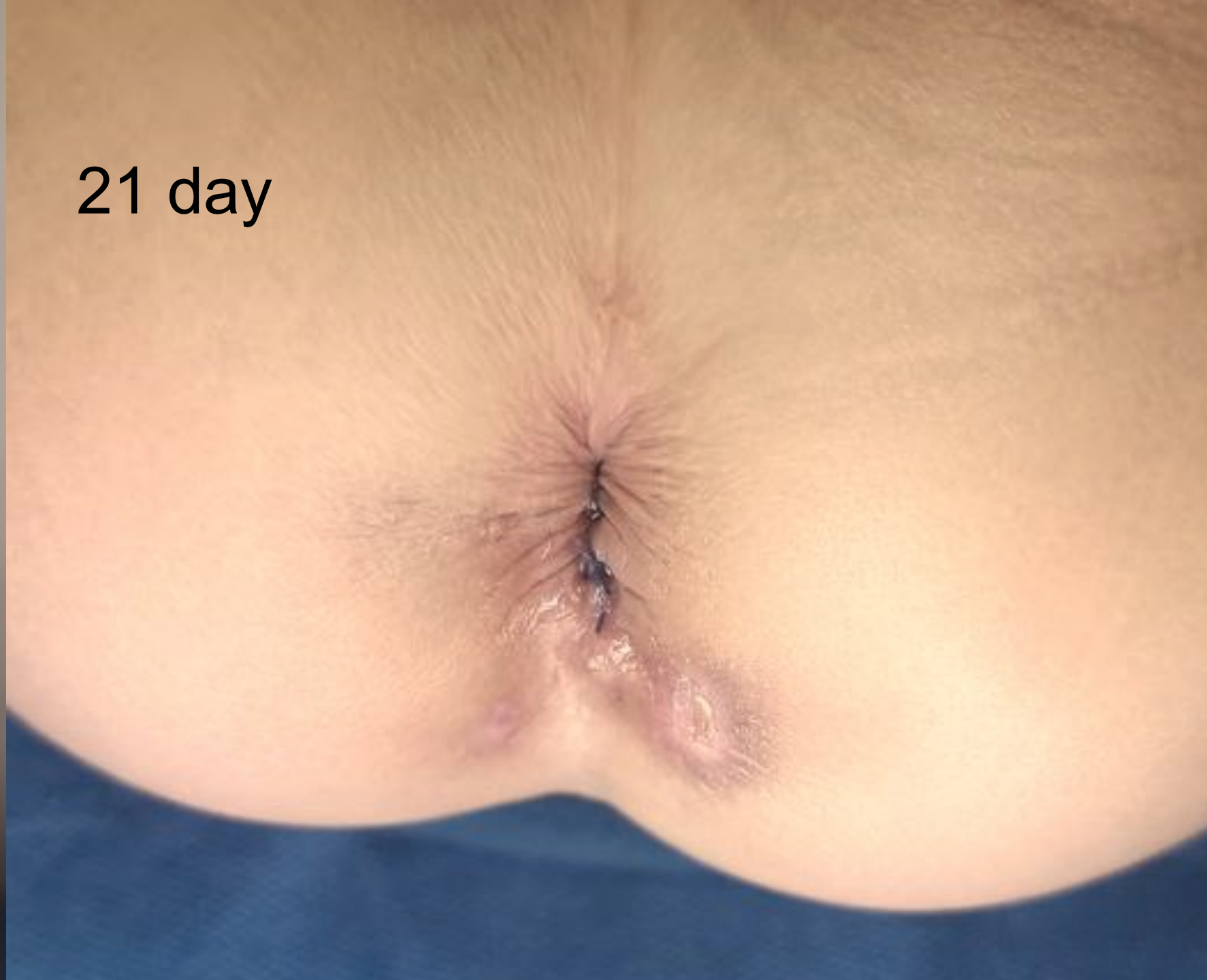2nd day



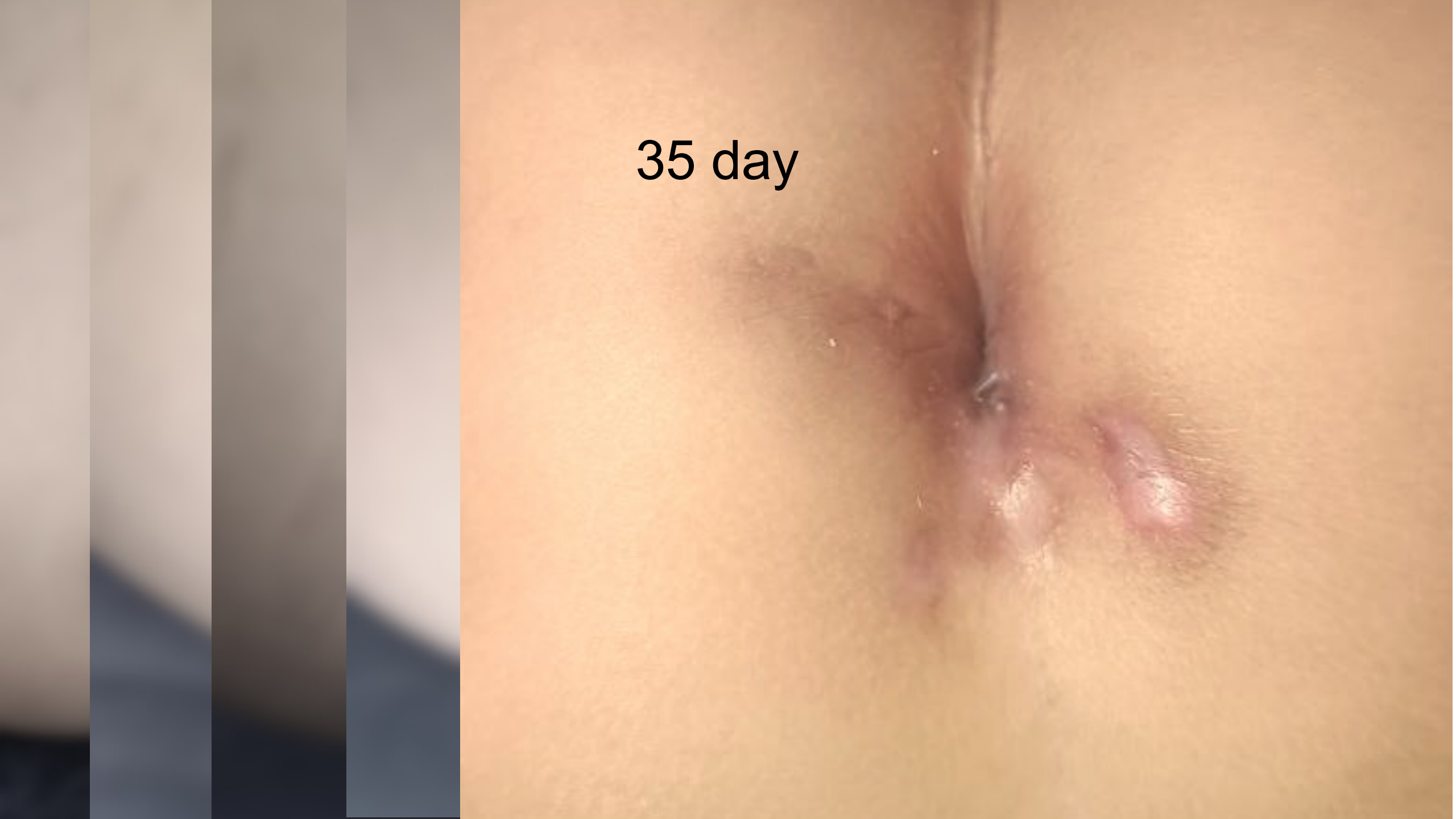9th day



21 day



35 day



- 1 ½ month po
- Good general condition
- No new episodes of abscess or pus discharge



CENTRO COLORRECTAL PARA NIÑOS MEXICO Y LATINOAMERICA



THANKS