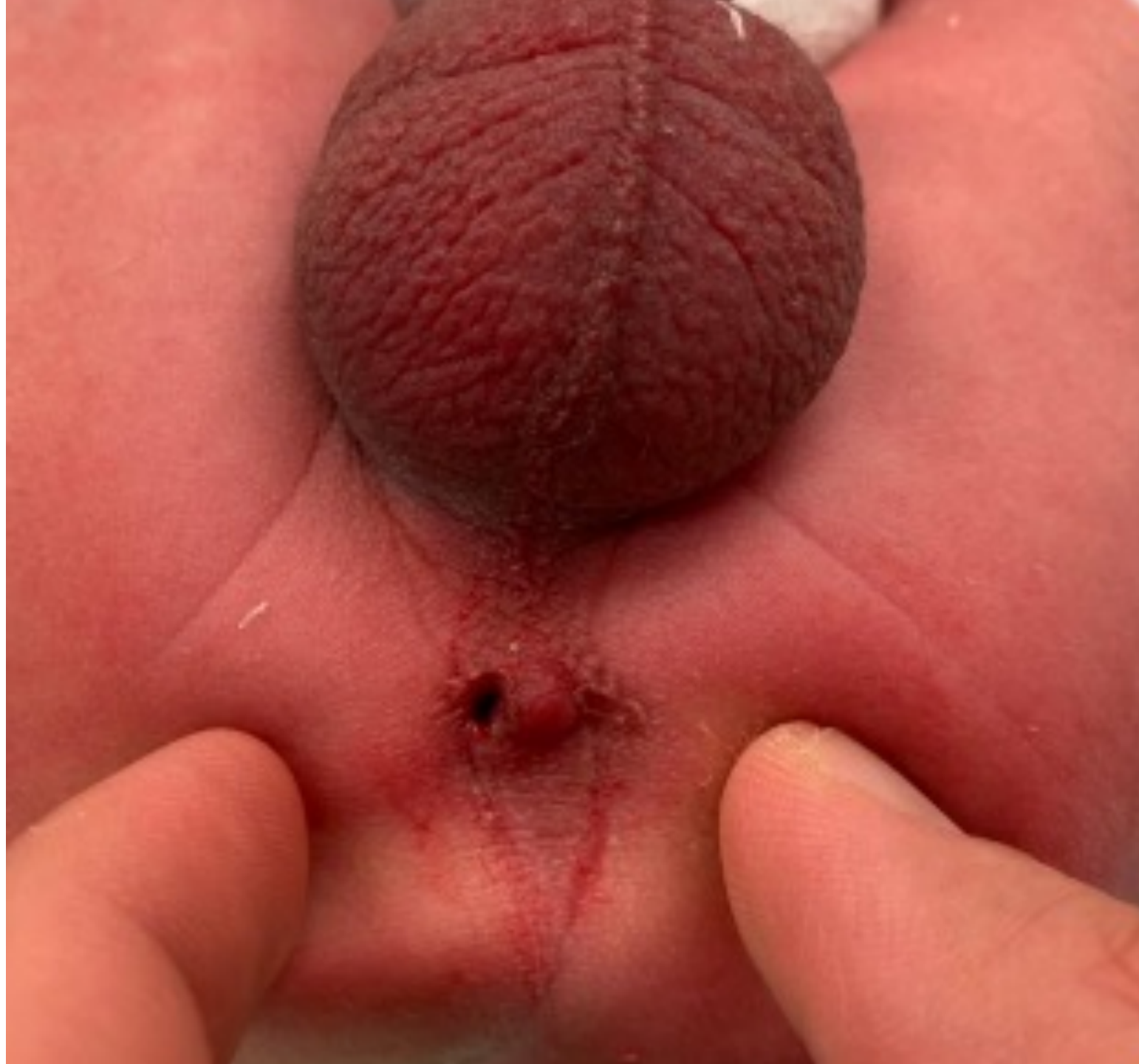



CENTRO COLORRECTAL PARA NIÑOS

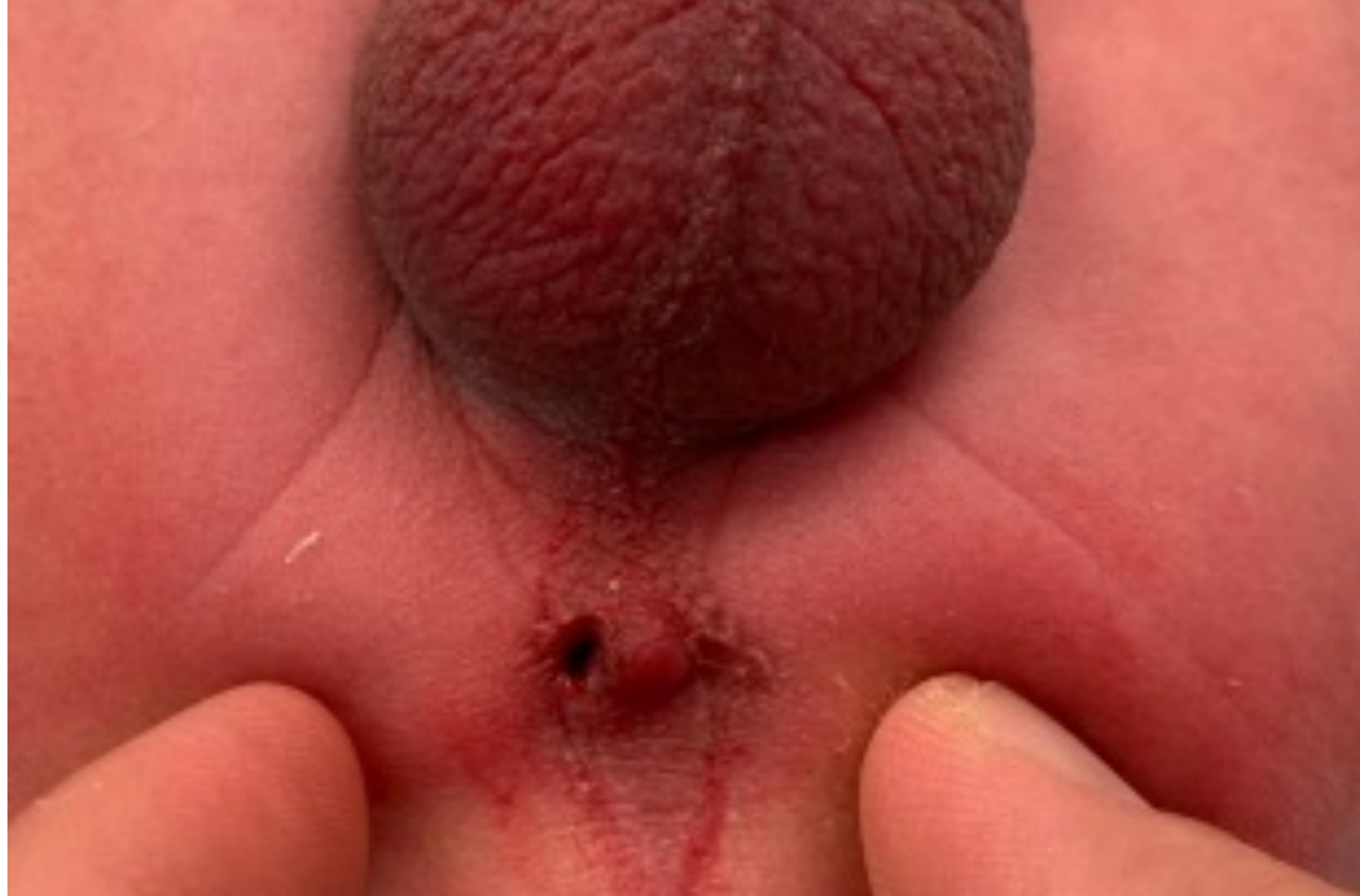Maria Zornoza, MD
Puebla, Mexico

- **Male patient**
- **DOB:** March 15, 2020.



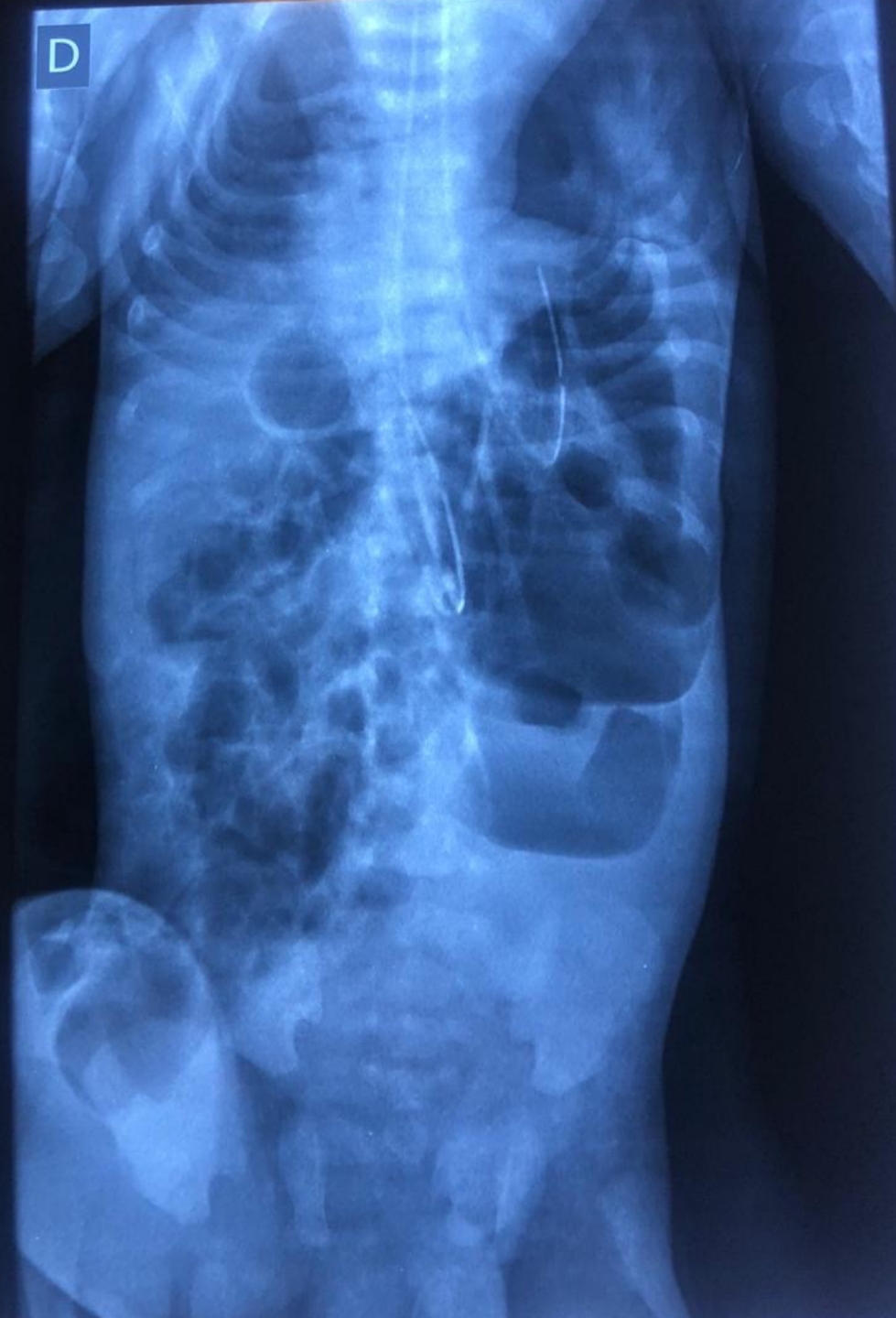What anorectal malformation is this?

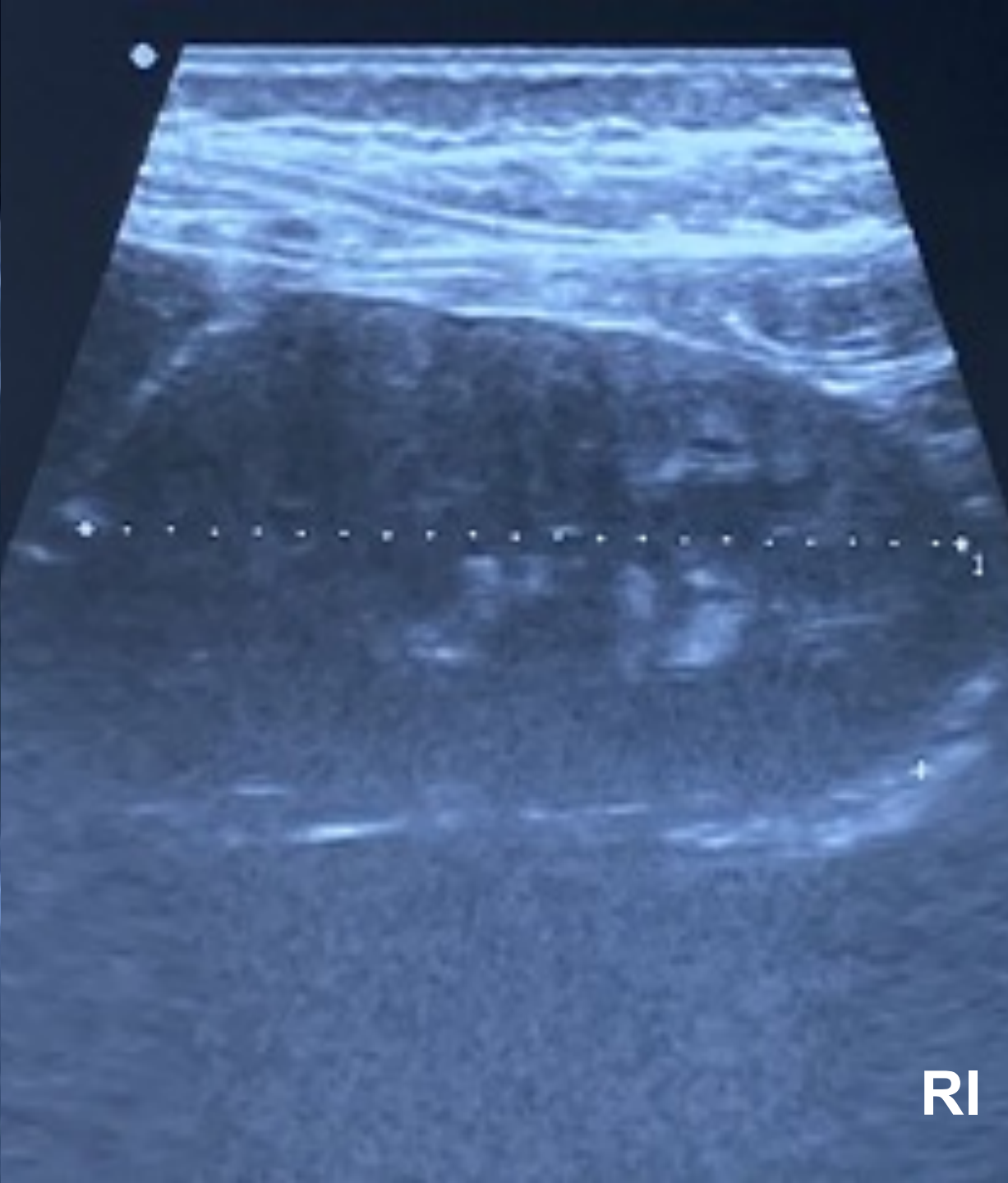
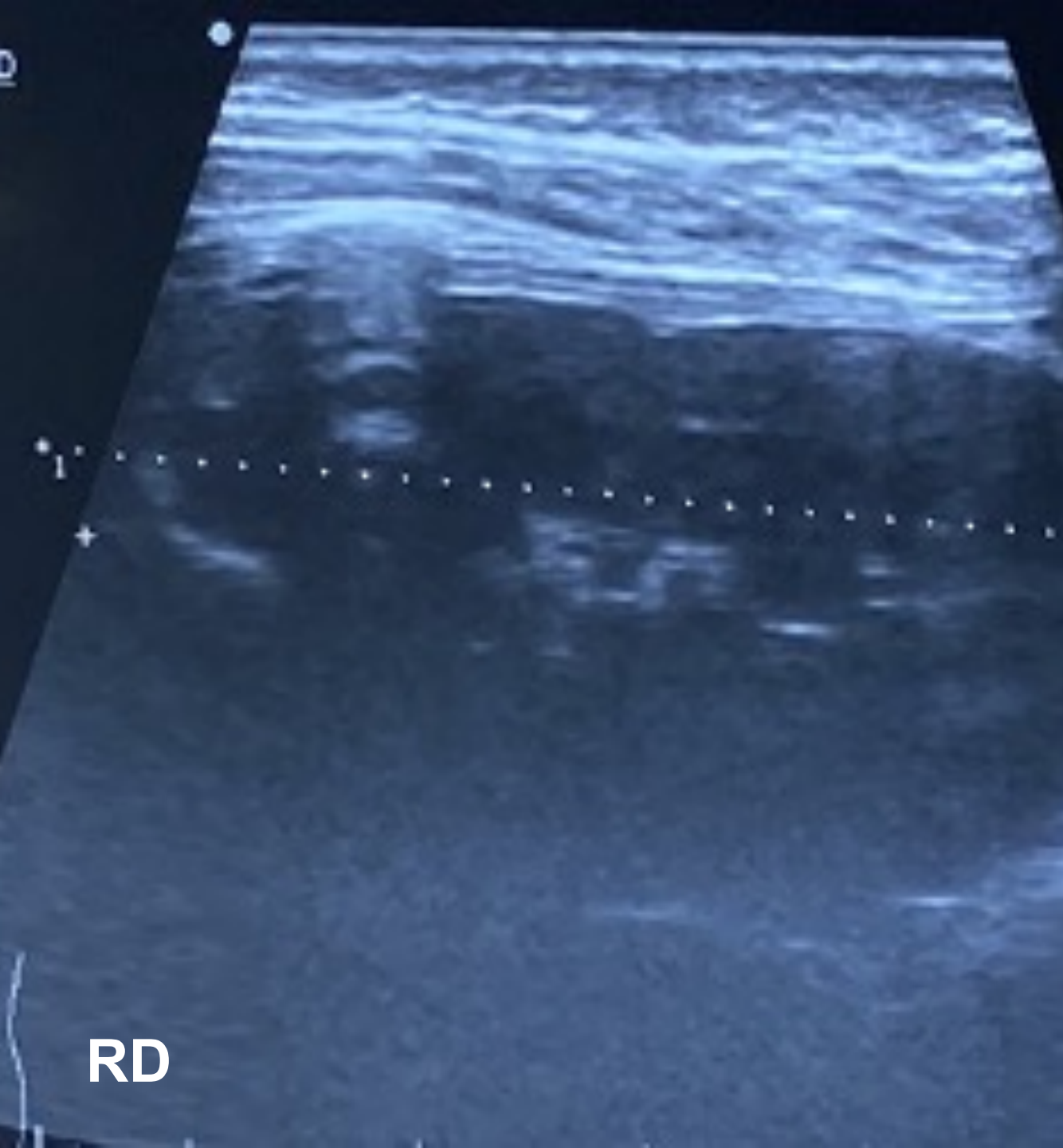
1. Rectoperineal fistula
2. Recto-bulbar fistula
3. Recto-prostatic fistula
4. Bladder neck fistula
5. No fistula
6. I don't Know



Protocol

D

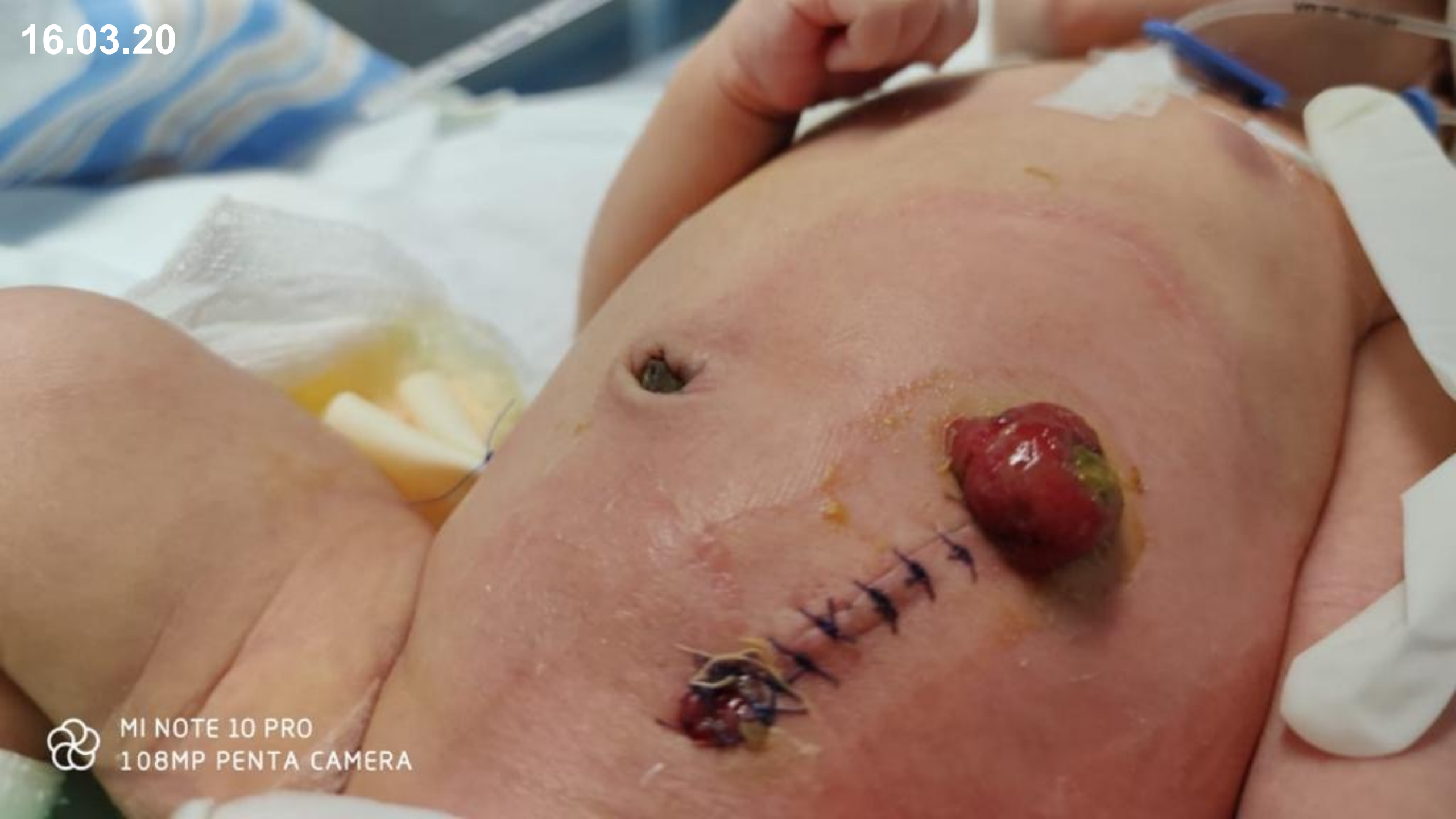



What would you do?

1. Primary PSARP
2. Colostomy

16.03.20



MI NOTE 10 PRO
108MP PENTA CAMERA

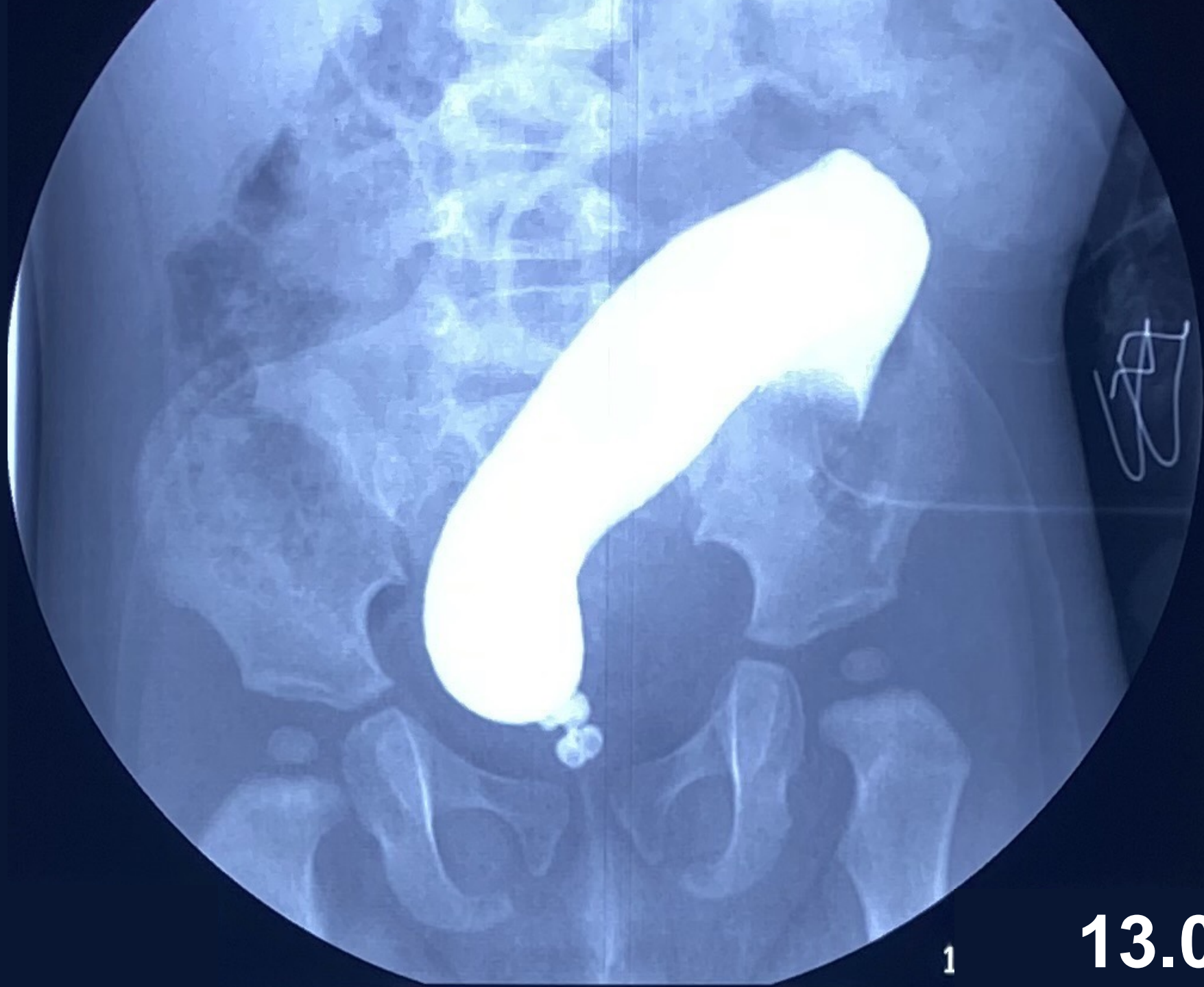DEI: 3.01 [0.56 - 1.68] CDExp:21.95µGy

3,3

SR: 0,63

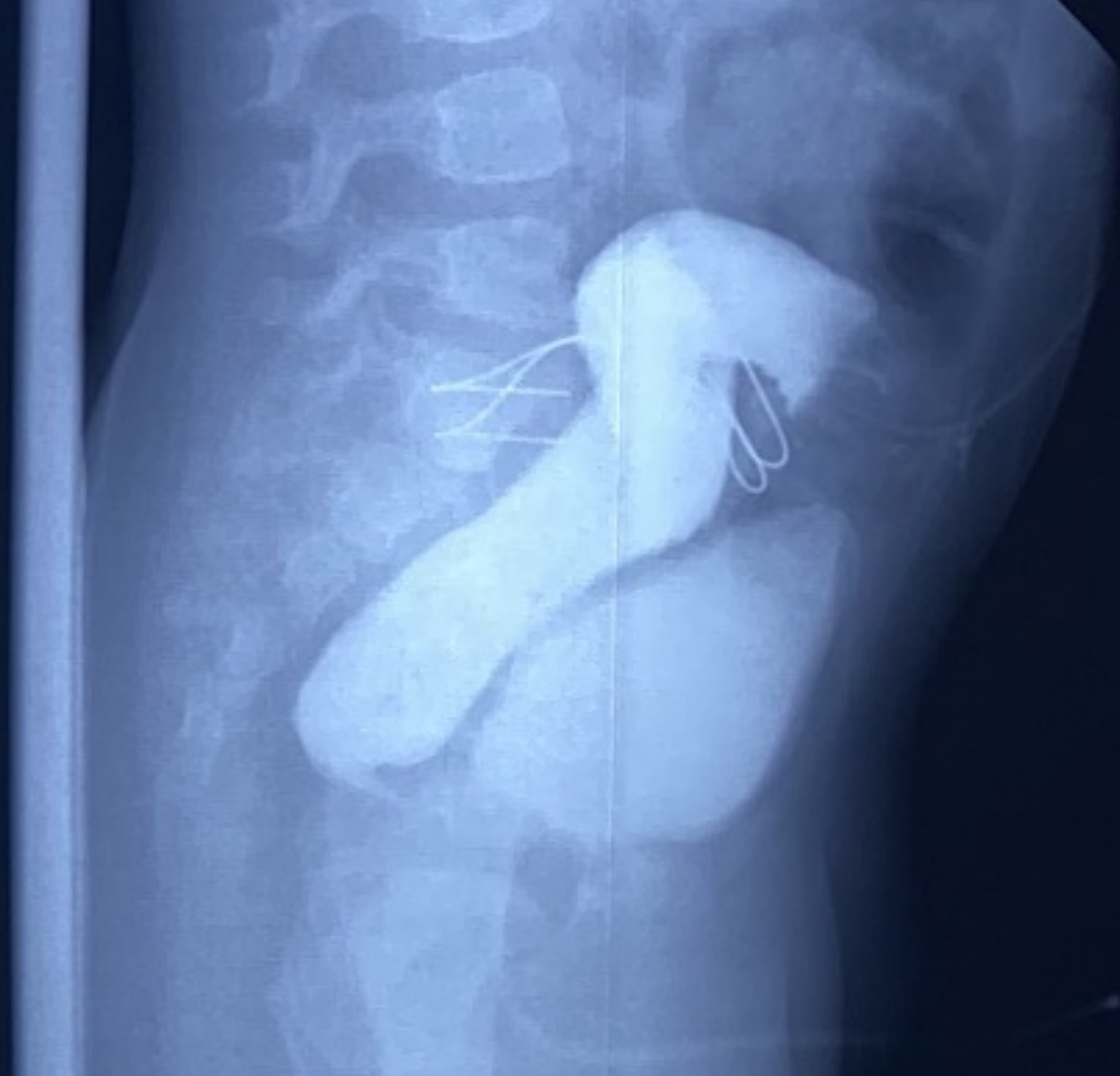2,1

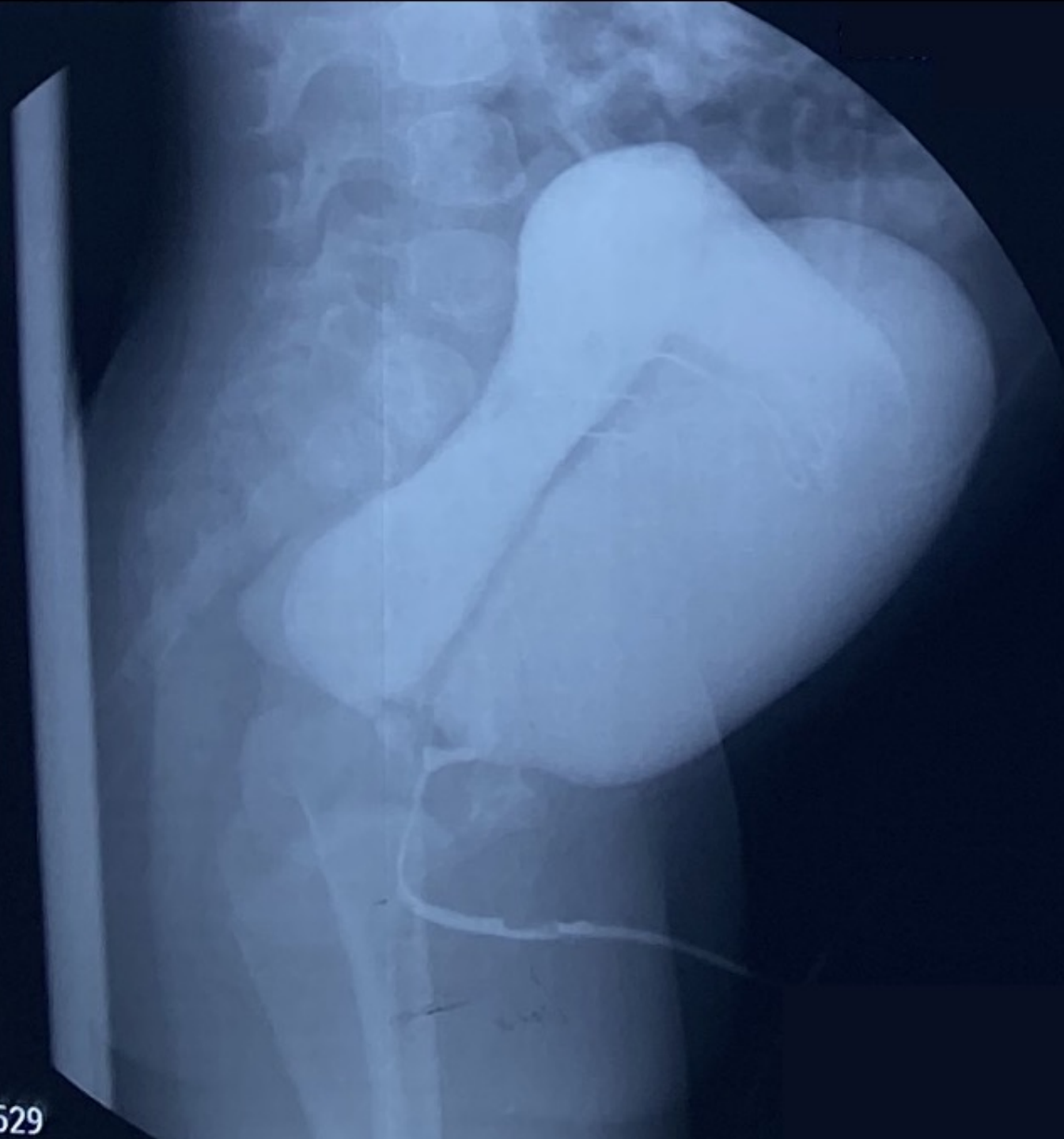Abdomen_antero-posterior_Standard_MEDIUM ADULT_Factory2

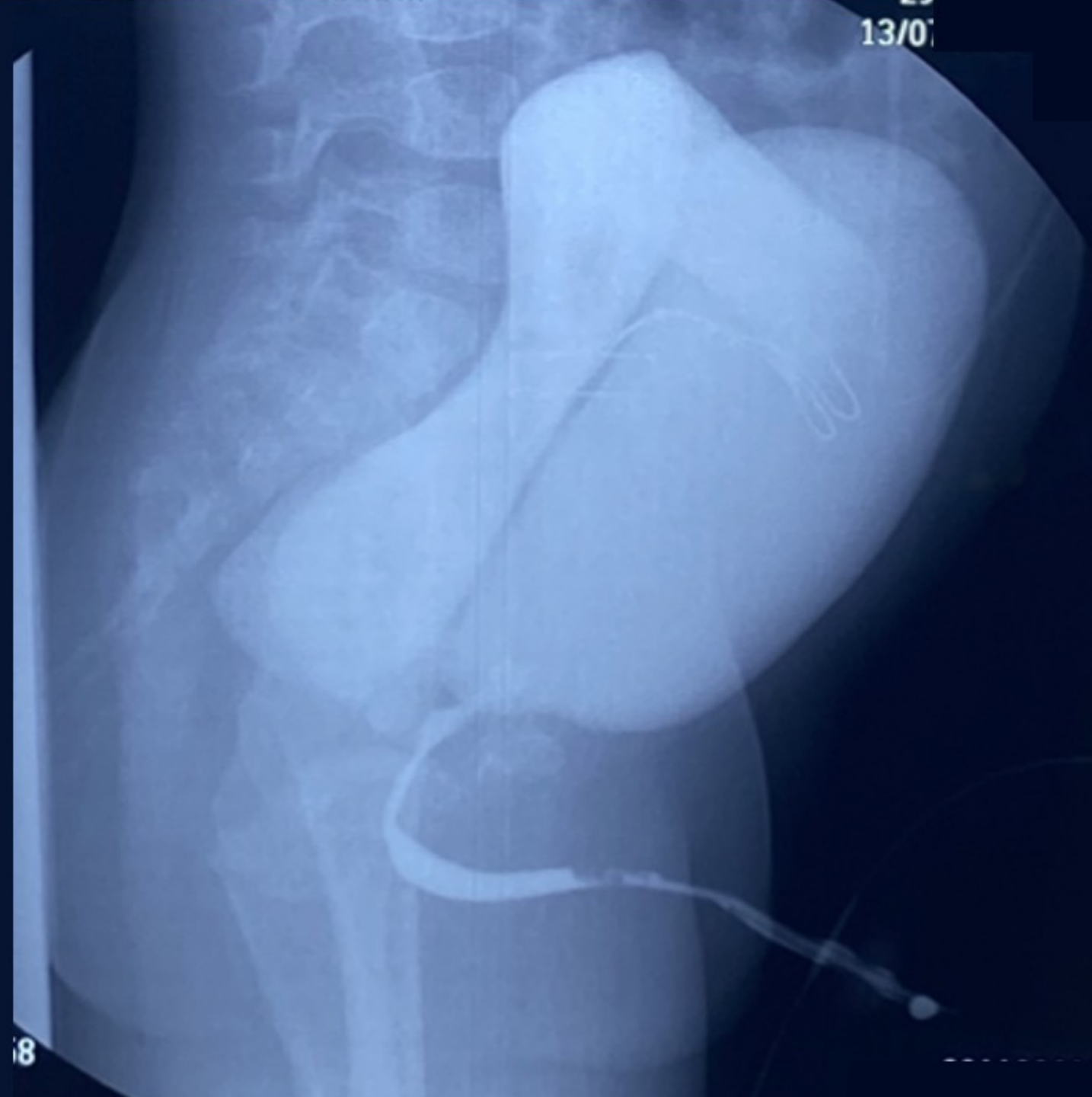

1

13.07.21

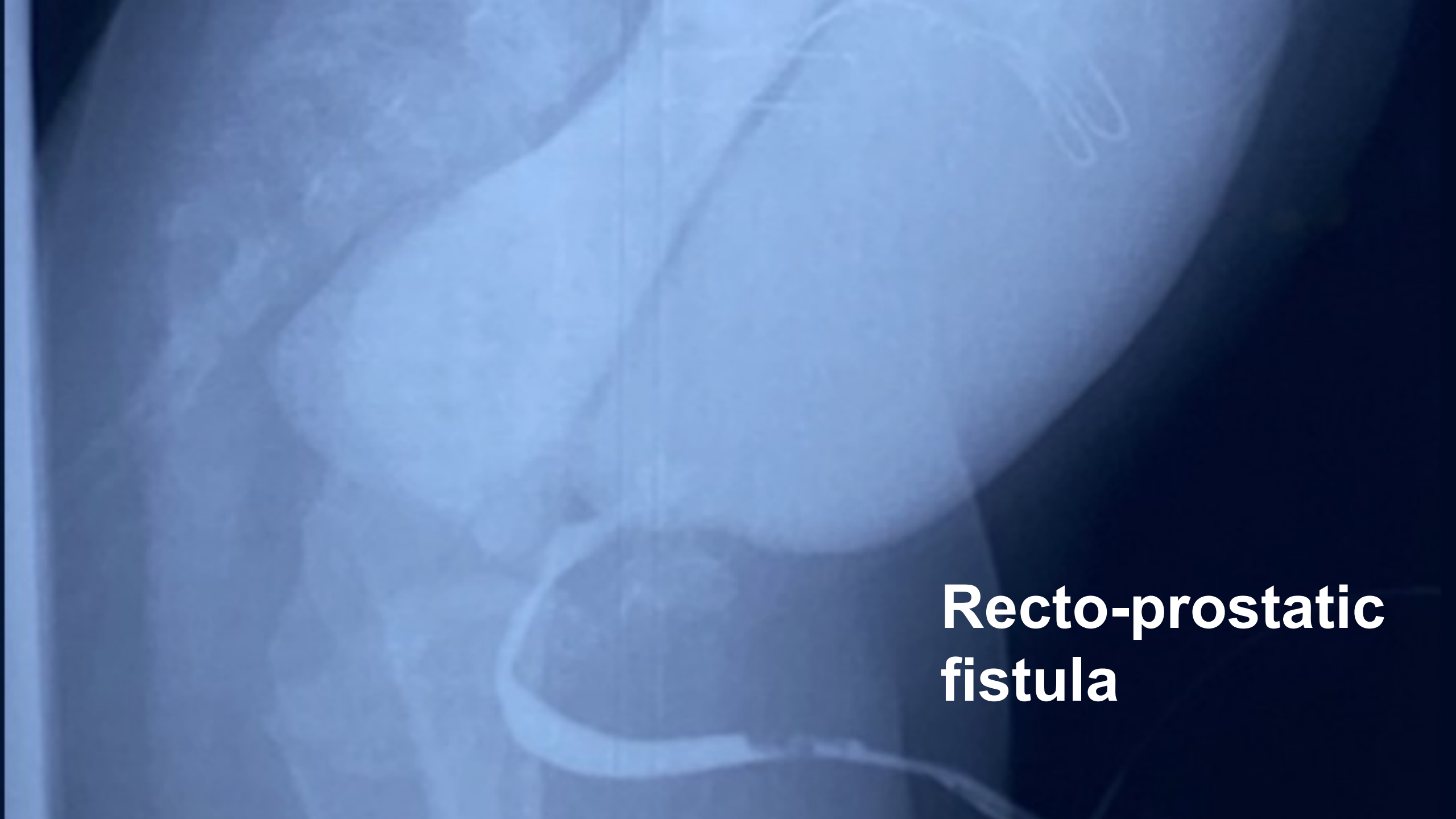






What anorectal malformation do you think this patient has?

1. Rectoperineal fistula
2. Recto-bulbar fistula
3. Recto-prostatic fistula
4. Bladder neck fistula
5. No fistula
6. I don't know

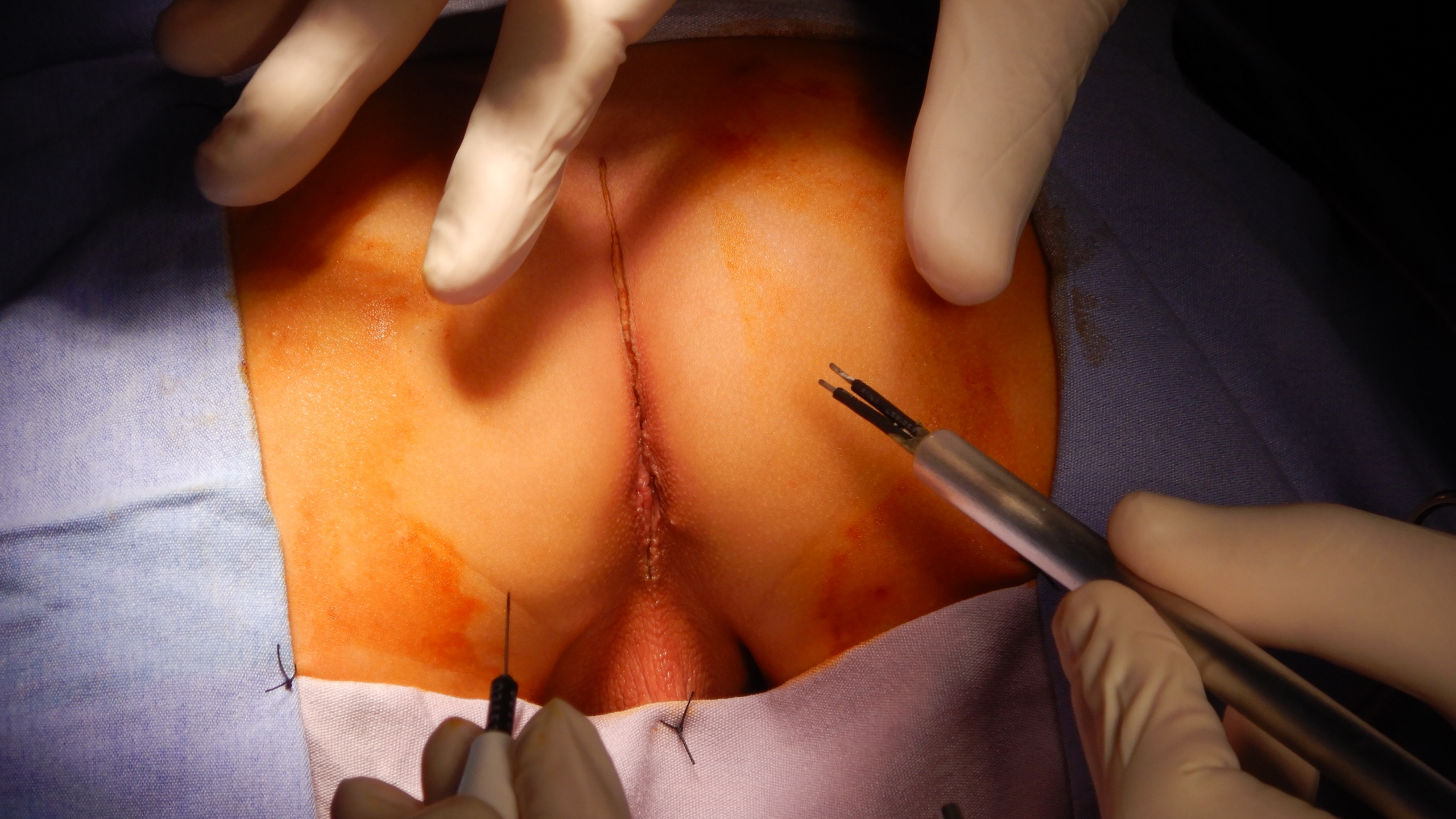


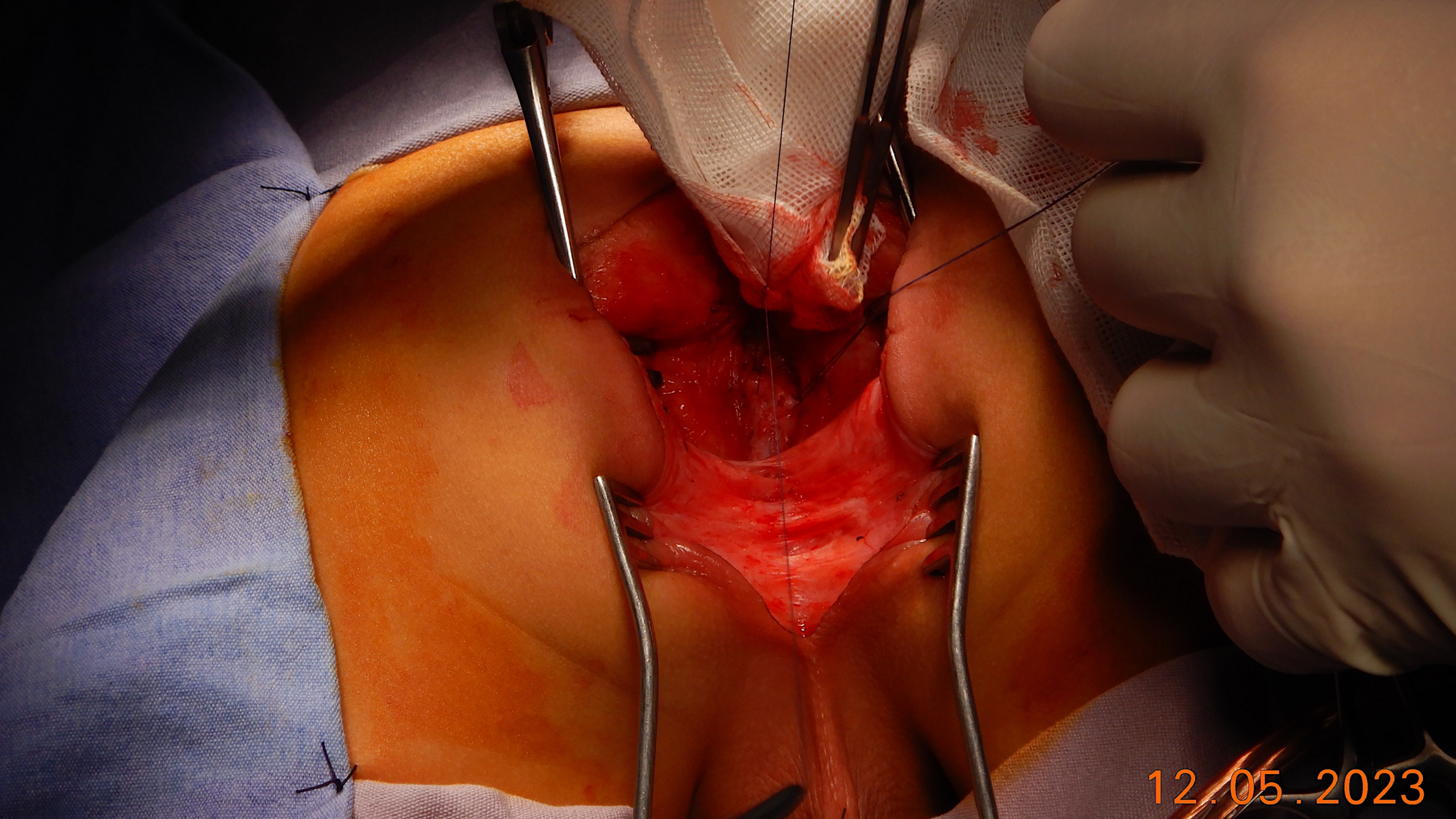
**Recto-prostatic
fistula**

How do you operate on the patient?

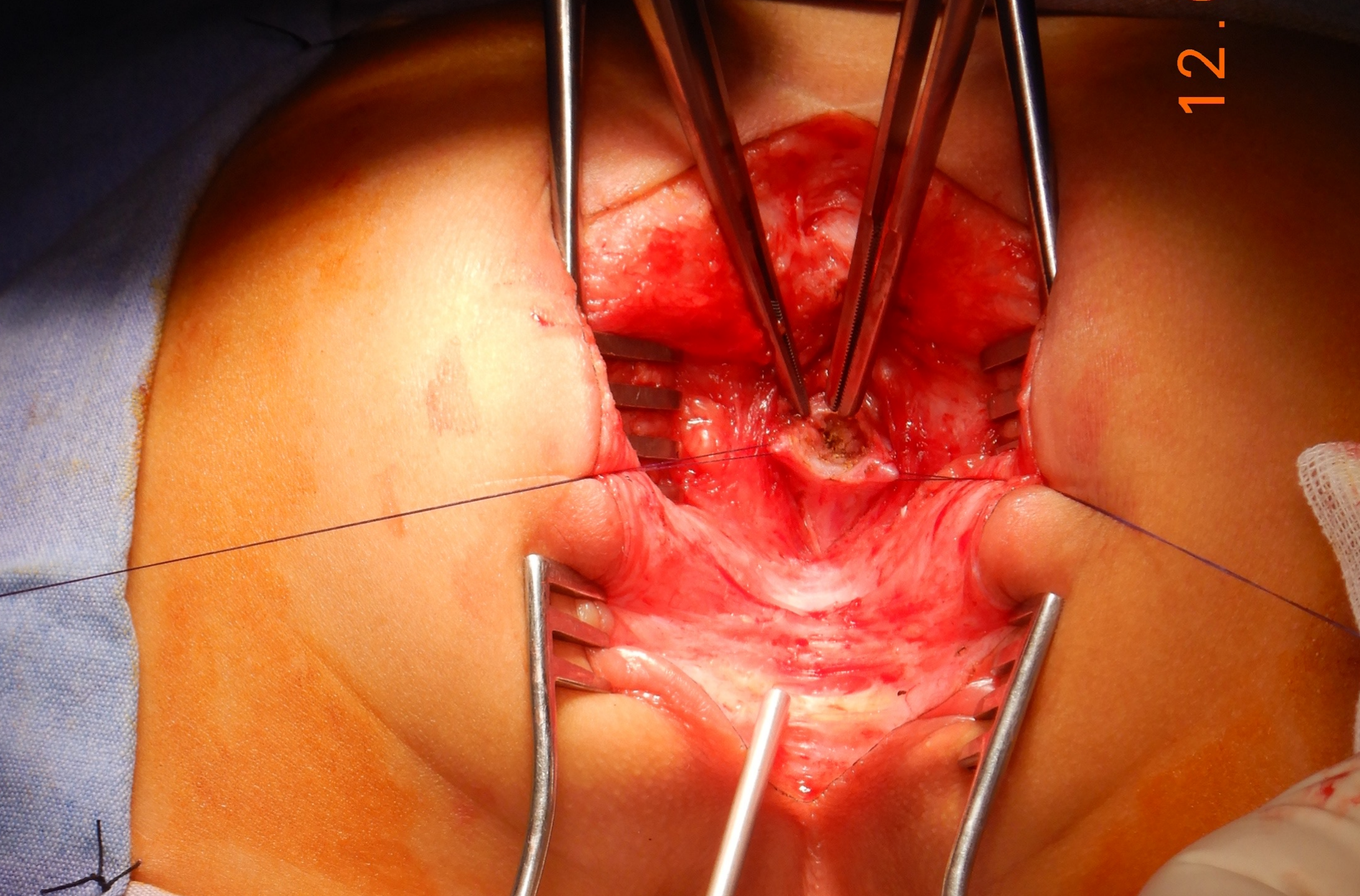
1. PSARP
2. Laparoscopic approach
3. Abdominal approach
4. Other

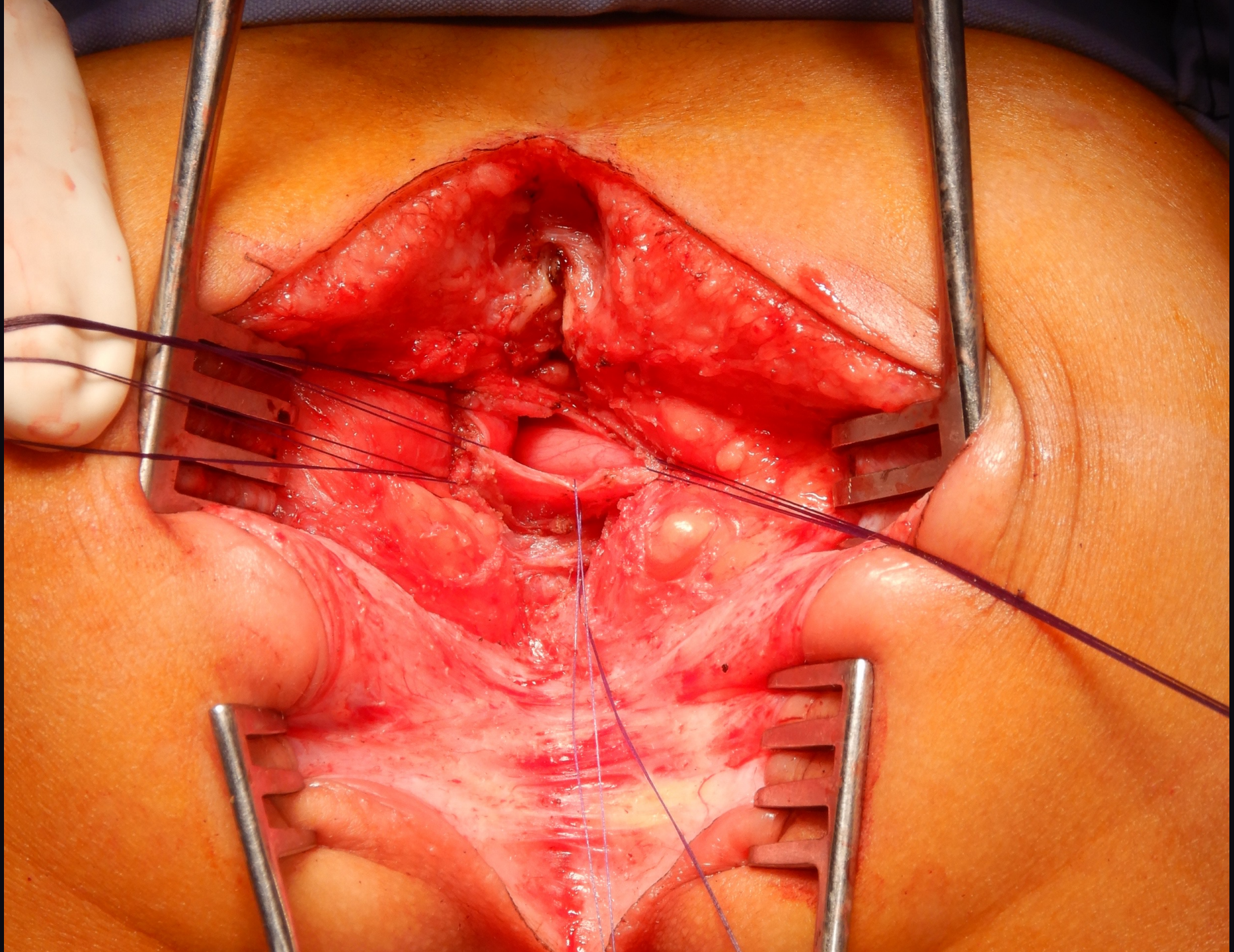
PSARP 12.05.23

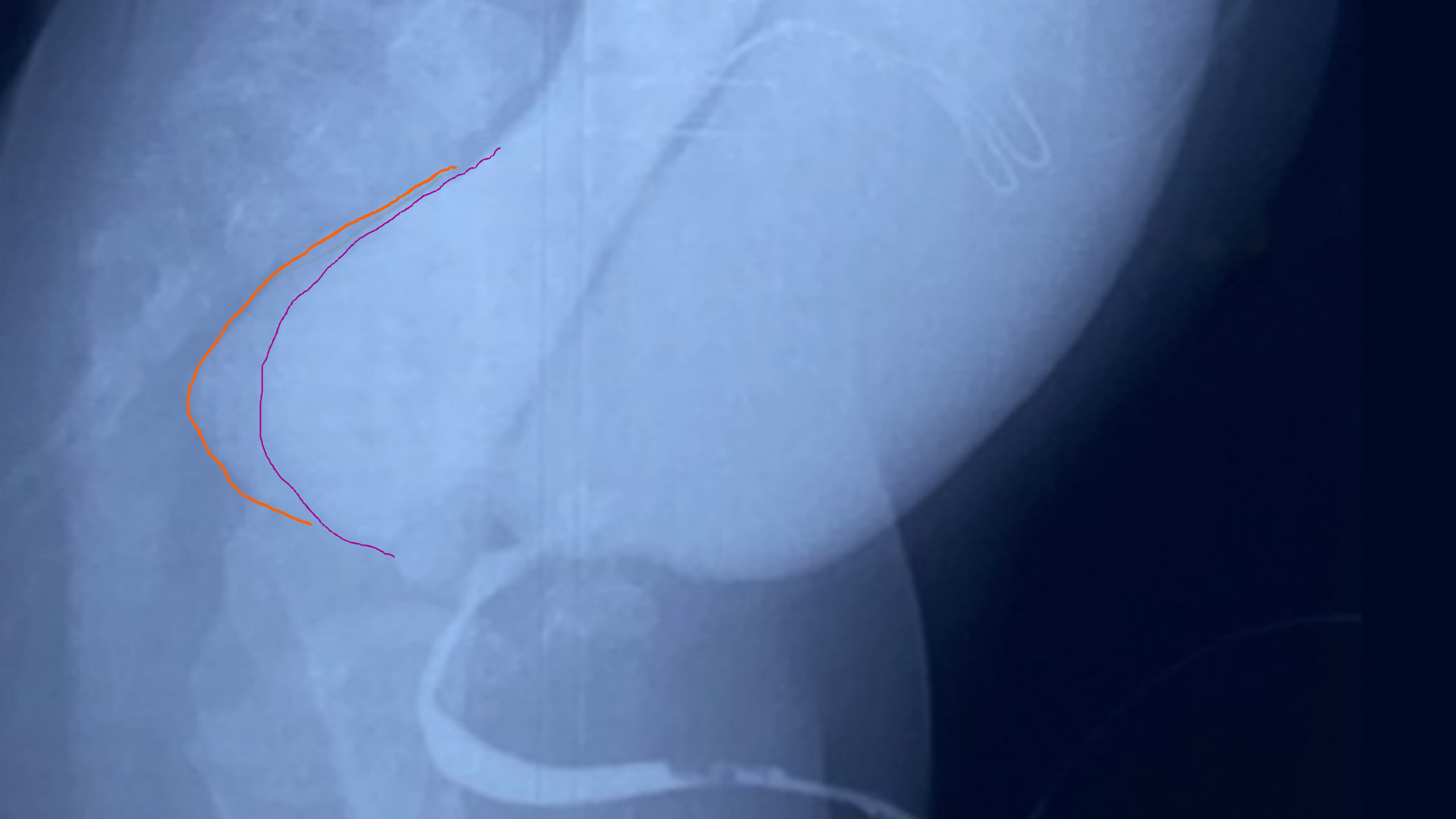


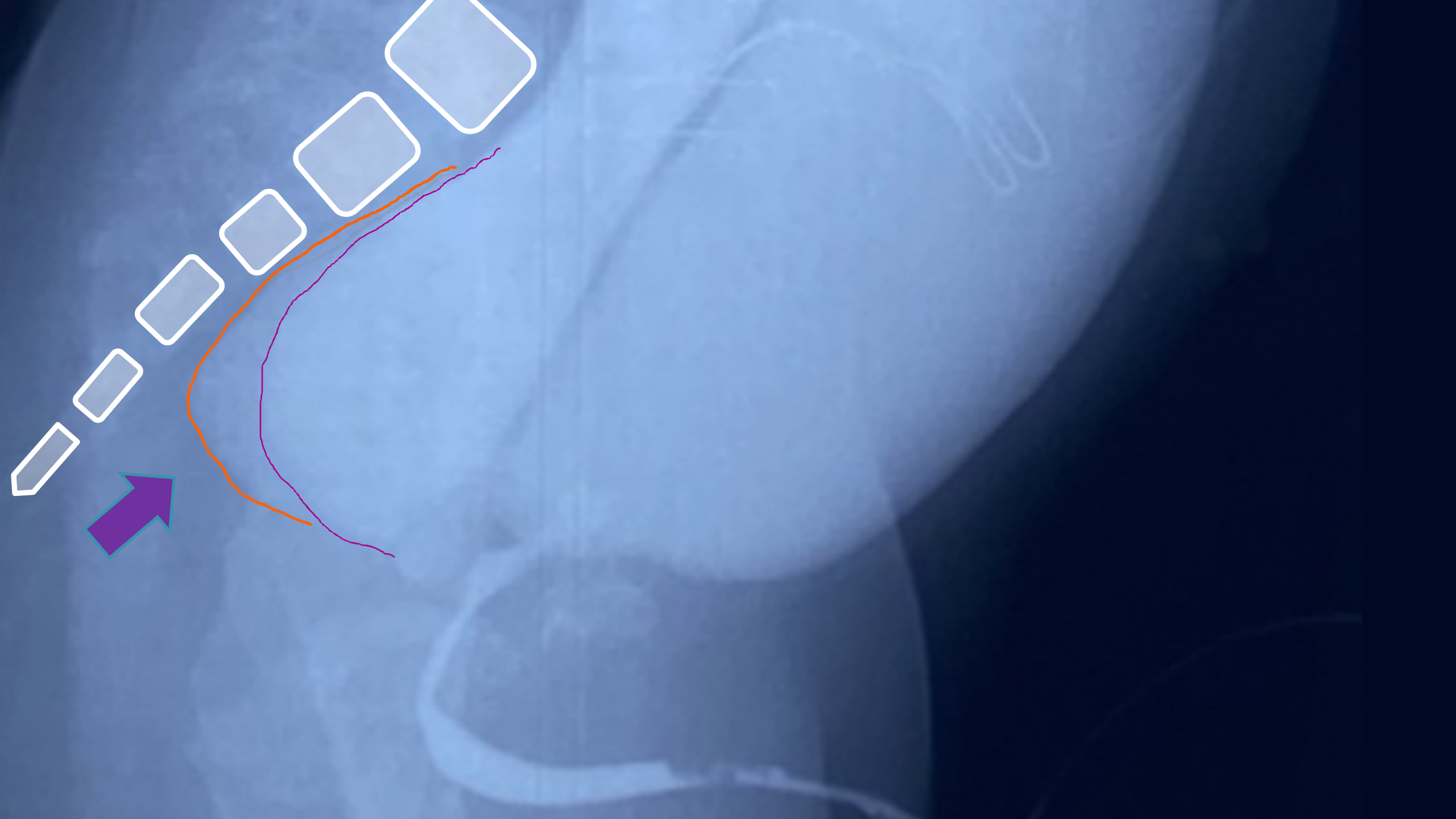


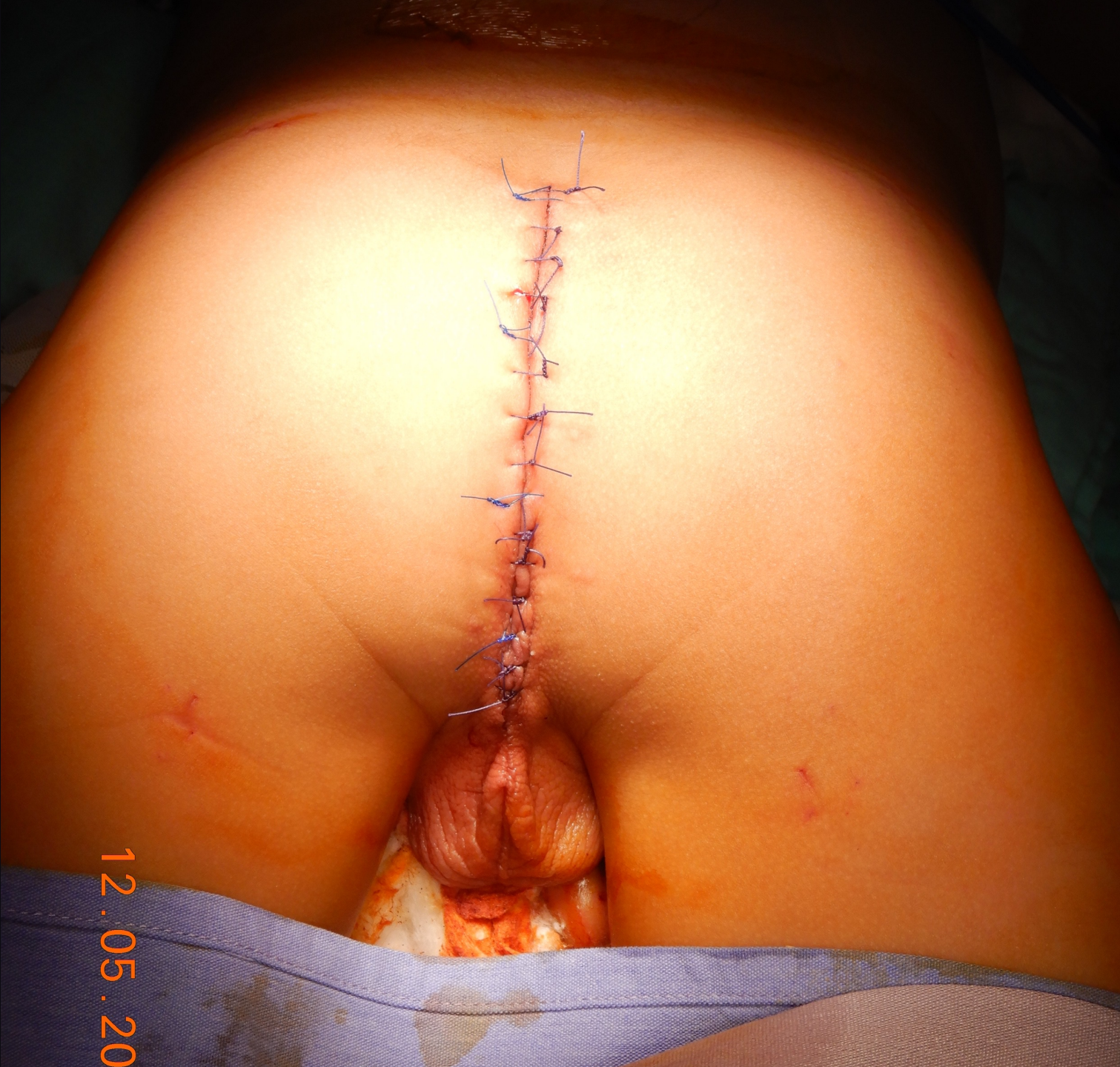12.05.2023











12.05.20

Three days after

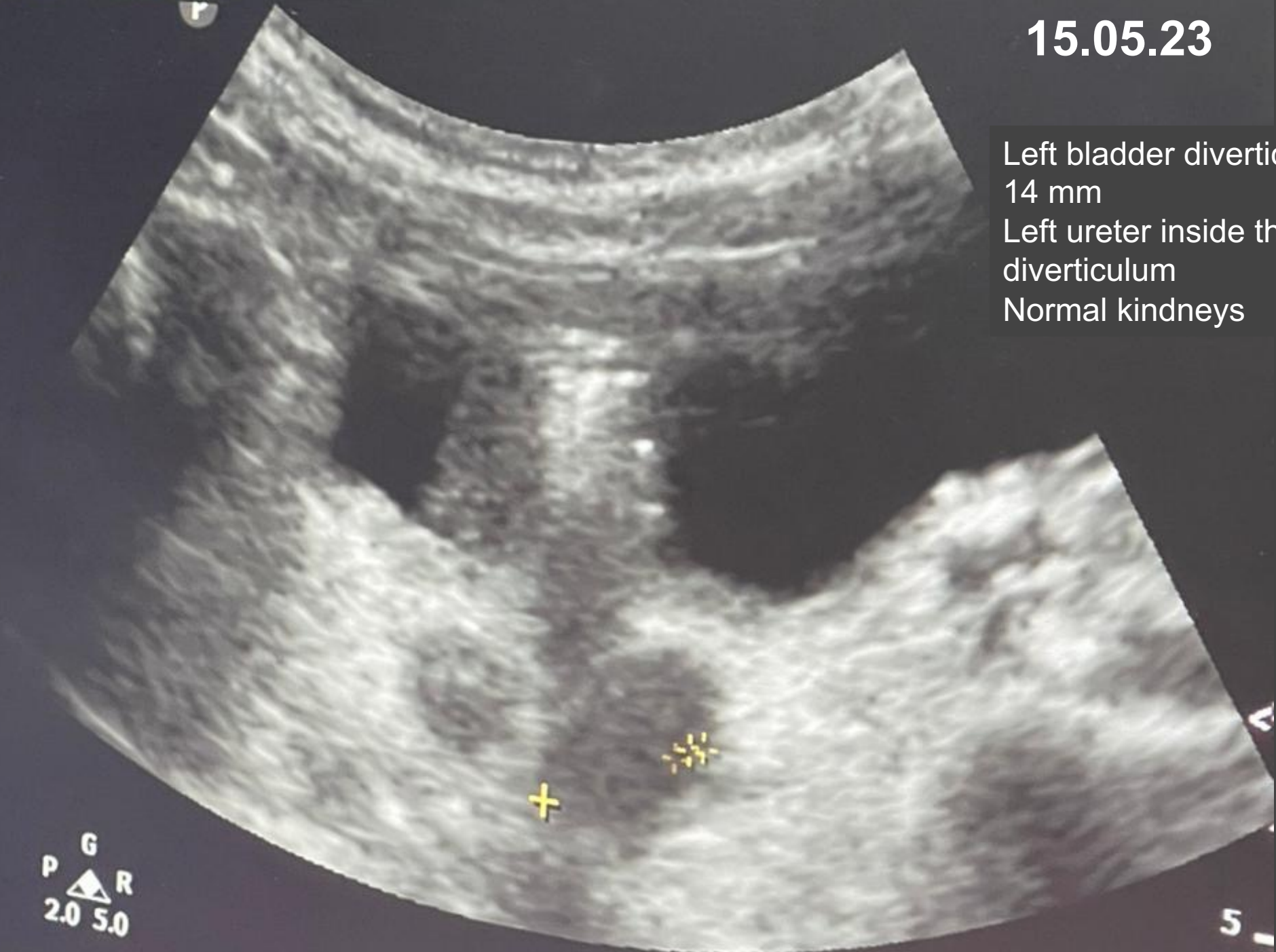Renal ultrasound, cystoscopy, and abdominal approach

15.05.23

Left bladder diverticulum 19 x
14 mm
Left ureter inside the
diverticulum
Normal kidneys

G
P ▲ R
2.0 5.0

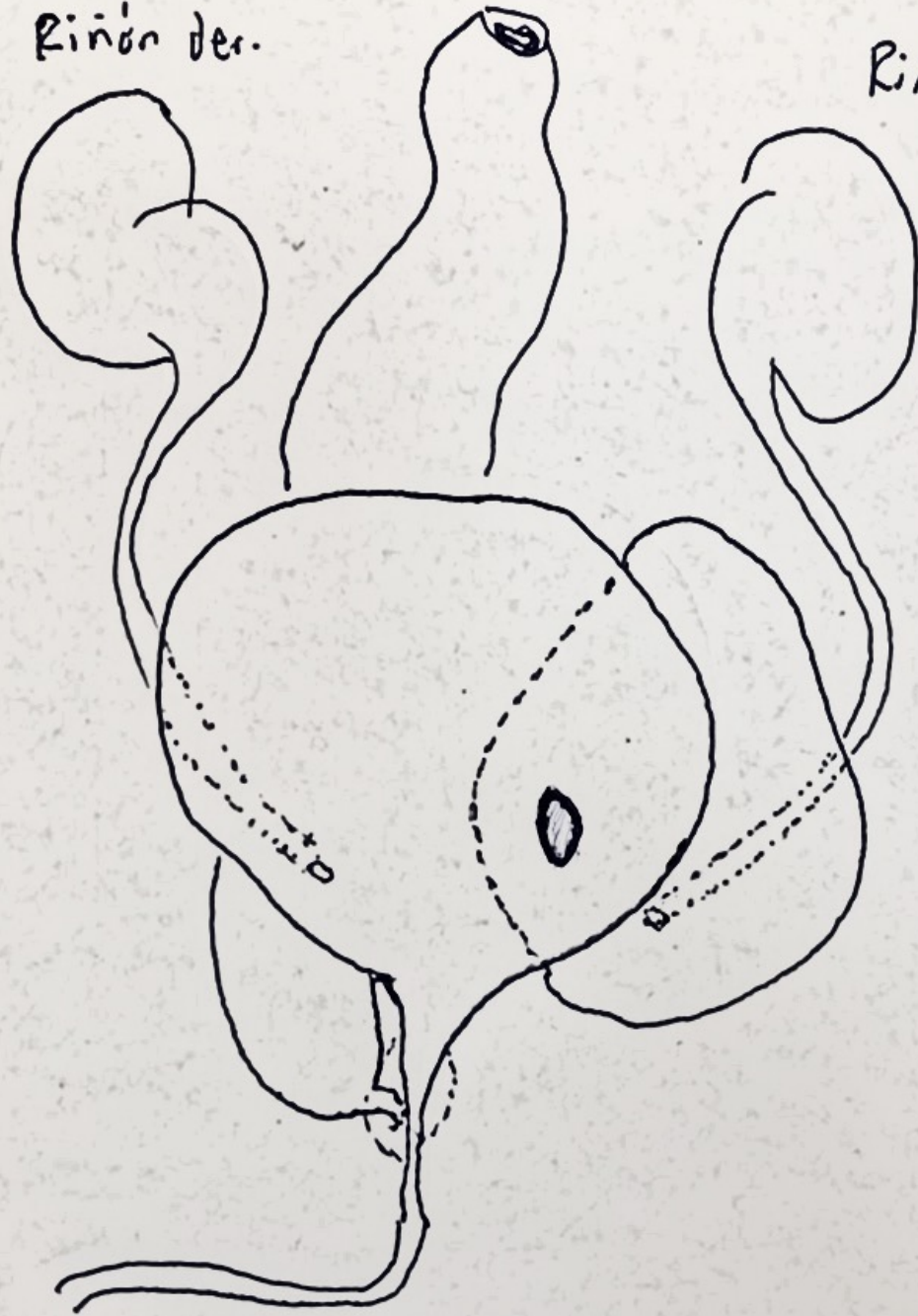
5

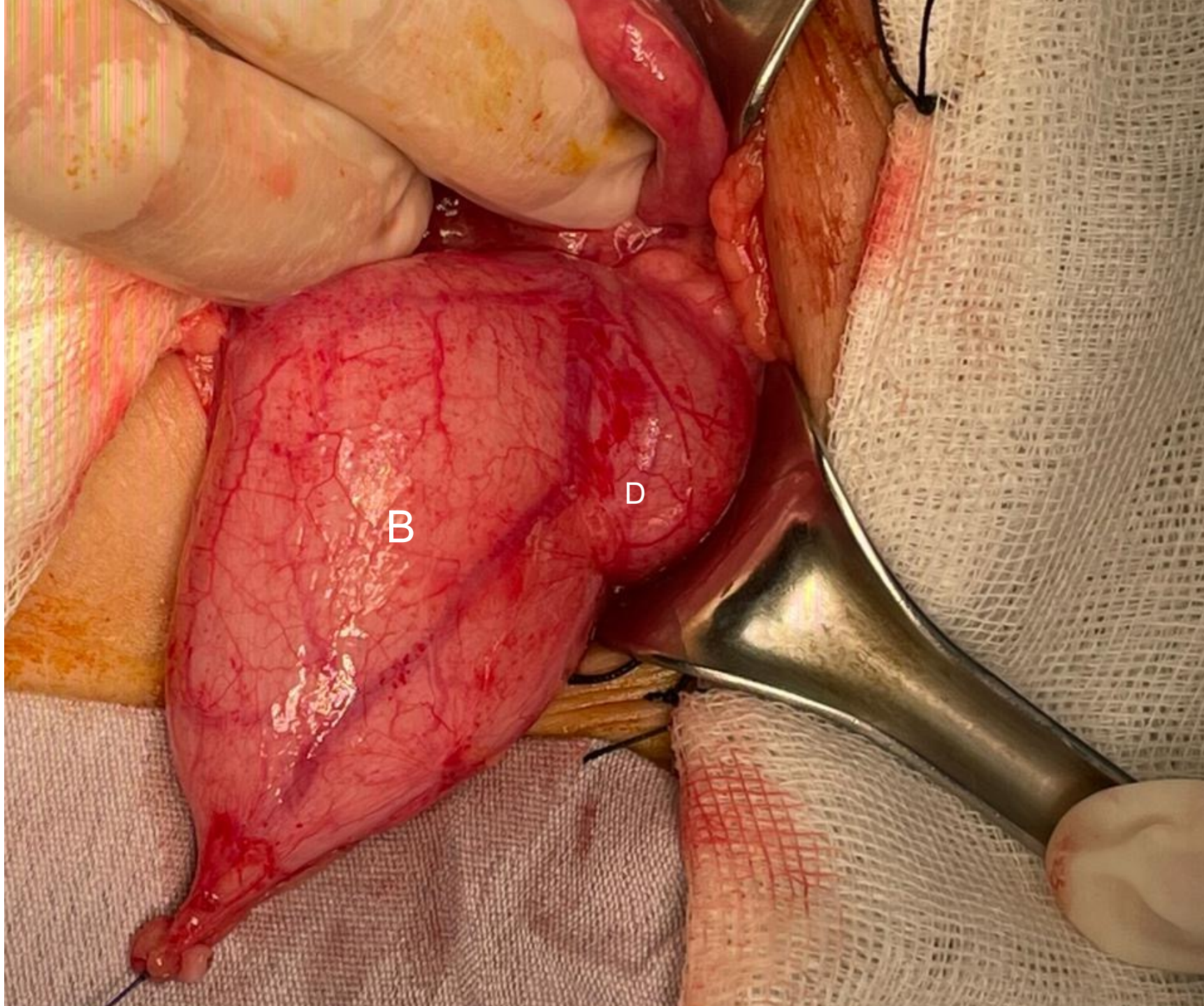


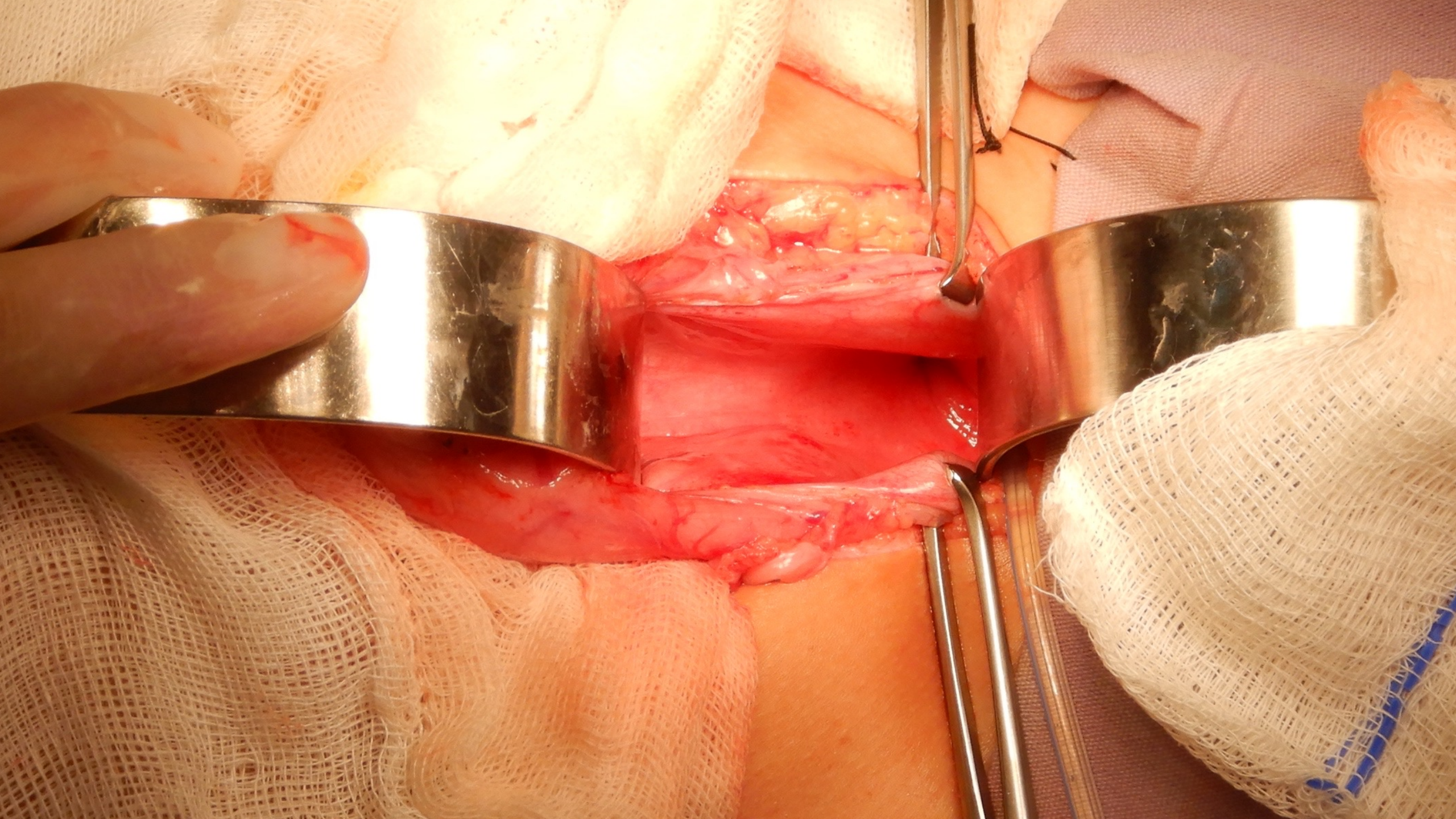
Cystoscopy 15.05.23

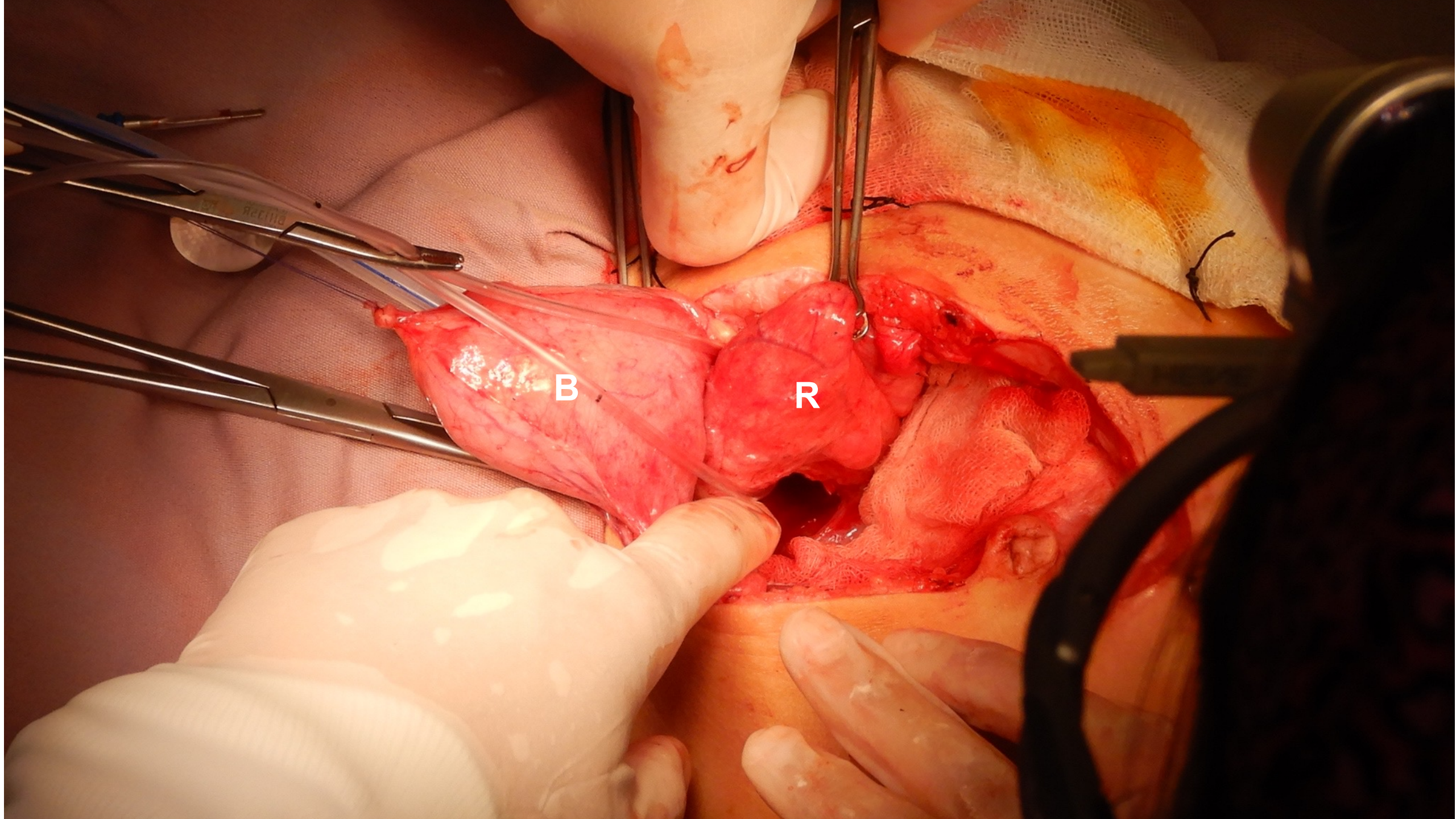
Rind der.

Rind iq.



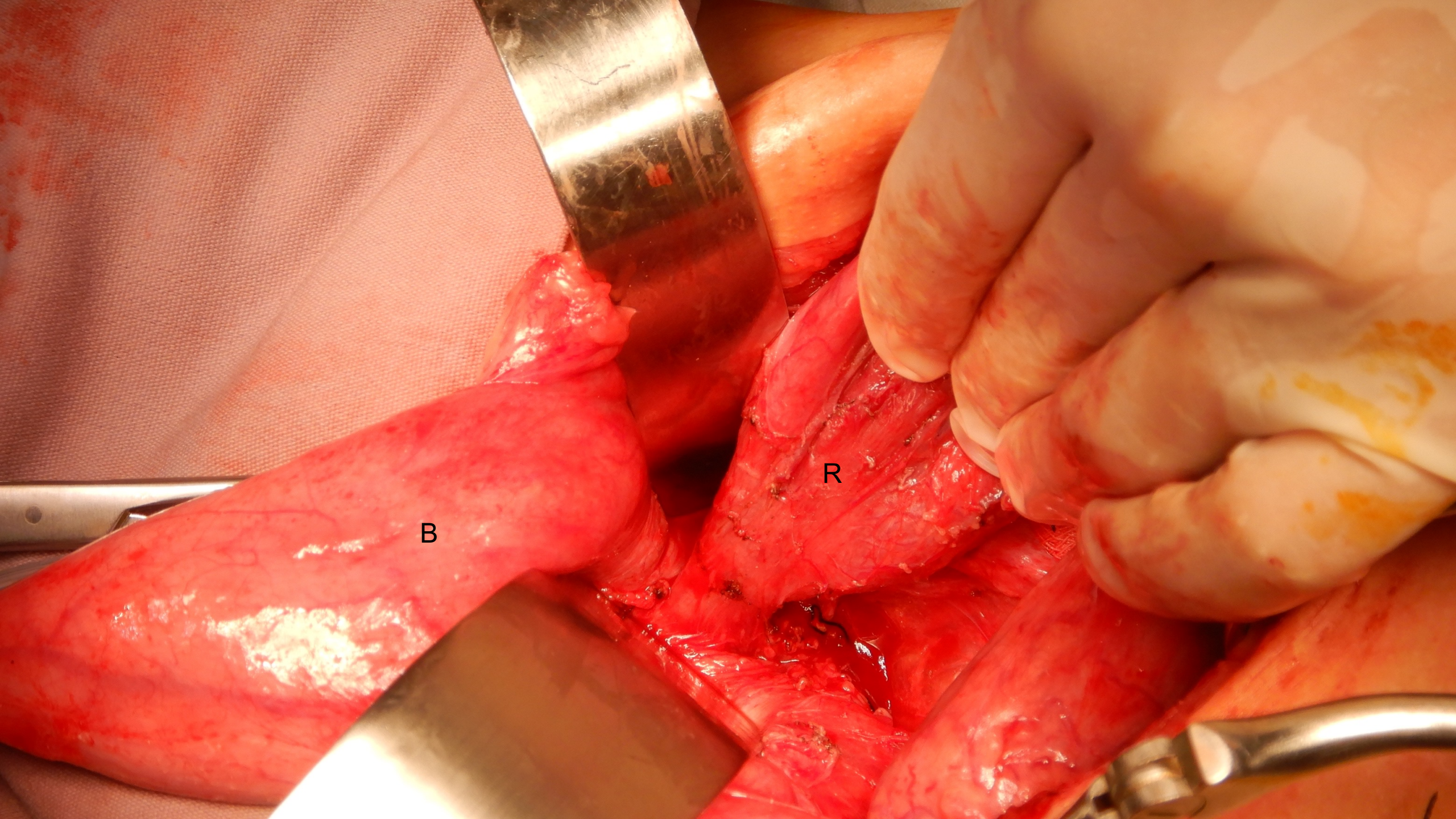






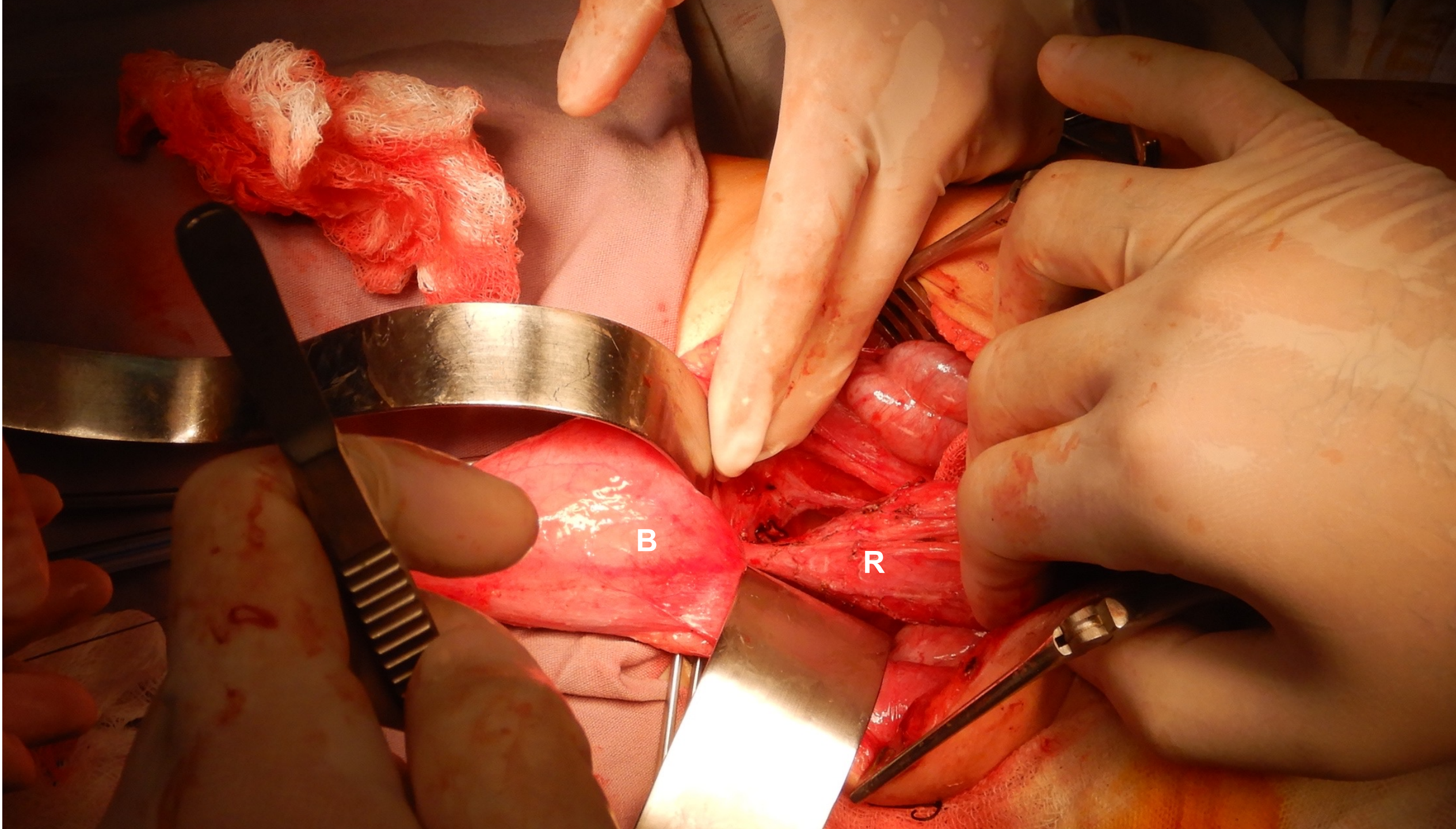
B

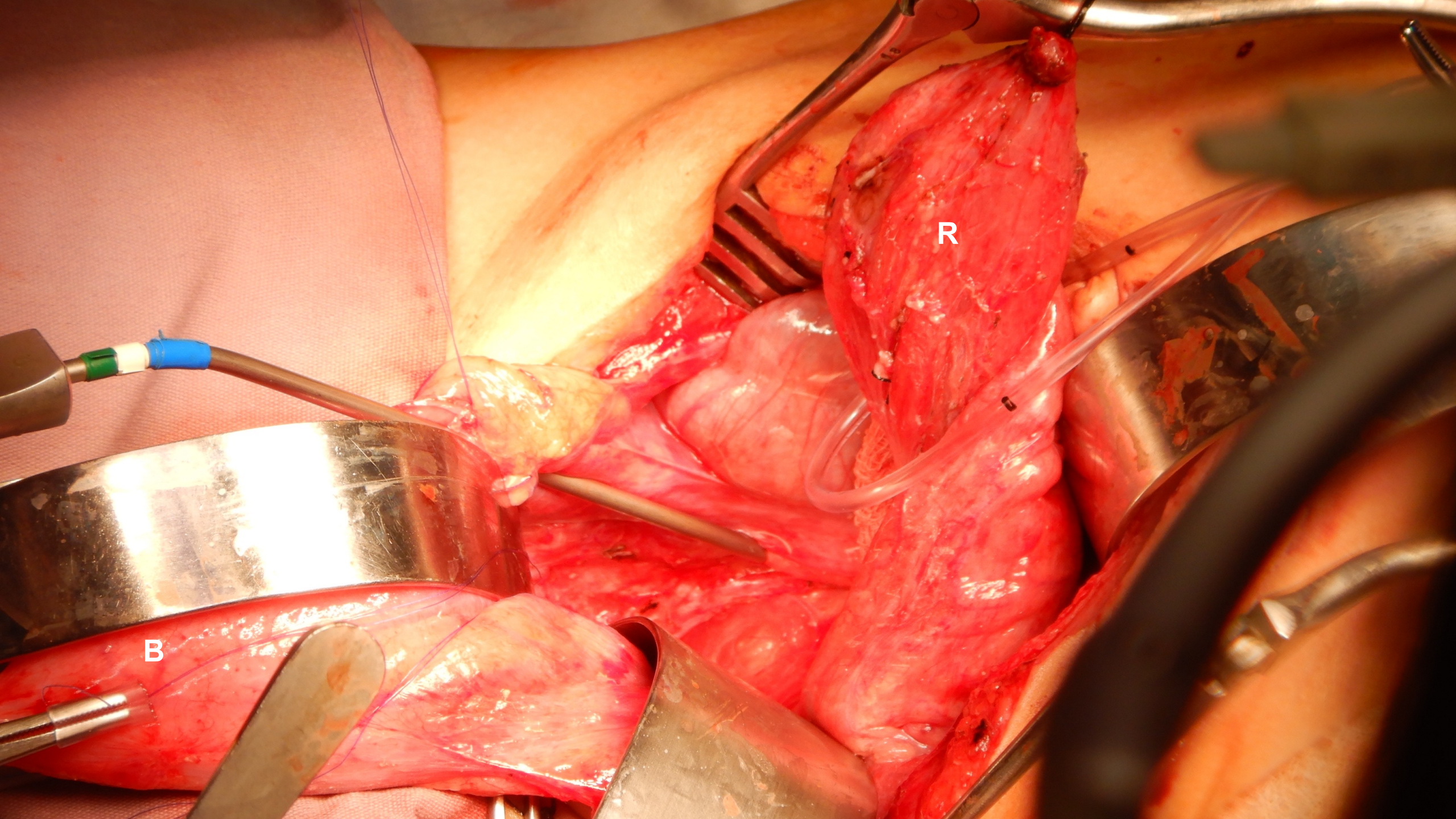
R



B

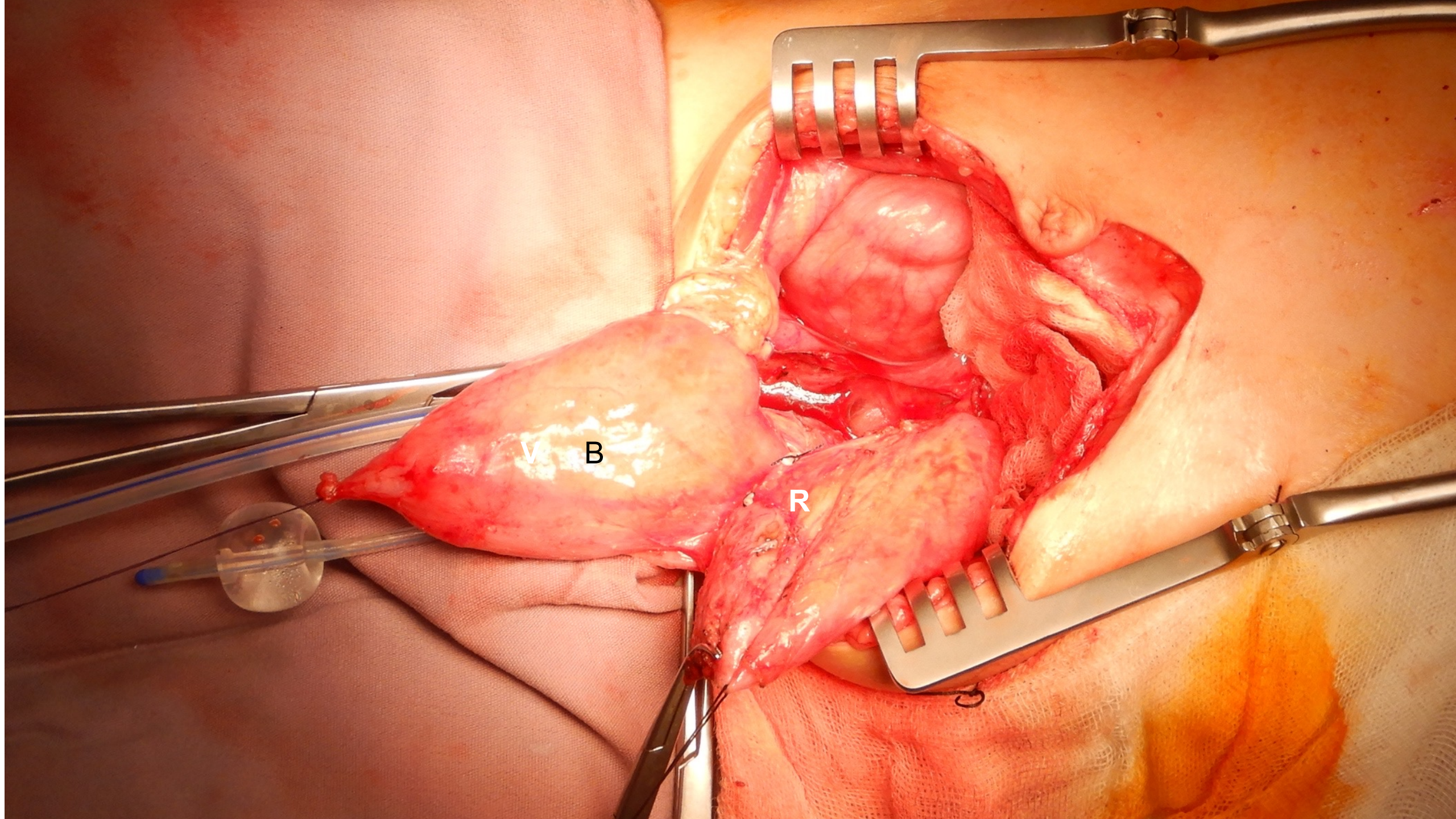
R





R

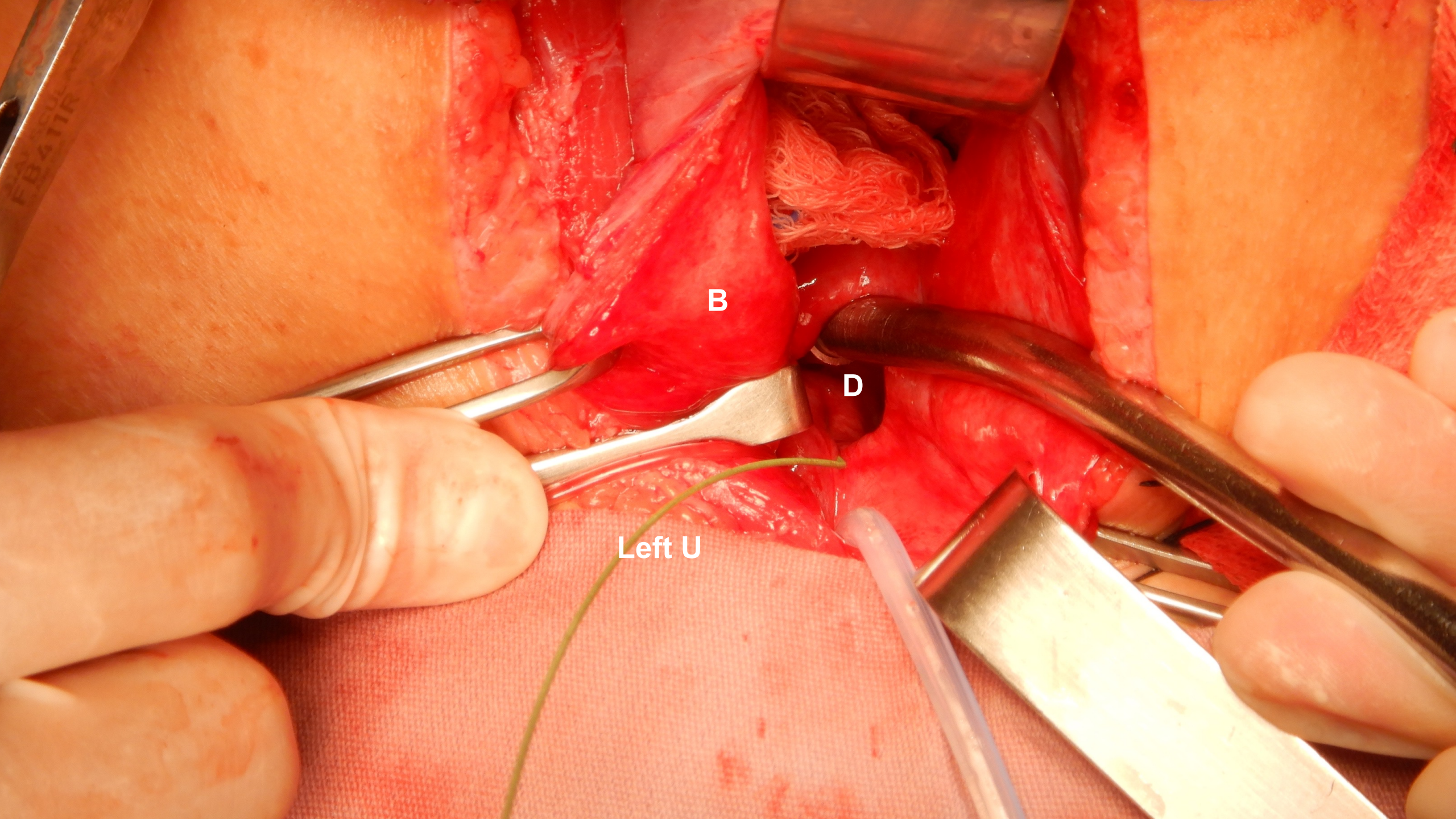
B



V

B

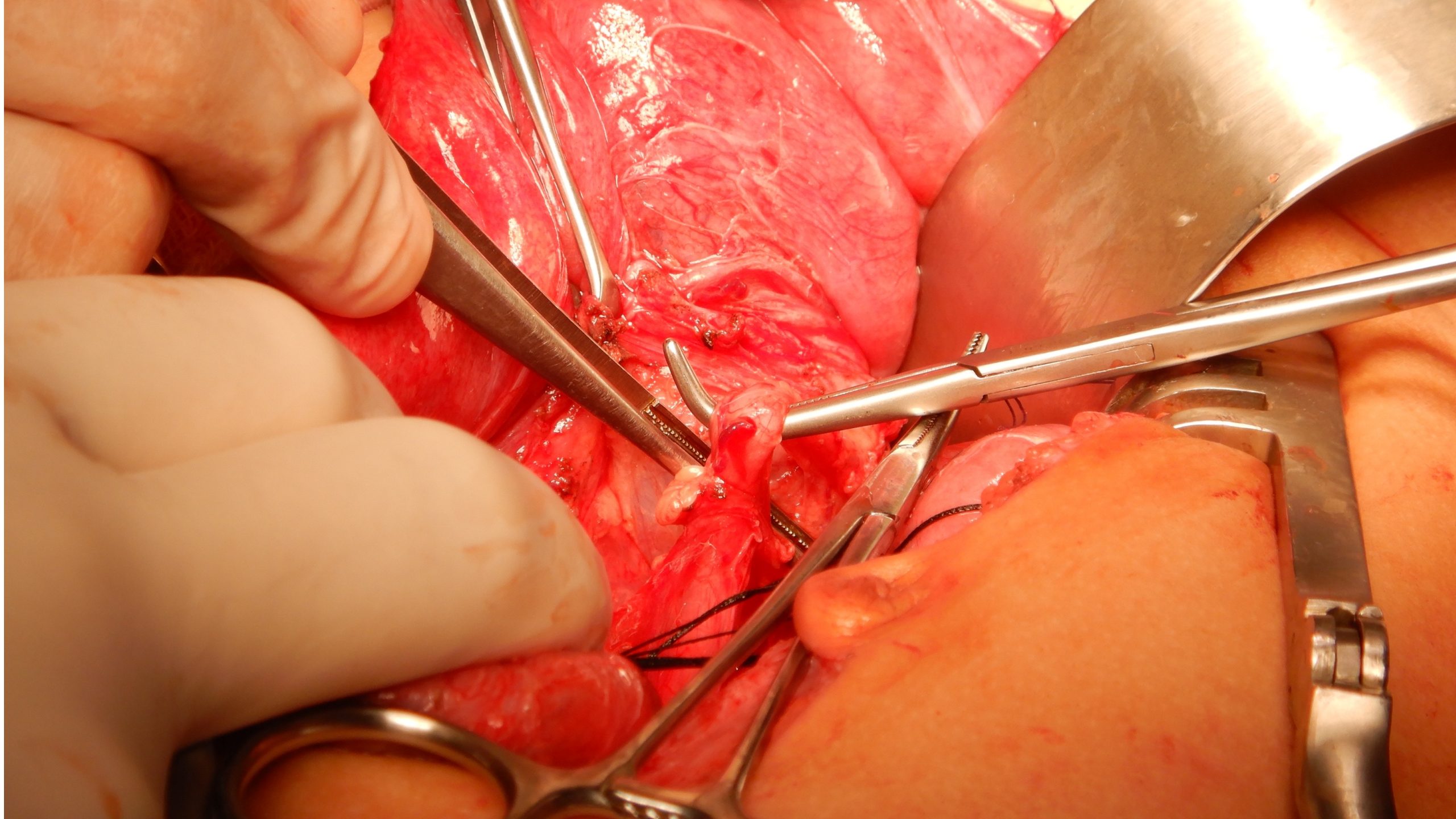
R

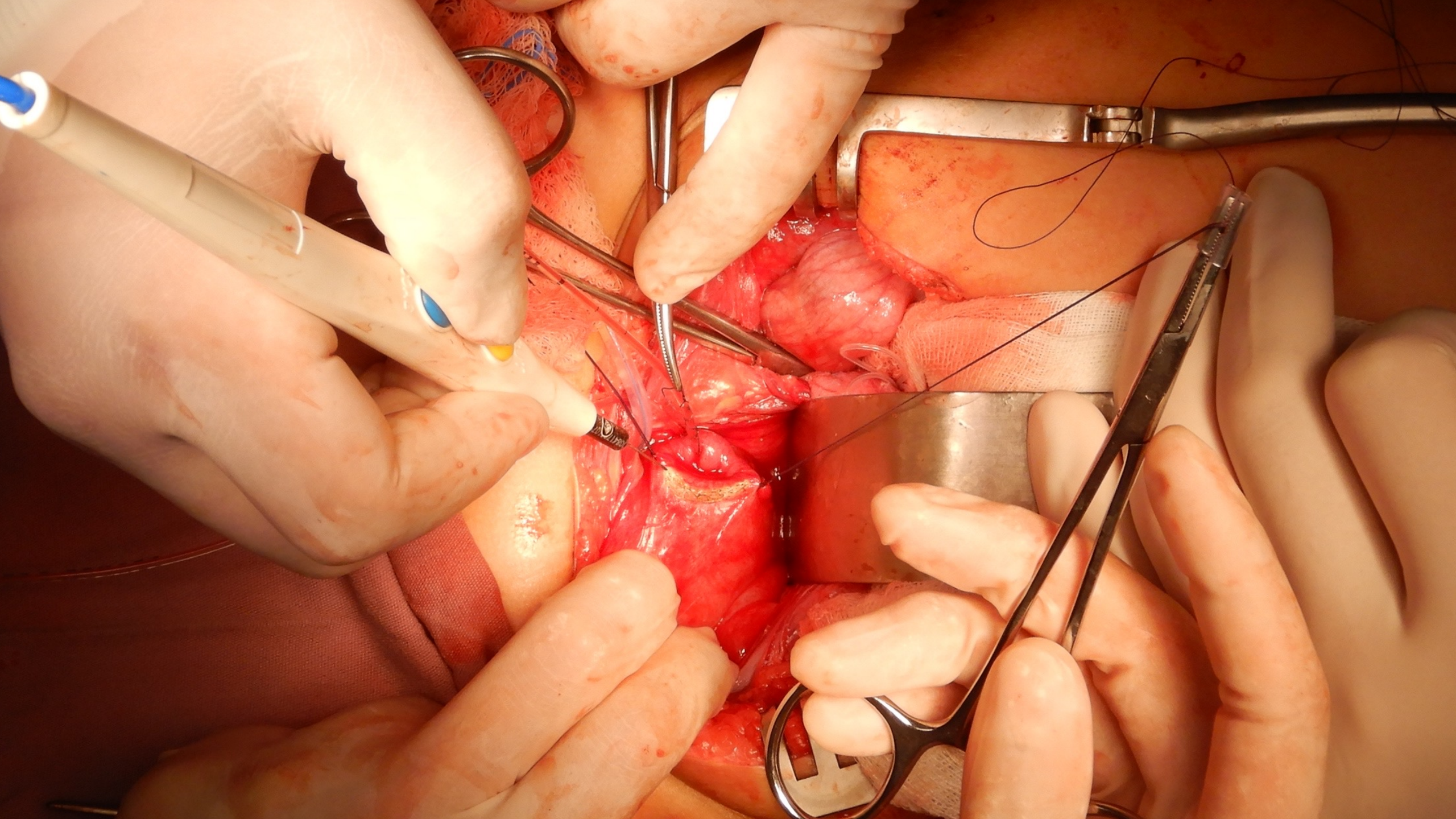


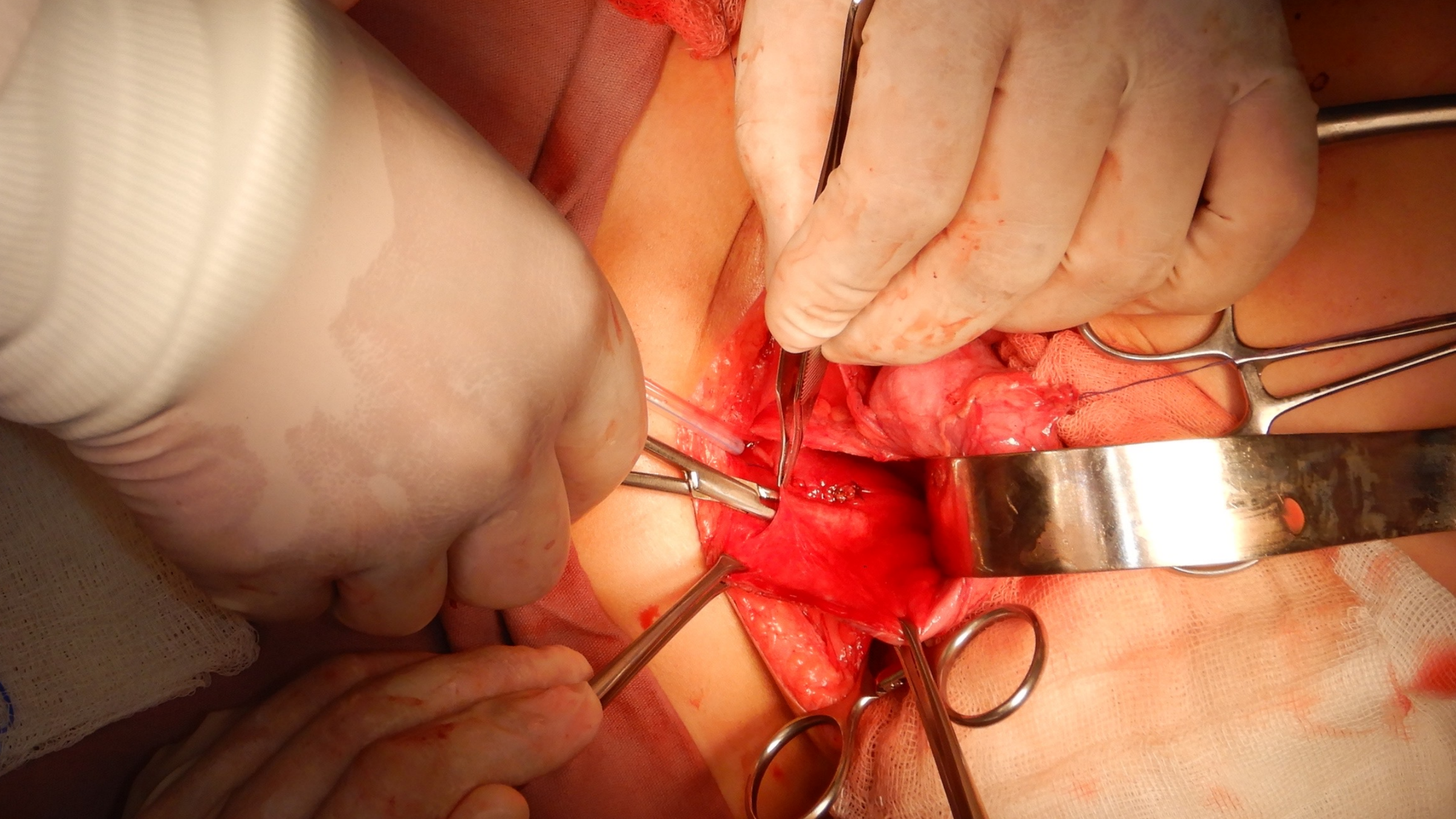
B

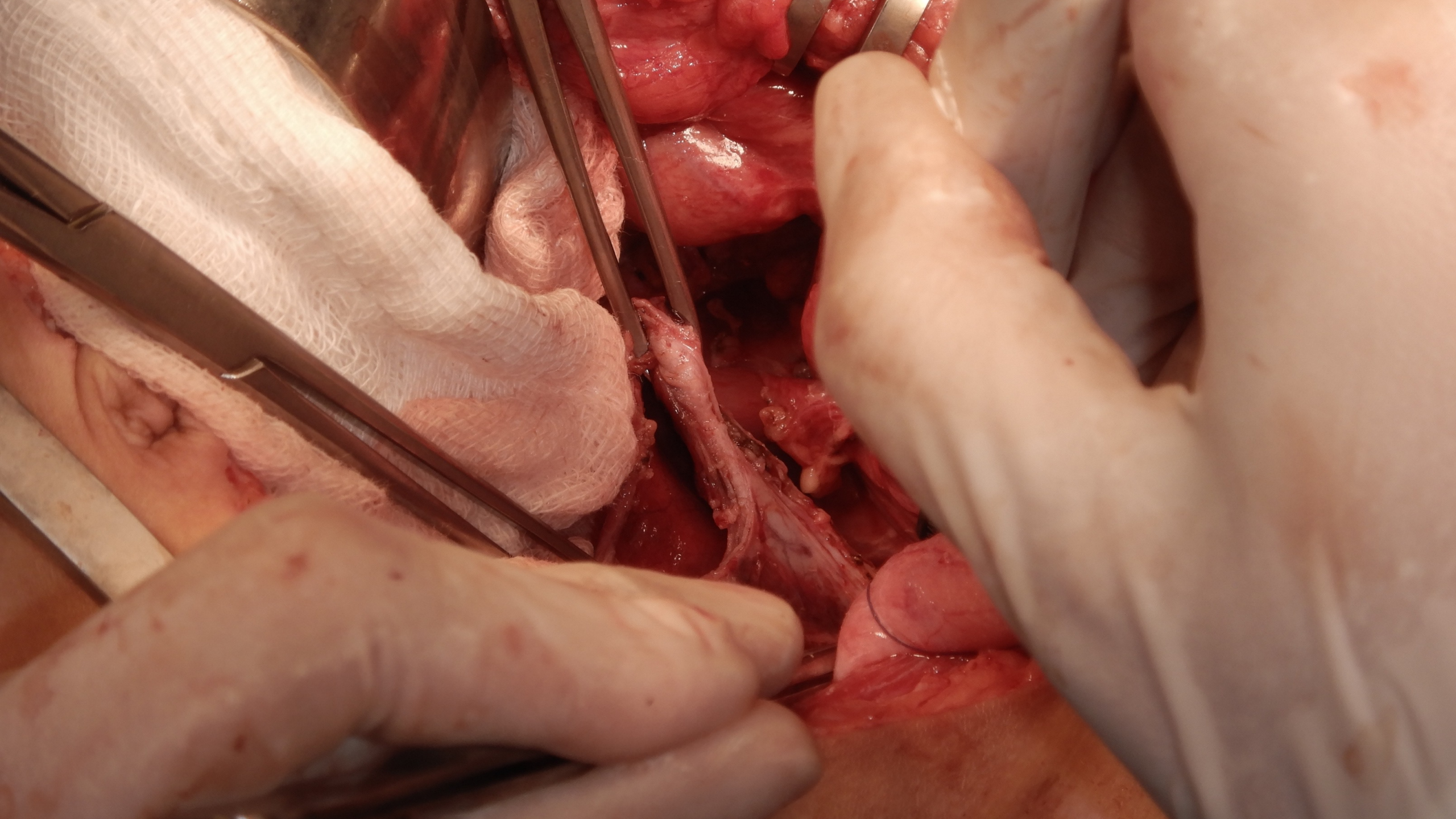D

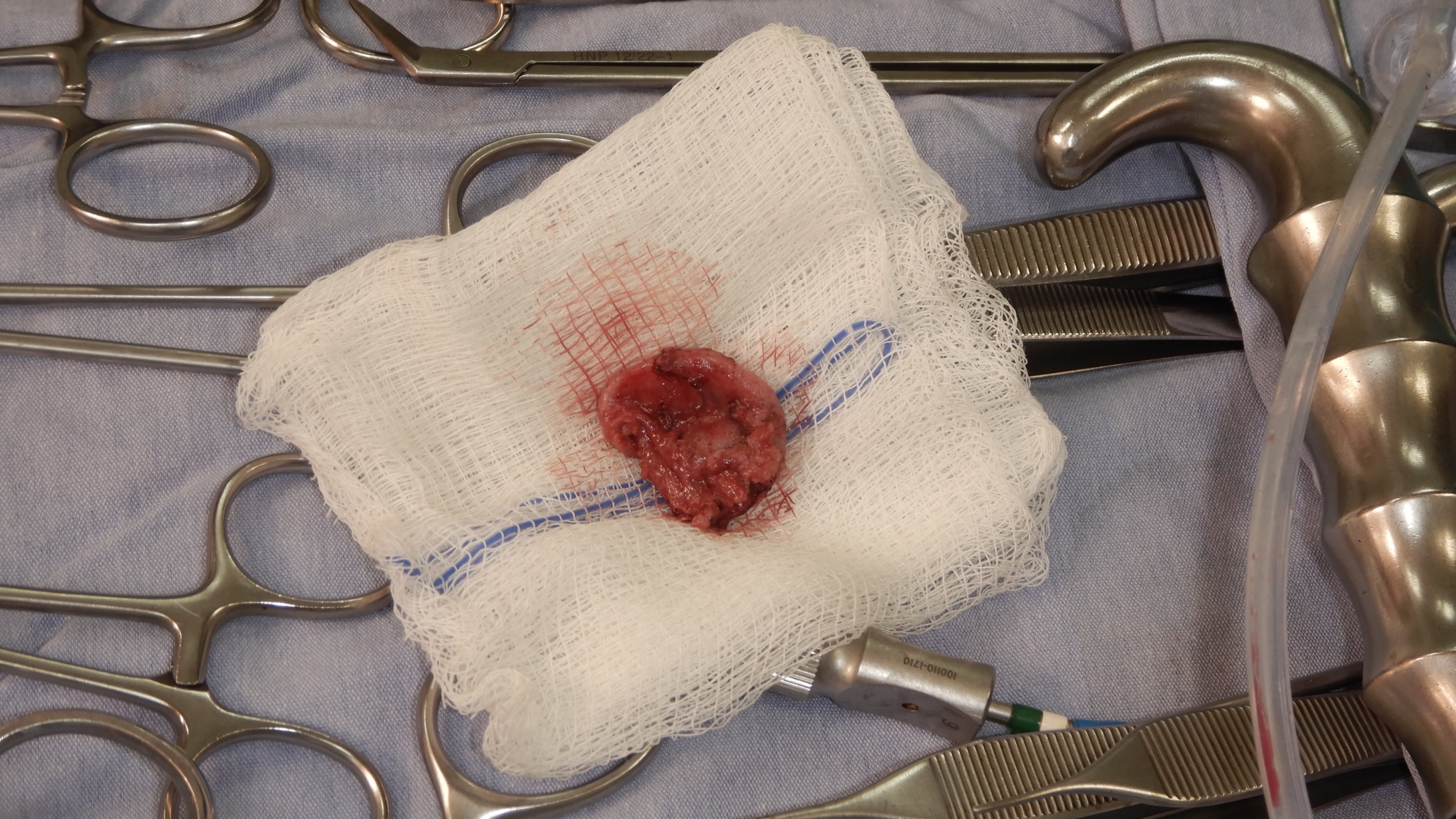
Left U

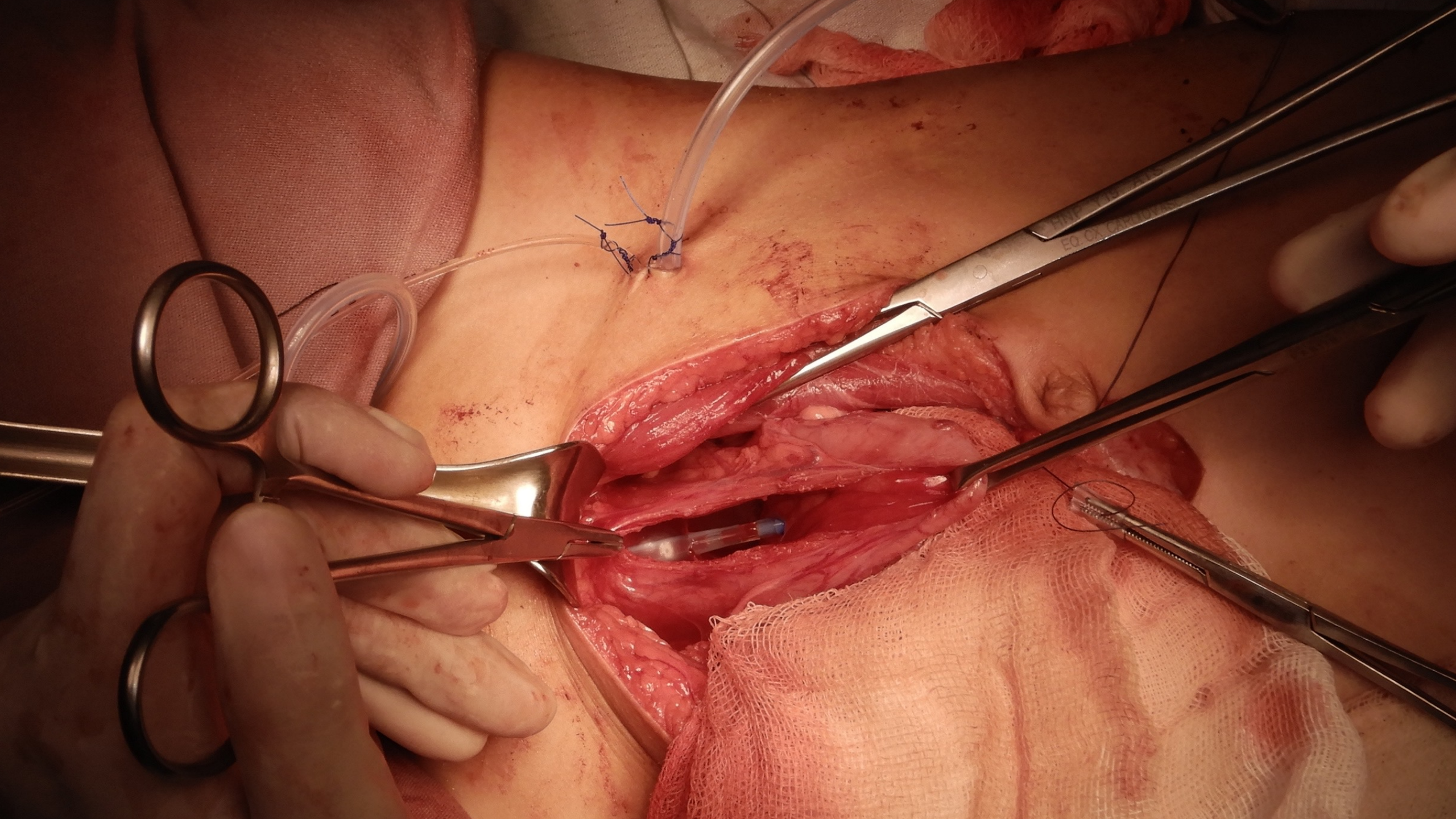


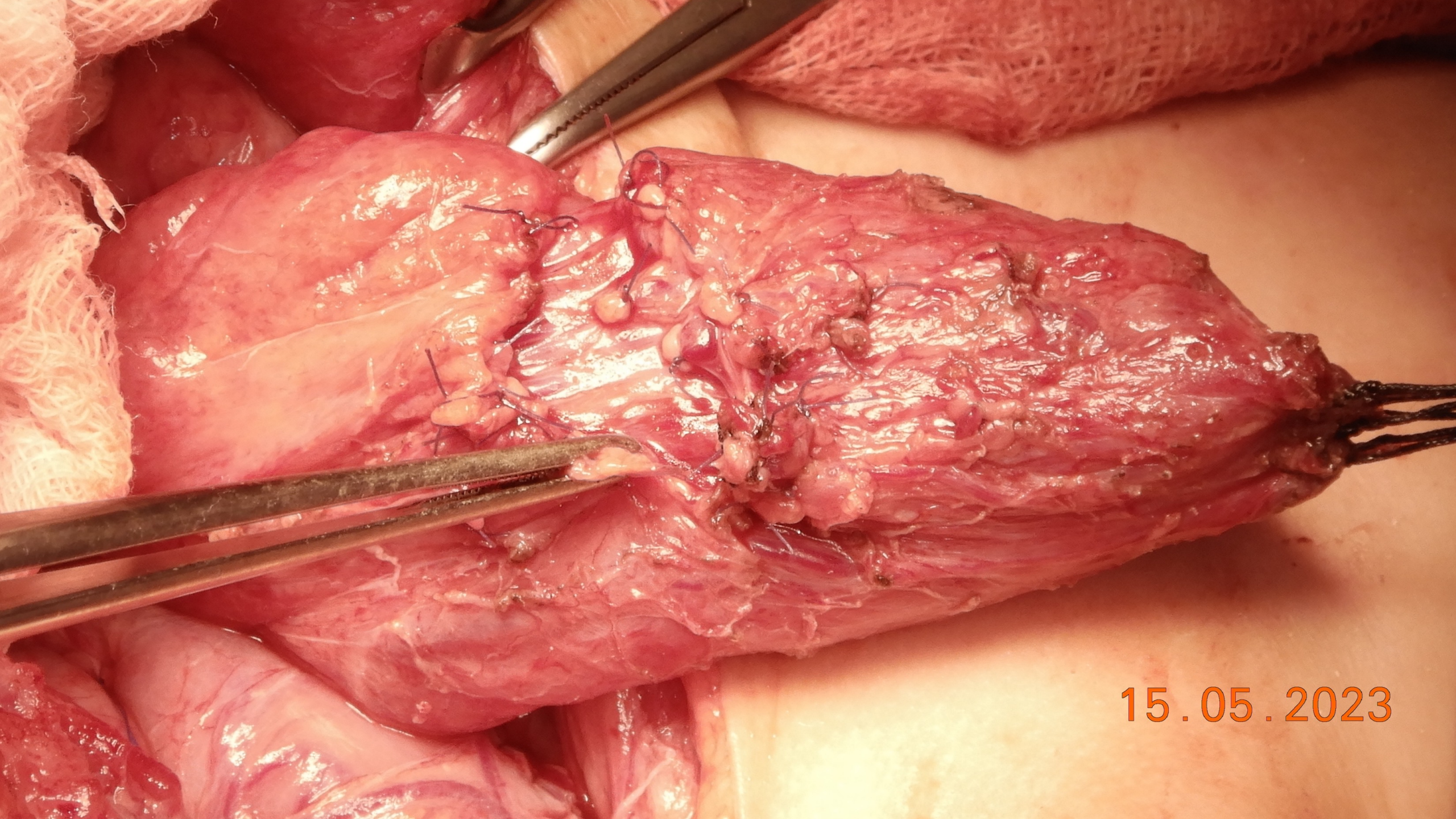




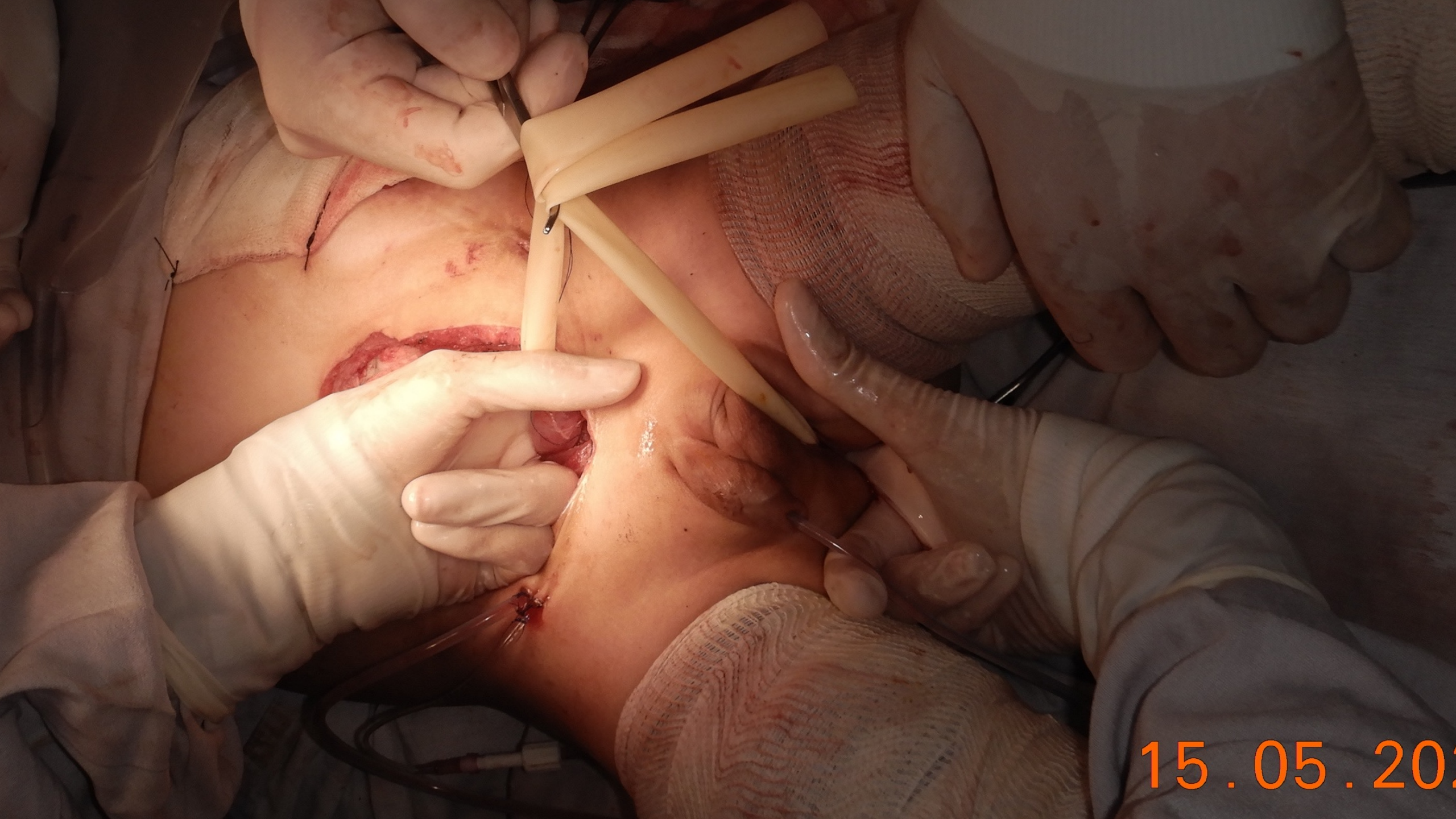




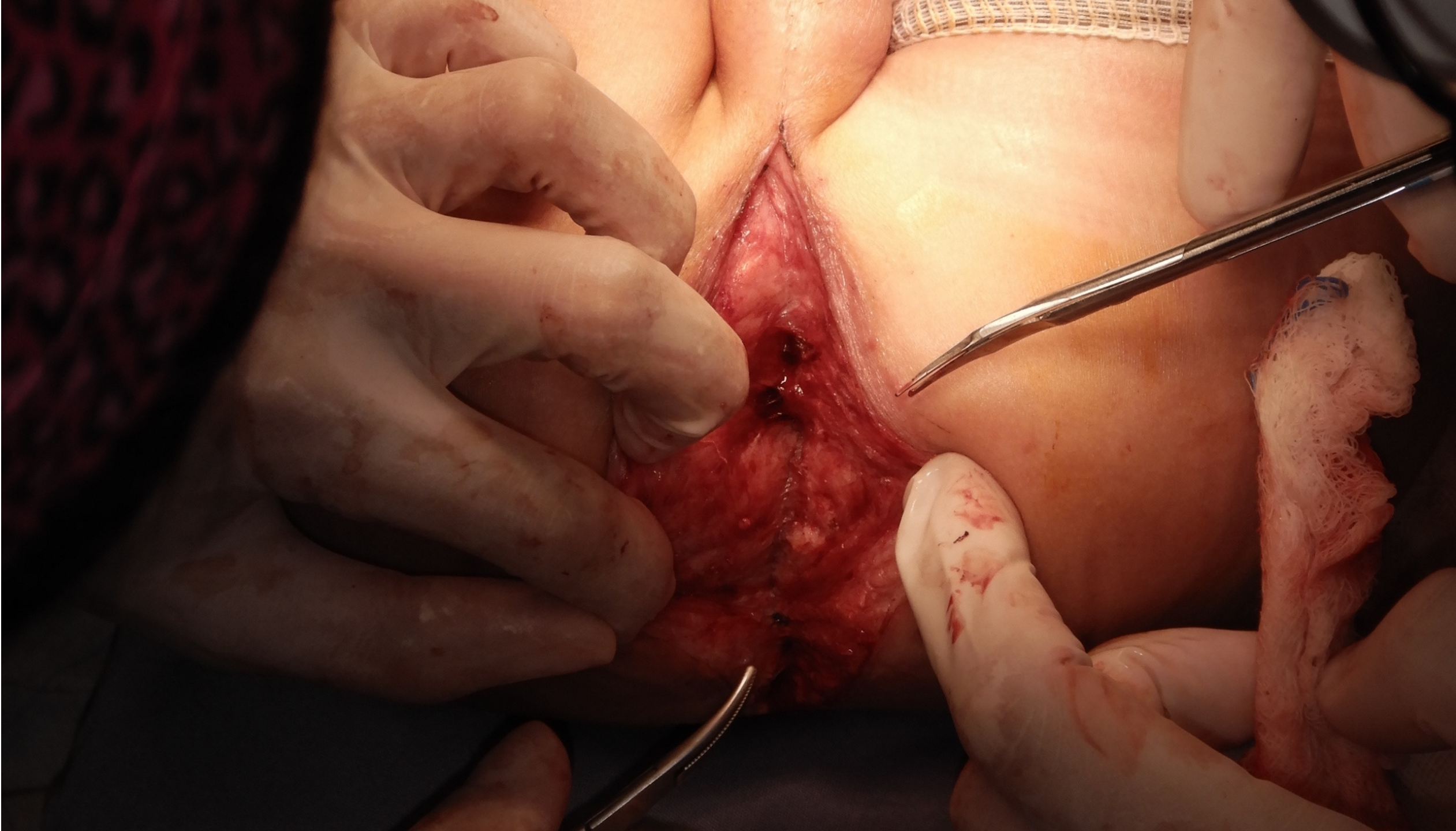


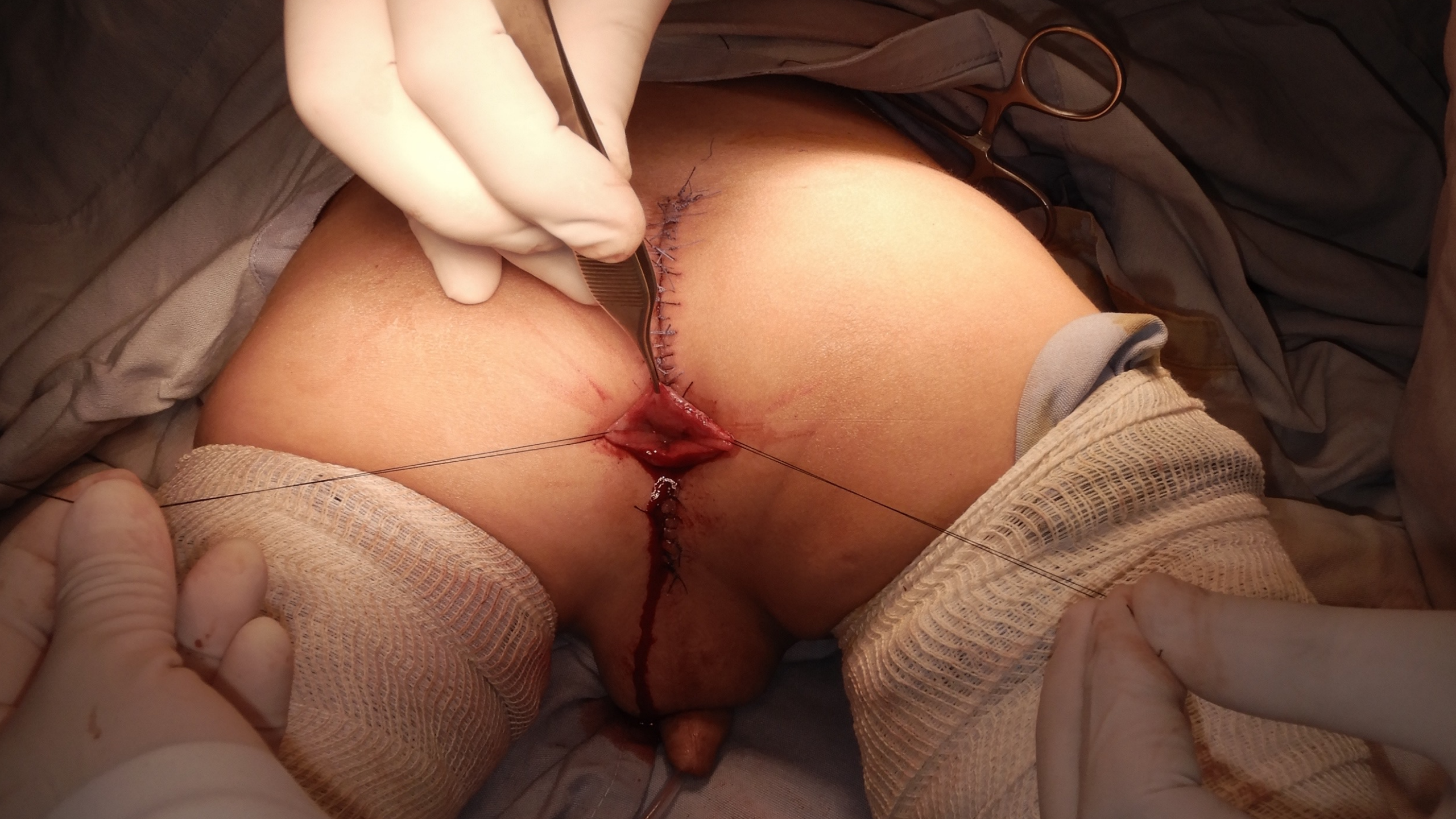15.05.2023



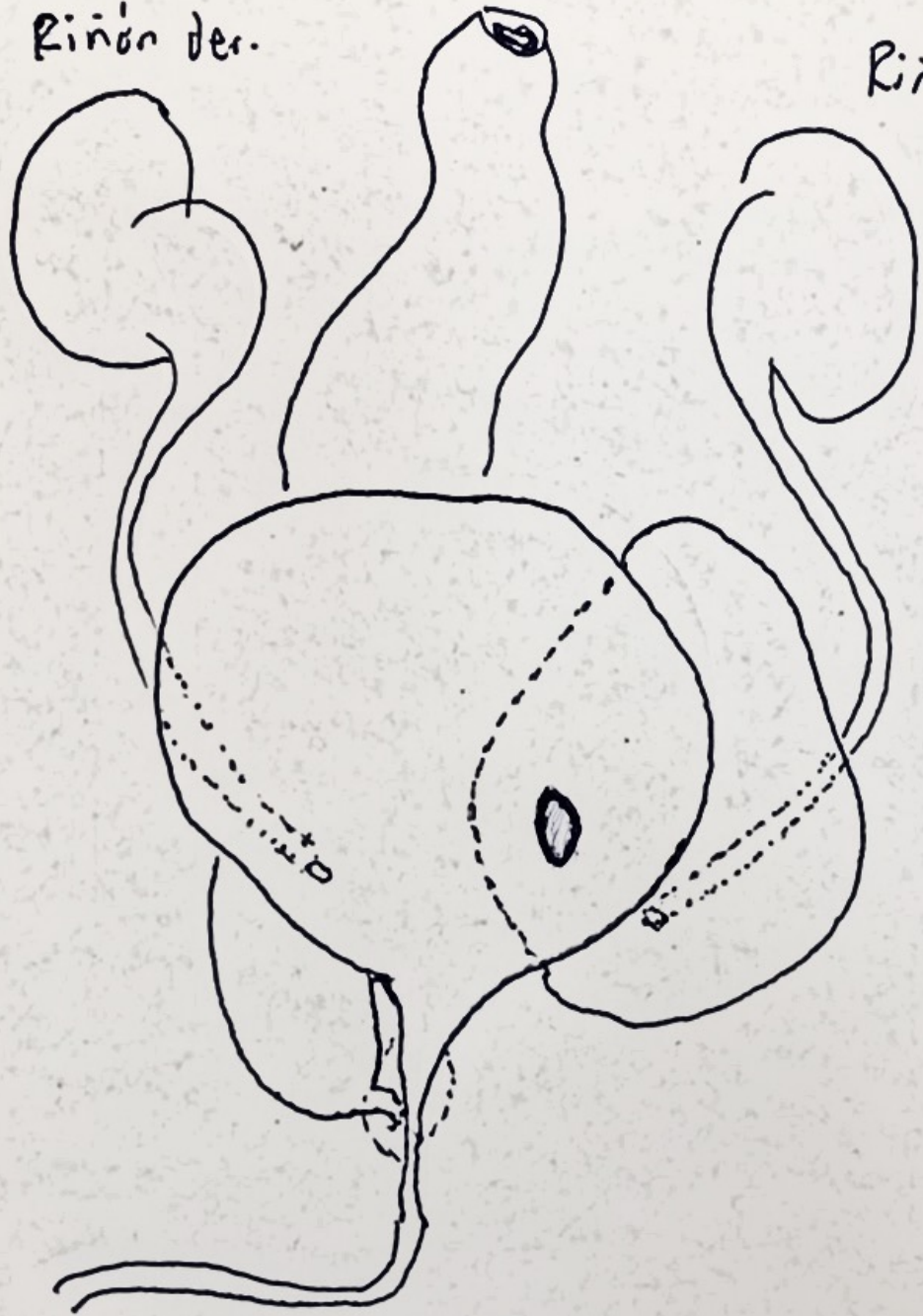
15.05.20





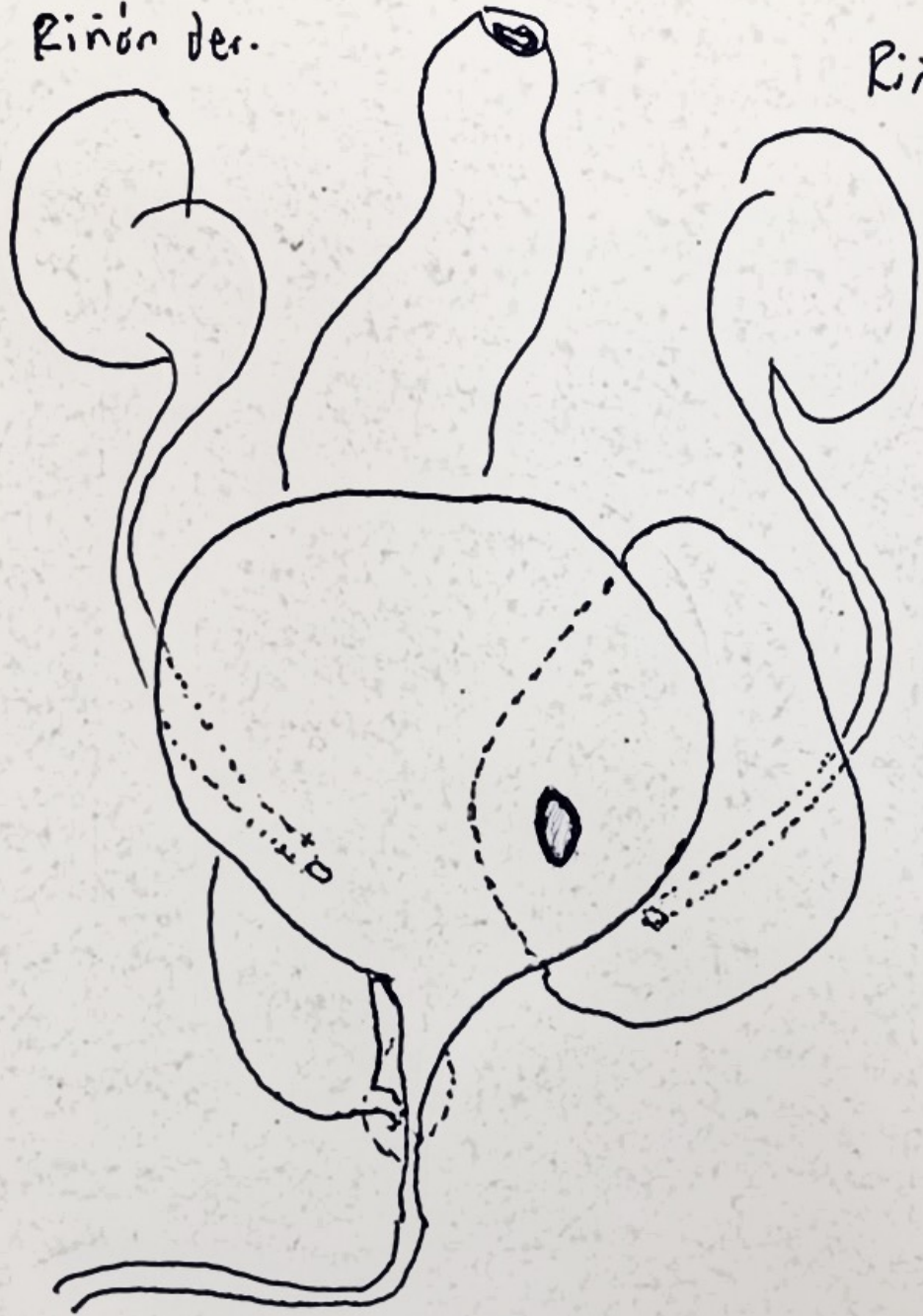
Rind der.

Rind iq.



Riñon der.

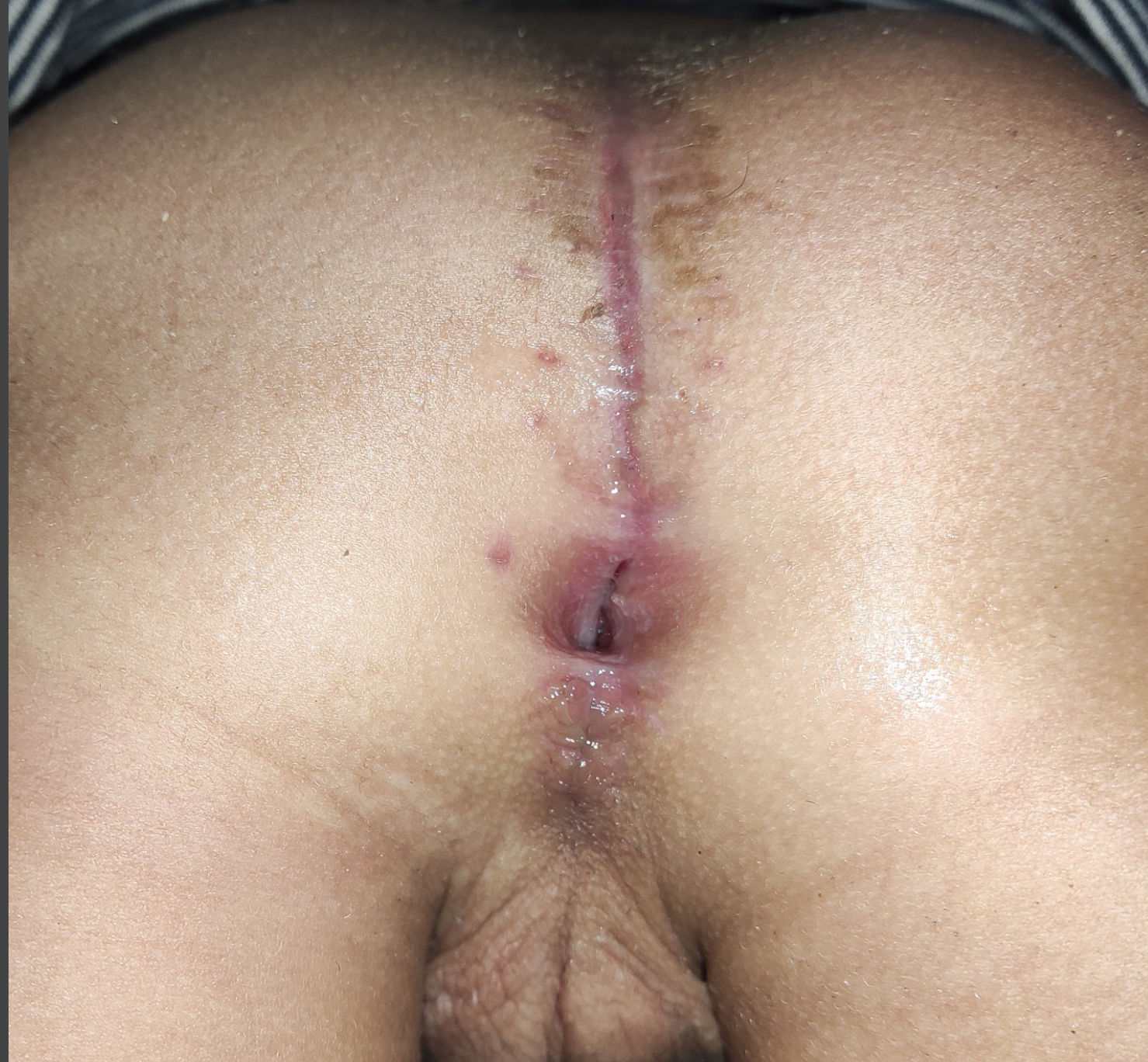Riñon izq.



Riñon der.

Riñon izq.







CENTRO COLORRECTAL PARA NIÑOS MEXICO Y LATINOAMERICA



Thank you