

Case # 4

09/21/2017



Children's Hospital Colorado

INTERNATIONAL CENTER FOR
**COLORECTAL AND
UROGENITAL CARE**

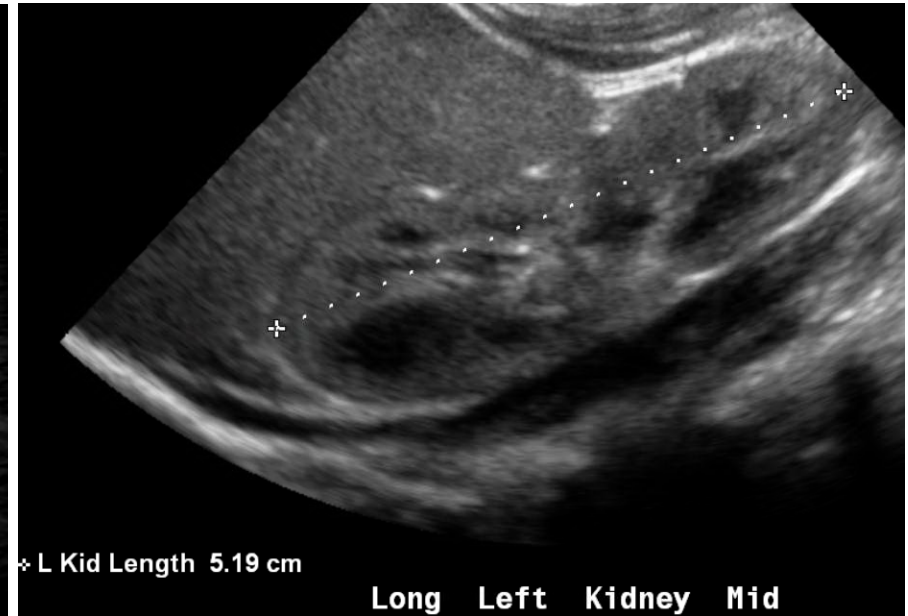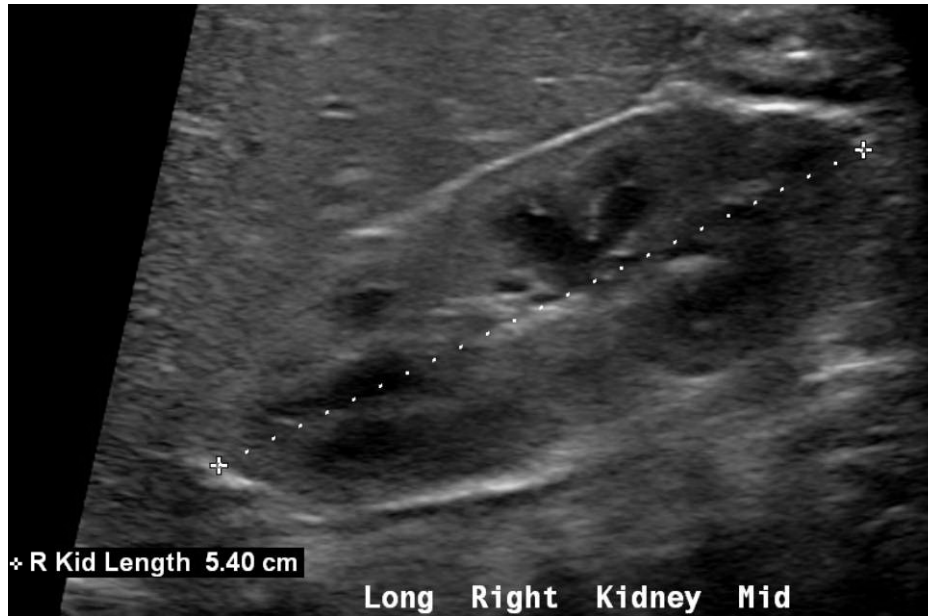


- Newborn male patient discharged from the hospital.
- Upon arrival home, father noticed that the baby had no anus and saw meconium coming at the base of the scrotum

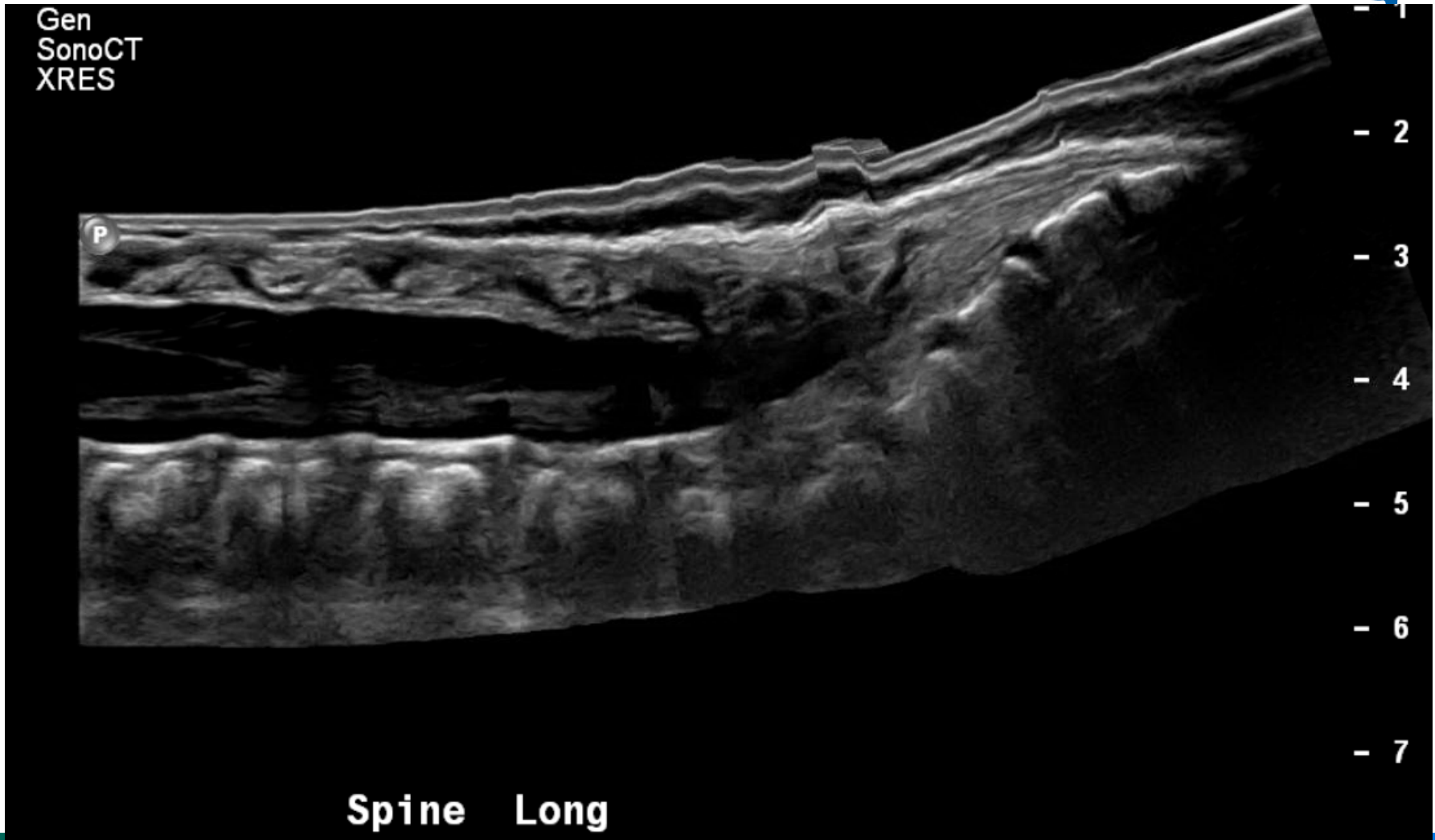

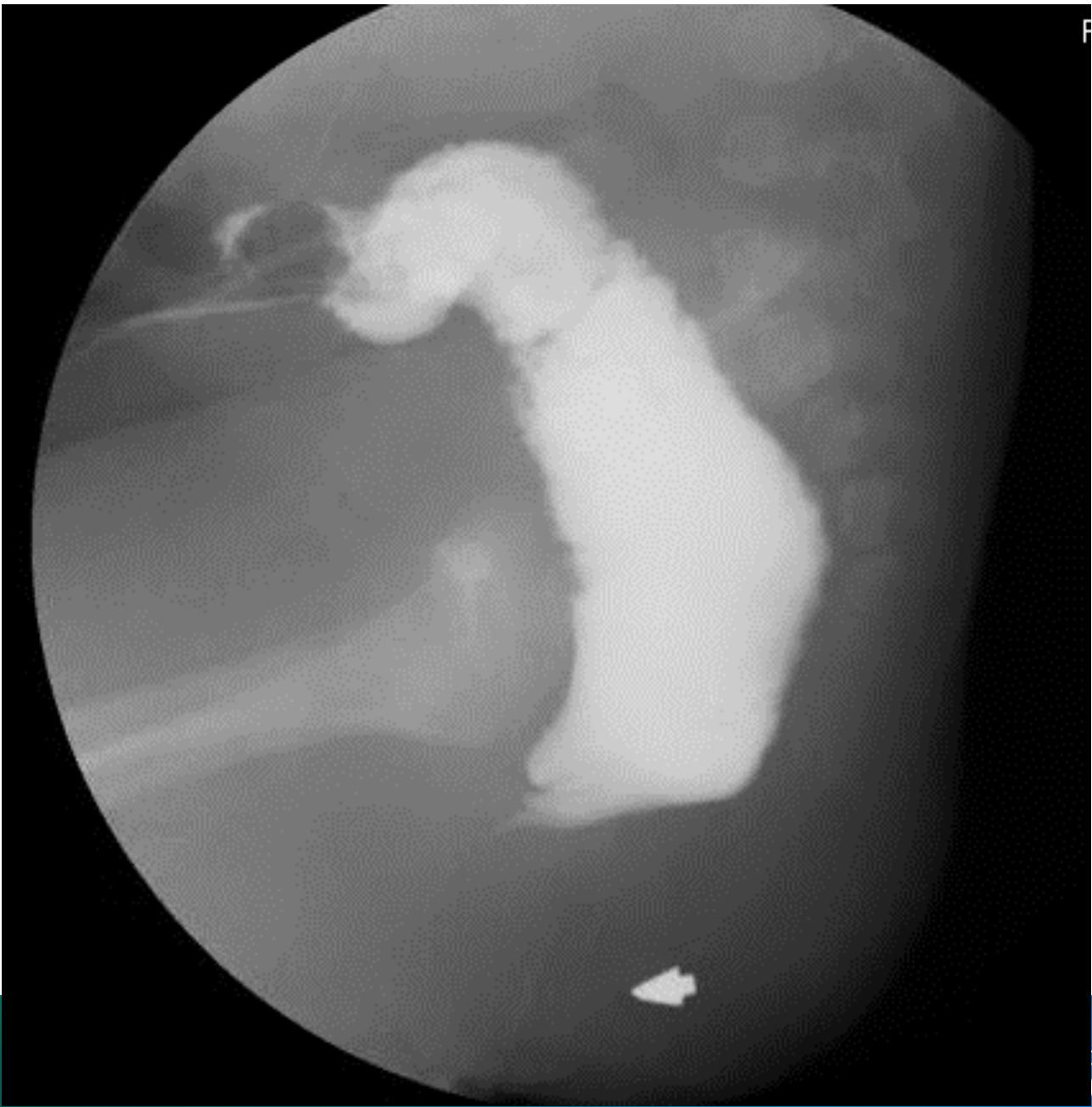- Re-admitted to the hospital.
- Colostomy and mucous fistula were created.
 - Suffered from dehiscence and needed to be re-admitted for wound care.
 - Family decided to come to Colorado for consultation and repair of the malformation.

Kidney Ultrasound



No tethered cord





F



What malformation is this?

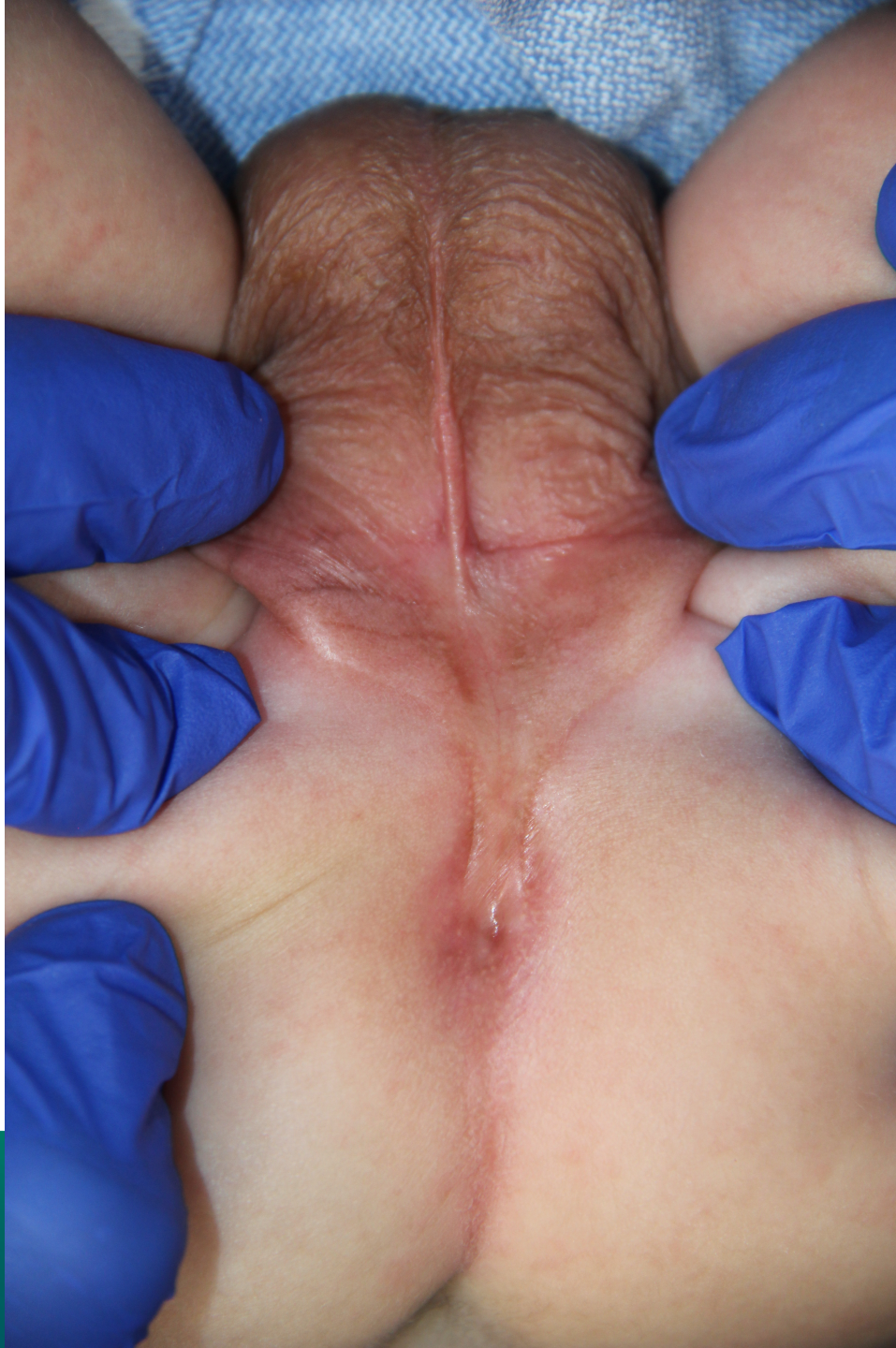1. Imperforate anus without fistula
2. Recto-perineal fistula
3. Recto-urethral bulbar fistula
4. I don't know



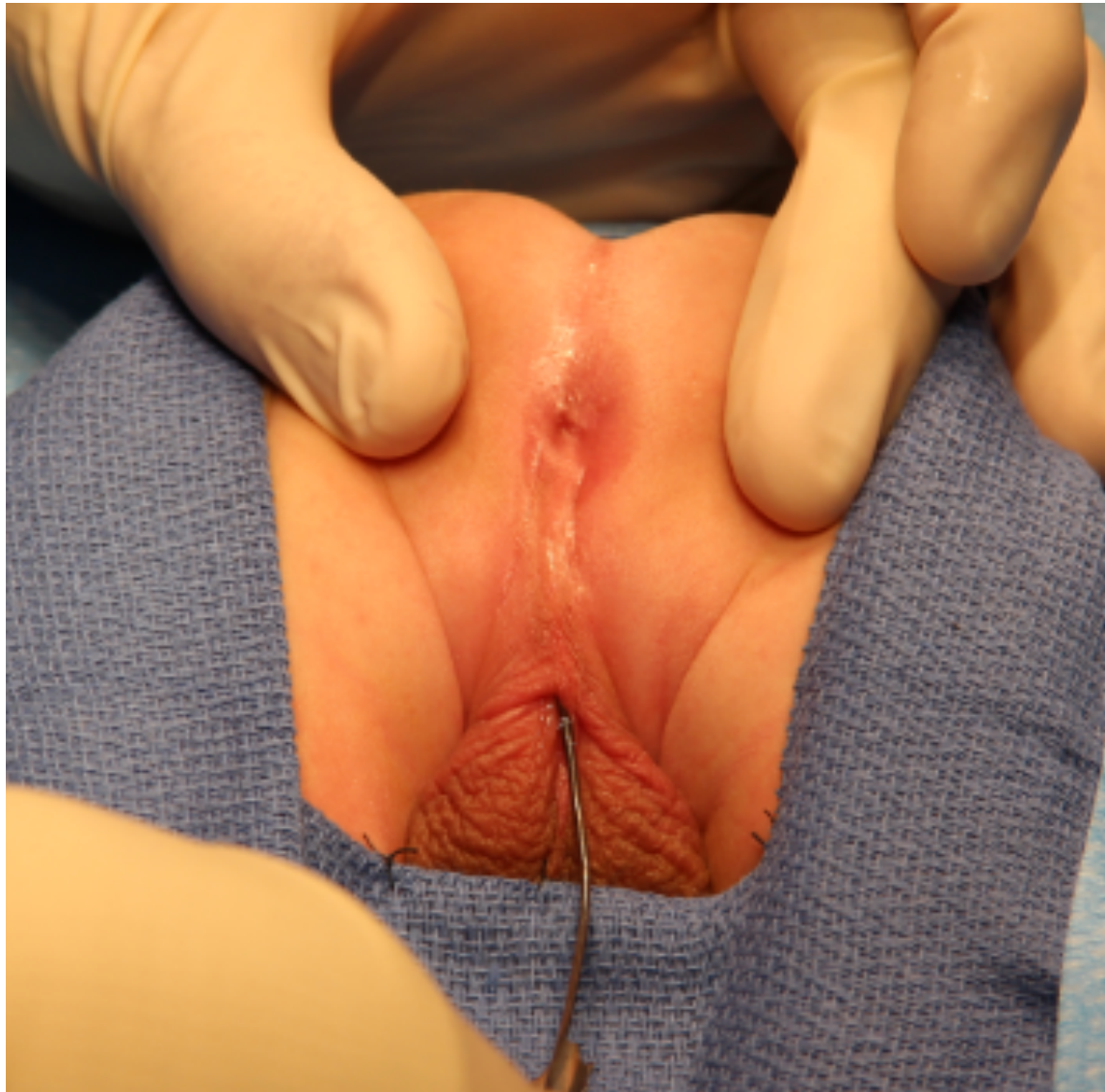F

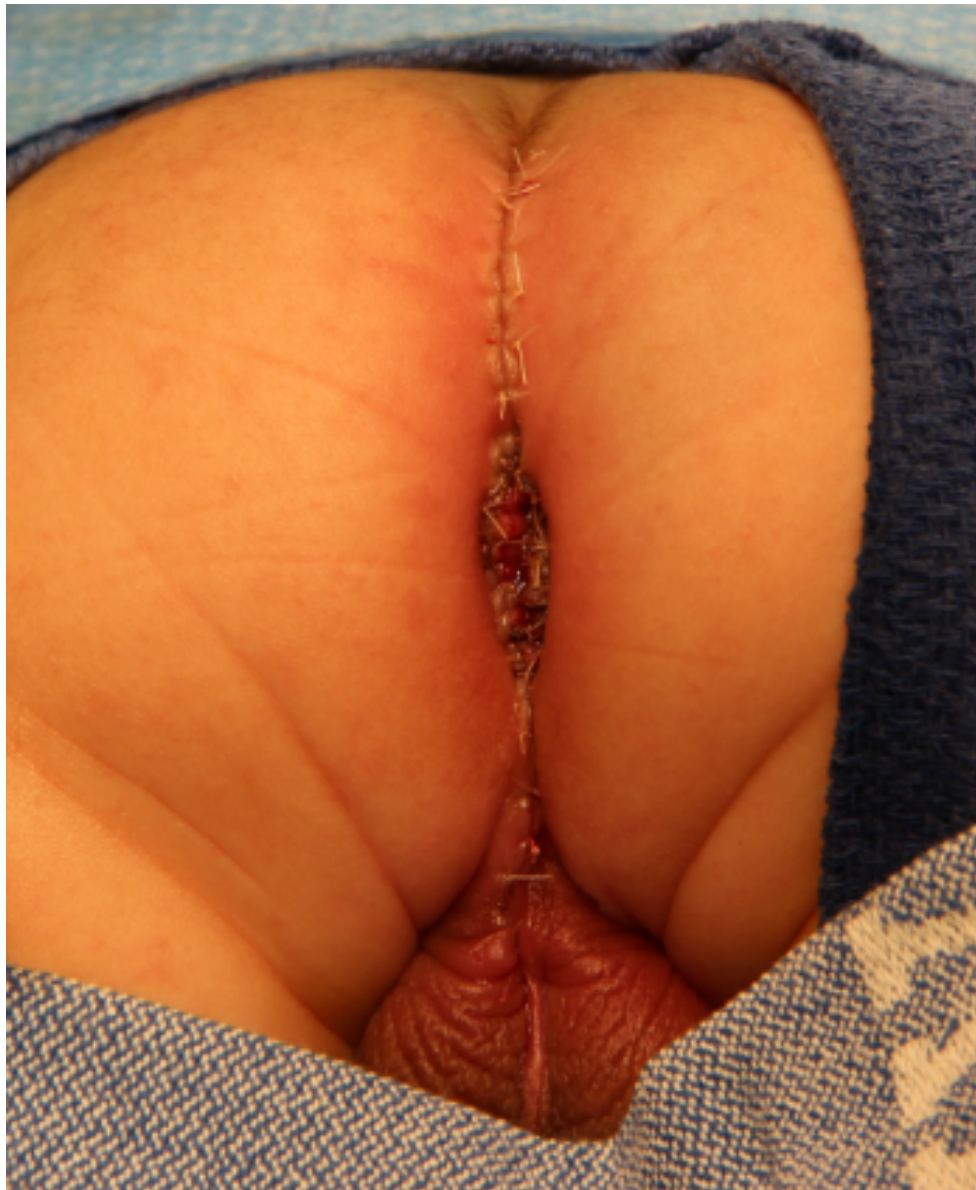

CENTER FOR
AL AND
UROGENITAL CARE



INTERNATIONAL CENTER FOR
**COLORECTAL AND
UROGENITAL CARE**







Our Next International Colorectal Web Meeting will be on October 19th, 2017

